

Urethral-pubic symphysis leak and osteomyelitis following GreenLight™ photoselective photovaporization of the prostate

Michael Kim¹, Aiden Kooyman², Sharon E. Fishberg¹, Jenn A. Locke³, Sarah Neu¹,
Sender Herschorn¹

¹Sunnybrook Health Sciences Centre, University of Toronto, Toronto, ON, Canada; ²University of British Columbia, Vancouver, BC, Canada; ³Kelowna General Hospital, University of British Columbia, Kelowna, BC, Canada

Cite as: Kim M, Kooyman A, Fishberg SE, et al. Urethral-pubic symphysis leak and osteomyelitis following Greenlight™ photoselective photovaporization of the prostate. *Can Urol Assoc J* 2026 March 16; Epub ahead of print. <http://dx.doi.org/10.5489/cuaj.9473>

Published online March 16, 2026

Corresponding author: Dr. Aiden Kooyman, University of British Columbia, Vancouver, BC, Canada; akooym01@student.ubc.ca

ABSTRACT

Introduction: Lower urinary tract symptoms (LUTS) secondary to benign prostatic enlargement are common in the aging male population. In patients where surgical management is warranted, GreenLight photoselective photovaporization (GreenLight-PVP) of the prostate is an option. Prostatic capsule perforation and urethral-pubic symphysis leak is a rare but highly morbid complication of this procedure.

Methods: In this case study compilation, cases of urethral-pubic symphysis leak following Greenlight-PVP were reported on and described. Following this, a literature search across several different platforms was performed.

Results: Four cases of urethral-pubic symphysis leak following GreenLight-PVP are reported on, and an additional seven cases from literature are tabulated.

Conclusions: From these cases, it is seen that patients with this complication often present with difficulty ambulating, urinary retention, pubic symphysis tenderness, and groin pain.

Investigations included urine culture, pubic bone culture, imaging (computed tomography

KEY MESSAGES

- Pubic symphysis leak and osteomyelitis is a rare but morbid complication of GreenLight-PVP.
- Conservative treatment should be attempted with antibiotics and urinary catheter.
- Open surgical management may be necessary and is often successful.
- Early recognition of this complication can lead to improvement to patient quality of life.

cystogram or magnetic resonance imaging of the pelvis), and cystoscopy. Non-surgical management includes urinary diversion and antibiotics and is the first-line treatment. Second-line surgical management includes open prostatectomy, robotic prostatectomy, or sequestration/sequestrectomy of pubic symphysis and repair of the prostate. Additionally, early recognition of this complication can lead to significant improvement in patient quality of life.

INTRODUCTION

Lower urinary tract symptoms (LUTS) due to benign prostatic enlargement (BPE) remains a common condition in the aging male population (1). One possible surgical treatment for BPE is Greenlight-PVP, however complications such as urethral-pubic symphysis leak and osteomyelitis have been reported (2). In this report, we present 4 cases of urethral-pubic symphysis leak and osteomyelitis and review 7 further cases from literature to improve recognition, diagnosis and management of this complication.

METHODS

First, 4 new cases are being presented and reviewed, detailing patient presentation, workup, treatment, and outcome. Following this, a literature search was performed across Medline, EMBAS, and Web of Science to identify reports related to prostatic capsule perforation with osteomyelitis following Greenlight™ PVP. Supplementing the new cases with cases from literature demonstrated the extent of the problem and its analysis in literature while highlighting various treatments and patient outcomes. A search strategy was used with MeSH and free-text keywords (Photoselective vaporization OR PVP OR greenlight TURP AND Osteomyelitis OR prostatosymphyseal fistula OR prostate-symphyseal fistula OR prostatic capsular perforation OR prostate osteitis pubis OR osteitis pubis). After removal of duplicates, 40 articles were screened by title and abstract yielding 8 relevant articles. Full-text review was done by 2 independent reviewers with discrepancies resolved by a third reviewer. The inclusion criteria were defined as any reports of a patient who underwent a Greenlight-PVP and had a prostatic capsular perforation with osteomyelitis. We identified 4 relevant articles linked to 7 instances for a total of 11 cases including the case reviews (Table 1).

RESULTS

Case 1

An 86-year-old male underwent Greenlight-PVP. A catheter was placed but removed one day post-operation. Two weeks postoperatively, he developed urinary incontinence, significant suprapubic pain and difficulty ambulating. Computed tomography (CT) imaging (**Figure 1**) demonstrated pubis symphysis bony irregularity with diastasis concerning for osteomyelitis and

septic arthritis. Urine cultures were positive for ESBL-producing *Escherichia coli* urinary tract infection. Initial treatment with 7 weeks of ertapenem did not resolve ambulatory issues, so he was treated with 3 months of ertapenem. Follow-up cystoscopy demonstrated asymmetric prostatic resection and further imaging and biopsy showed no active infection. He continued to experience urge urinary incontinence, but then died of other causes.

Case 2

A 72-year-old male underwent Greenlight-PVP after bothersome straining and incomplete emptying. Two weeks postoperatively, he developed fever, tachycardia, and suprapubic pain. Blood cultures grew ESBL-producing *E. coli*, and he was put on antibiotics.

Five months later, he presented with hip pain. X-ray revealed symphysis pubis diastases and sacral ala fracture. He was managed for pelvic fracture. On follow-up, he continued to have difficulty ambulating. While MRI (Figure 2) demonstrated pubic symphysis stability, CT-cystogram (Figure 3) demonstrated an anterior prostatic urethral leak.

Cystoscopy demonstrated a defect measuring approximately 1cm distal to the bladder neck. Surgical intervention included sequestrectomy of pubic symphysis, repair of the prostate, with omental flap for coverage. He was placed on 12 weeks of IV Meropenem with 6 weeks of doxycycline to treat *Cutibacterium acnes*. His symptoms resolved, and follow-up retrograde urethrogram and cystoscopy did not demonstrate any contrast extravasation (Figure 4).

Case 3

A 64-year-old male with a history of Grade Group 2 prostate cancer experienced urinary retention post androgen deprivation therapy and radiation therapy. Urodynamics demonstrated that he had detrusor overactivity and outlet obstruction. He underwent Greenlight-PVP. Postoperatively he had pubic pain. An MRI scan demonstrated urine leak between the prostatic urethra and the pubic symphysis. Retrograde urethrogram did not demonstrate any evidence of extravasation after conservative management with Foley catheter and 6 weeks of ampicillin. Symptoms resolved, and a repeat retrograde urethrogram, voiding cystourethrogram and cystoscopy was performed 6 months later confirming resolution of urethral symphysis leak and no further change (Figure 5).

Case 4

A 63-year-old male with a history a previous Greenlight-PVP underwent a repeat Greenlight-PVP for worsening nocturia and poor flow 5 years later. He developed dysuria, urgency, frequency, mild incontinence, abdominal/groin pain, and hematuria immediately after the catheter was removed. Urine cultures showed enterococcus faecalis. Ciprofloxacin followed by cefixime was ineffective after 21-days. CT urogram demonstrated no upper tract abnormalities and a cytology was negative, but cystoscopy demonstrated abnormal tissue at the bladder neck anteriorly 9 months later. Bone scan demonstrated increased bony uptake at the pubic symphysis.

Because of the abnormal tissue at cystoscopy he underwent a TURBT and at the time a hole in the anterior prostate was discovered.

A white blood cell study and a bone marrow scan did not show evidence of osteomyelitis (Figure 6). Based on his symptoms he was treated with IV vancomycin and oral moxifloxacin for 6 weeks. He had continued pain and gross hematuria and follow-up cystoscopy noted this from the bladder neck.

There was no healing of the hole in the prostate. He was started on off-label hyperbaric oxygen and with no resolution of symptoms underwent robotic laparoscopic radical prostatectomy 19 months after the Greenlight photovaporization of the prostate. At the time a fistula hole to the pubic symphysis was noted. He recovered with mild incontinence.

Combined results

In a combined literature review and our cases presented here, a total of 11 patients had a urethral-pubic symphysis leak and osteomyelitis following Greenlight-PVP (**Table 1**). Median age was 70.5 (range 50-86). Median prostate size was 35.5cc (range 16-51). Half were completed with the 120W Greenlight-PVP (3) and the other half with 180W Greenlight-PVP (3) (4 unknown). Median time to presentation post Greenlight-PVP was 12 days (range 7-330). Presenting symptoms included pubic symphysis tenderness, groin pain, difficulty emptying and difficulty ambulating. Signs included fever and tachycardia. Work-up included urine culture, CT-cystogram (5/10), MRI (6/10) and cystoscopy (7/10). CT-cystograms demonstrated a leak between the prostatic capsule and the pubic symphysis. MRIs demonstrated evidence of osteitis pubis. Cystoscopy usually demonstrated defects at the anterior prostate. Patients were initially treated with antimicrobials and urinary drainage (urethral or suprapubic catheter). Five patients had successful open operative management of the leak (including pubic bone sequestrectomy with repair or prostatectomy and placement of omental flap).

DISCUSSION

The use of Greenlight-PVP to treat male BPE is gaining popularity. Because of the high energy associated with the laser in Greenlight-PVP, there is a risk of prostatic capsular perforation lead to urethral to pubic symphysis leak and subsequent osteomyelitis of the pubis symphysis. Symptoms include pubic symphysis tenderness, groin pain, difficulty emptying and difficulty ambulating.

Appropriate work-up includes urine culture, pubic bone culture, imaging (CT-cystogram and/or MRI pelvis) and cystoscopy (8/9/10). Following diagnosis, conservative management with urinary catheter (urethral or suprapubic catheter) and antimicrobial treatment (with cultures) has been shown to have success in some cases (5/11). Conservative management has limitations in resolving symptoms and osteomyelitis (12). Operative intervention with pubic bone resection may be necessary (13).

If symptoms worsen or do not improve with conservative management after 4-6 weeks, open surgical management should be performed often in conjunction with Orthopedic surgery.

There is no consensus on the best operative management (i.e. prostate sparing versus prostatectomy), however, pubic bone sequestrectomy and use of a flap should be considered.

CONCLUSIONS

Pubic symphysis leak and osteomyelitis is a rare but morbid complication of Greenlight-PVP. Symptoms include pubic symphysis tenderness, groin pain, difficulty emptying and difficulty ambulating. Appropriate work-up includes urine culture, pubic bone culture (if possible), imaging (CT-cystogram and/or MRI pelvis) and cystoscopy. Conservative treatment should be attempted with antibiotics and urinary catheter. Second-line open surgical management may be necessary and is often successful. Timely diagnosis of this complication may help reduce morbidity and improve patient quality of life.

DRAFT

REFERENCES

1. Roehrborn CG. Benign prostatic hyperplasia: An overview. *Rev Urol* 2005;7:Suppl 9:S3-14.
2. Nickel JC, Aaron L, Barkin J, et al. Canadian Urological Association guideline on male lower urinary tract symptoms/benign prostatic hyperplasia (MLUTS/BPH): 2018 update. *Can Urol Assoc J* 2018;12:303-12. <https://doi.org/10.5489/cuaj.5616>
3. Matta R, Dvorani E, Wallis C, et al. Complications after surgery for benign prostatic enlargement: A population-based cohort study in Ontario, Canada. *BMJ Open* 2019;9:e032170. <https://doi.org/10.1136/bmjopen-2019-032170>
4. Cornu JN, Ahyai S, Bachmann A, et al. A systematic review and meta-analysis of functional outcomes and complications following transurethral procedures for lower urinary tract symptoms resulting from benign prostatic obstruction: An update. *Eur Urol* 2015;67:1066-96. <https://doi.org/10.1016/j.eururo.2014.06.017>
5. Thomas JA, Tubaro A, Barber N, et al. A multicenter randomized noninferiority trial comparing GreenLight-XPS Laser vaporization of the prostate and transurethral resection of the prostate for the treatment of benign prostatic obstruction: Two-yr outcomes of the GOLIATH study. *Eur Urol* 2016;69:94-102. <https://doi.org/10.1016/j.eururo.2015.07.054>
6. Calves J, Thoulouzan M, Perrouin-Verbe MA, et al. Long-term patient-reported clinical outcomes and reoperation rate after photovaporization with the XPS-180W GreenLight Laser. *Eur Urol Focus* 2019;5:676-80. <https://doi.org/10.1016/j.euf.2017.10.006>
7. Ajib K, Mansour M, Zanaty M, et al. Photoselective vaporization of the prostate with the 180-W XPS-Greenlight laser: Five-year experience of safety, efficiency, and functional outcomes. *Can Urol Assoc J* 2018;12:E318-24. <https://doi.org/10.5489/cuaj.4895>
8. Kahokehr AA, Boysen WR, Schild MH, et al. Urinary pubic symphysis fistula leads to histopathologic osteomyelitis in prostate cancer survivors. *Urology* 2020. <https://doi.org/10.1016/j.urology.2020.07.038>
9. Wignall TA, Carrington BM, Logue JP. Post-radiotherapy osteomyelitis of the symphysis pubis: computed tomographic features. *Clin Radiol* 1998;53:126-30. [https://doi.org/10.1016/S0009-9260\(98\)80059-7](https://doi.org/10.1016/S0009-9260(98)80059-7)
10. Sexton SJ, Lavien G, Said N, et al. Magnetic resonance imaging features of pubic symphysis urinary fistula with pubic bone osteomyelitis in the treated prostate cancer patient. *Abdom Radiol (NY)* 2019;44:1453-60. <https://doi.org/10.1007/s00261-018-1827-2>
11. Nosé BD, Boysen WR, Kahokehr AA, et al. Extirpative cultures reveal infectious pubic bone osteomyelitis in prostate cancer survivors with urinary-pubic symphysis fistulae (UPF). *Urology* 2020;142:221-5. <https://doi.org/10.1016/j.urology.2020.04.095>
12. Lavien G, Chery G, Zaid UB, et al. Pubic bone resection provides objective pain control in the prostate cancer survivor with pubic bone osteomyelitis with an associated urinary tract to pubic symphysis fistula. *Urology* 2017;100:234-9. <https://doi.org/10.1016/j.urology.2016.08.035>
13. Gupta S, Zura RD, Hendershot EF, et al. Pubic symphysis osteomyelitis in the prostate cancer survivor: Clinical presentation, evaluation, and management. *Urology* 2015;85:684-90. <https://doi.org/10.1016/j.urology.2014.11.020>

FIGURES AND TABLES

Figure 1. Periosteal reaction and asymmetry of the pubic rami concerning for osteomyelitis.

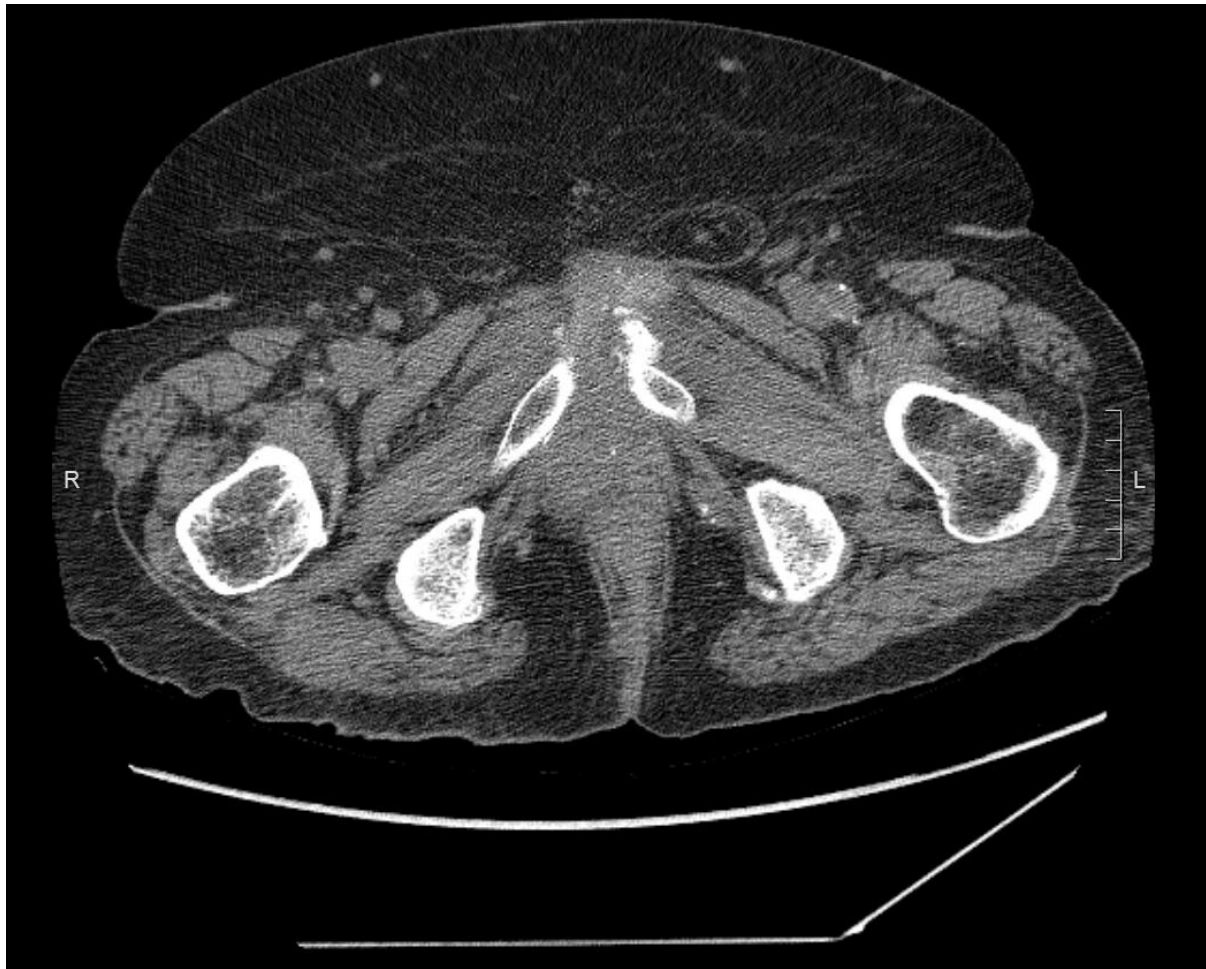

Figure 2. T2-weighted magnetic resonance imaging demonstrating the widened pubic symphysis as well as contrast extravasation from the anterior margin of urethra suggestive of leak.

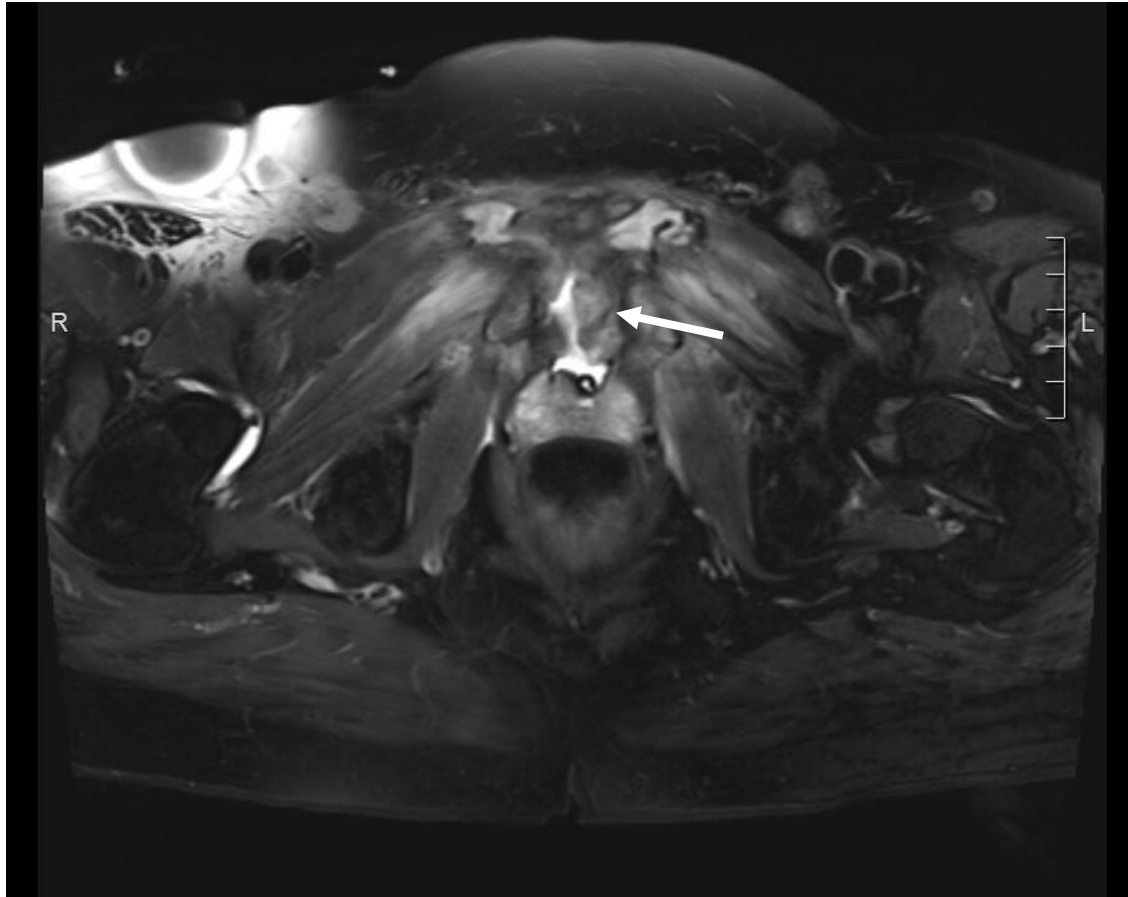
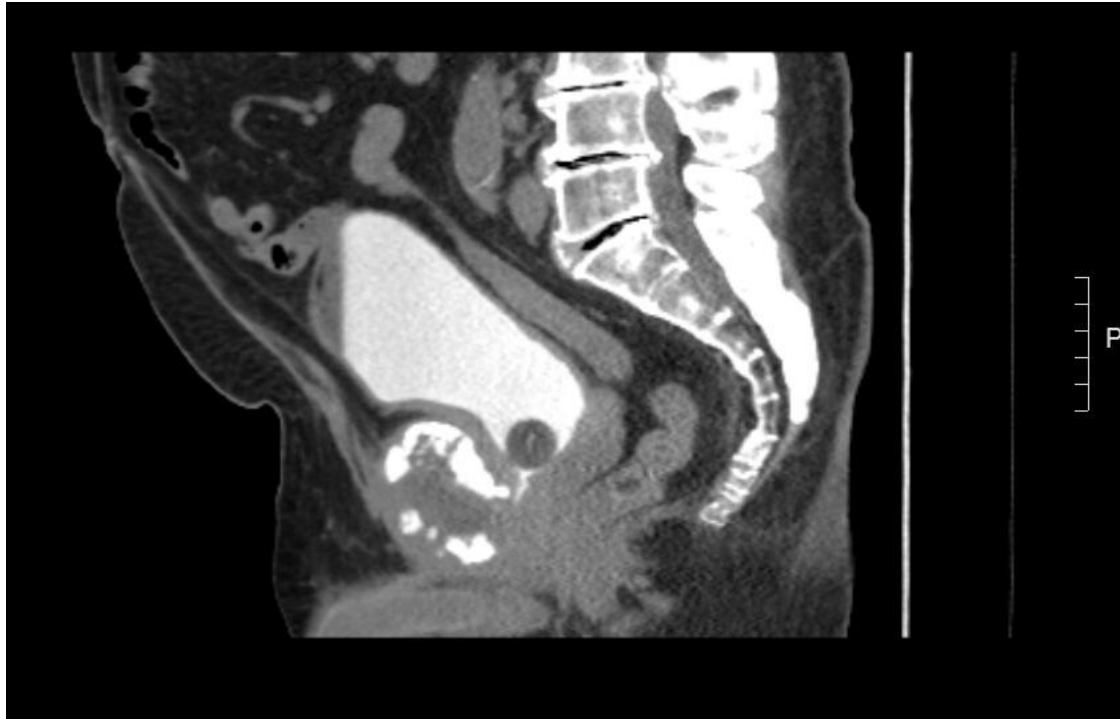


Figure 3. Computed tomography cystogram sagittal view with Foley catheter in situ. A small contrast leak is demonstrated from the prostatic urethra near the bladder neck to the bony fragments of the pubic symphysis.



DRAFT

Figure 4A and 4B. Voiding cystourethrogram performed 2 months post leak repair. There is no contrast extravasation visualized after (A) the bladder is filled with contrast; and (B) after bladder emptying.

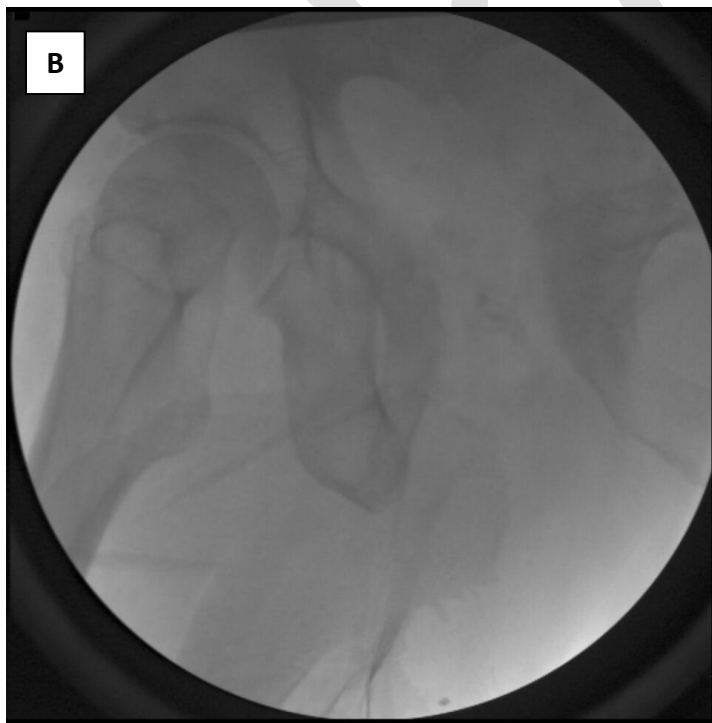
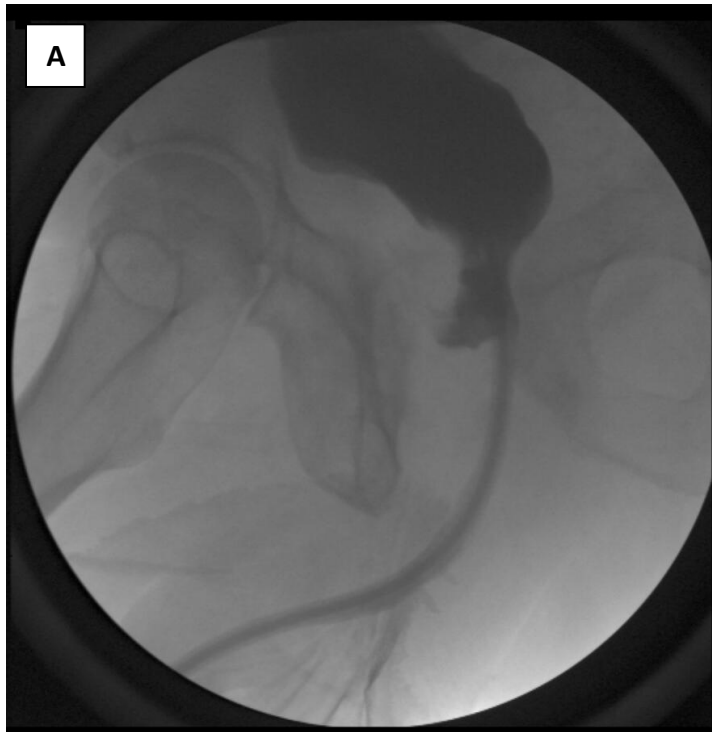
Figure 5. Retrograde urethrogram performed at followup 6 months after initiation of conservative management. There is no evidence of urinary extravasation.

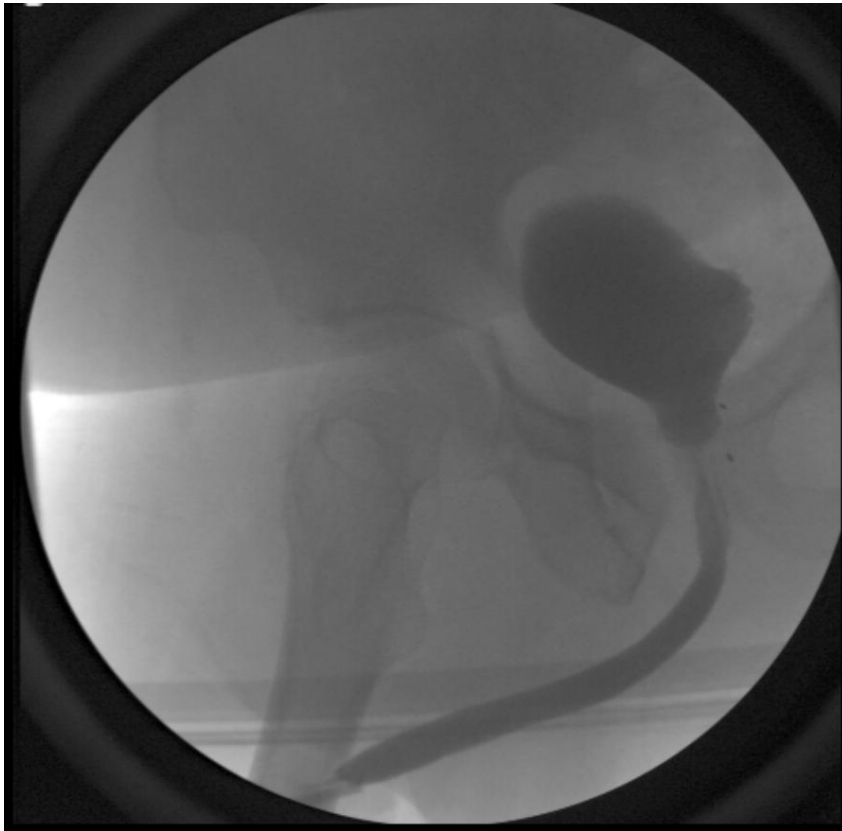

Figure 6. Bone scan and white blood cell scan demonstrating increased uptake at the pubic symphysis but not osteomyelitis.



Age	Prostate size (cc)	Greenlight™ PVP power (Watt)	Time of presentation (days)	Presenting symptoms	Workup	Treatment	Outcomes
68	38	120	4	Bilateral leg swelling and pubic symphysis pain	CT cystogram, VCUG, cystoscopy, MRI	Failed trial antibiotics and Foley open fistula repair with peritoneal interposition flap	Pain improved; SUI and ED
50	16	120	21	Pubic symphysis pain and difficulty ambulating	CT abdomen/pelvis, cystoscopy, cystography, urethrography, MRI	SP catheter and antibiotics	Successful
82	35	120	330	Difficulty ambulating	CT cystogram	Open radical retropubic prostatectomy with debridement of pubic symphysis with antibiotics post-operatively	Pain improved; SUI
65	35	180	7	Urinary retention, bilateral groin pain, difficulty ambulating	Cystoscopy, CT cystogram	Open radical retropubic prostatectomy and debridement of pubic symphysis	–
73	36	180	28	Bilateral groin pain, difficulty ambulating	Cystoscopy, CT cystogram, MRI	Antibiotics	Resolved

73	51	–	–	Pain secondary to obturator abscess	–	Robotic Y-V plasty w/ perivesical tissue and fat flap	–
65	55	180	7	Difficulty ambulating, mild voiding symptoms	MRI	Antibiotics and foley catheter	Successful
Cases at our institution							
86	–	–	14	Pubic symphysis pain and difficulty ambulating	Cystoscopy, CT scan, uroflowmetry and PVR	Antibiotics	Urge Urinary Incontinence
74	29	–	–	Urinary retention, suprapubic pain, difficulty ambulating	Cystoscopy, CT cystogram, MRI	Open repair of prostate, pubic symphysis sequestration	Successful
64	–	–	10	Urinary retention, suprapubic pain, difficulty ambulating	MRI, cystoscopy, RUG	Antibiotics and foley catheter	Successful
63	–	–	60	Dysuria, urgency, incontinence, abdominal and groin pain, hematuria	CT IVP, cystoscopy, pelvis x-ray, bone scan	Antibiotics, robotic laparoscopic prostatectomy	Successful; mild incontinence

CT: computed tomography; ED: erectile dysfunction; IVP: intravenous pyelogram; MRI: magnetic resonance imaging; PVR: postvoid residual; SUI: stress urinary incontinence; VCUG: voiding cystourethrogram.