

# Case - Enterocutaneous fistula 10 years after undergoing tension-free transvaginal tape surgery

Xin Yu Yang<sup>1,2</sup>, Yacine Zaffour<sup>2</sup>, Sarah-Jeanne Cyr<sup>1,3</sup>, Xavier Paré<sup>1,4</sup>

<sup>1</sup>Department of Surgery, Université de Montréal, Montreal, QC, Canada; <sup>2</sup>Faculty of Medicine, Université de Montréal, Montreal, QC, Canada; <sup>3</sup>Division of Urology, Hospital Affiliated University Regional-CIUSSS-MCQ, Trois-Rivières, QC, Canada; <sup>4</sup>Division of General Surgery, Hospital Affiliated University Regional-CIUSSS-MCQ, Trois-Rivières, QC, Canada

Cite as: Yang XY, Zaffour Y, Cyr S-J, et al. Case - Enterocutaneous fistula 10 years after undergoing tension-free transvaginal tape surgery. *Can Urol Assoc J* 2026;20(3):E131-4. <http://dx.doi.org/10.5489/cuaj.9362>

Published online November 25, 2025

## INTRODUCTION

Tension-free vaginal tape (TVT) is a surgical procedure used to treat stress urinary incontinence (SUI) in women when conservative treatments fail. It involves placing a synthetic mesh tape beneath the urethra to provide structural support.<sup>1</sup> Since its development by Petros and Ulmsten in the 1990s, several variants have emerged, including retropubic TVT, transobturator approaches, and mini-slings.<sup>2</sup>

TVT is widely used and effective, with long-term subjective cure rates for the retropubic approach ranging from 51–88%.<sup>3</sup> Common complications include urinary retention (2–4%),<sup>4</sup> bladder perforation (2.5–11.7%), and vaginal or bladder erosion (0.6–5.4%).<sup>5</sup> Significant complications, such as intestinal injury are rare, occurring in 0.03–0.7% of cases.<sup>6</sup> Concerns about complications led to a decline in their use; however, recent renewed interest has revived the debate.<sup>7</sup>

Here, we present the case of a 57-year-old female who developed an enterocutaneous fistula over 10 years after undergoing a TVT procedure.

## CASE REPORT

A 57-year-old female with a body mass index (BMI) of 18.5 kg/m<sup>2</sup> presented with a right suprapubic mass in July 2024. Her past surgical history includes L5-S1 fusion and TVT urethropexy for SUI in 2010.

The patient was initially seen by her primary care physician, and clinical assessment suggested a skin abscess, which was drained; however, she later developed persistent purulent discharge from the site, accompanied by gas emission and a foul odour,

prompting referral to general surgery. Examination showed a right suprapubic cutaneous opening with purulent discharge (Figure 1).

Computed tomography (CT) scan revealed an 82×9×8 mm enterocutaneous fistula from the right lower quadrant to the cecal base following the expected path of the right lateral arm of the TVT sling (Figure 2).

Colonoscopy revealed a foreign body embedded within a fecalith. Attempts at dislodging the object and extensive irrigation revealed a bluish mesh filament partially embedded in the cecal wall (Figure 3). No other abnormalities were noted except for sigmoid diverticulosis.

Based on the clinical and imaging findings, the working diagnosis was an enterocutaneous fistula secondary to TVT mesh erosion into the cecum.

Urology was consulted for collaborative management. Cystoscopy showed no urethral or bladder erosion. Treatment options were discussed, including the resection of the affected bowel segment with partial or complete removal of the TVT mesh. Complete excision was chosen to avoid retained infected material, which could lead to fistula recurrence or pelvic abscess. Potential risks of surgery were explained, including infection, bleeding, anastomotic leak, SUI recurrence, and injury to bowel, urethra, bladder, or vagina.

## Surgical procedure

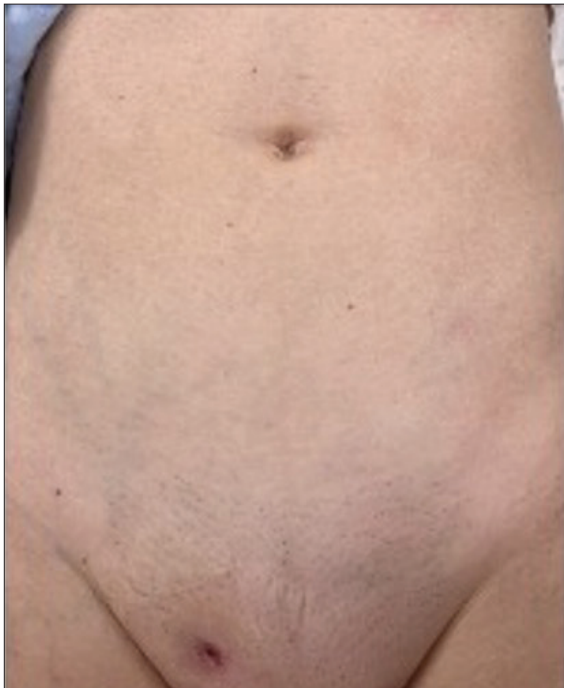This was a joint procedure performed by a urologist and a colorectal surgeon. The patient was placed in Lloyd-Davies position under general anesthesia. A midline infraumbilical laparotomy was performed. Intraoperative exploration revealed an enterocutaneous fistula originating from the base of the cecum in the right iliac fossa (Figure 4). The cecum was mobilized, and the fistulous tract was isolated at its base, leaving the ileocecal valve intact. A cecectomy was performed.

Upon further exploration, the foreign body embedded within the fistulous tract was encountered, consisting of a TVT mesh segment intertwined with a fecalith (Figure 5).

The TVT mesh excision was performed in a step-wise manner. A large urinary catheter was placed to guide the dissection and minimize the risk of urethral

KEY MESSAGES

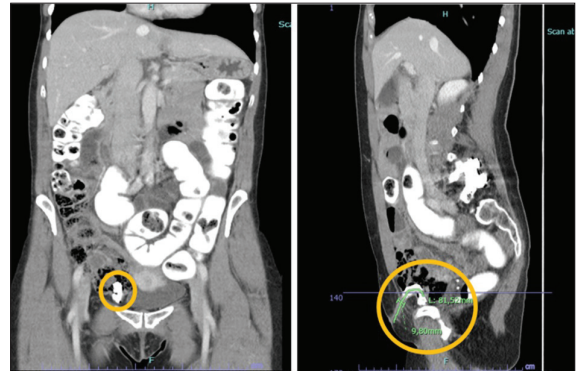
- Enterocutaneous fistula secondary to tension-free vaginal tape mesh erosion is a rare but serious delayed complication.
- Symptoms can manifest years after surgery, requiring a high index of clinical suspicion.
- Definitive management often necessitates a multidisciplinary surgical approach.
- Careful patient selection and thorough preoperative counseling are crucial to minimize long-term risks.



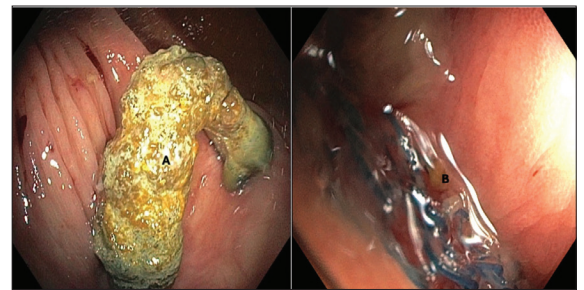
**Figure 1.** External opening of the enterocutaneous fistula located on the right lateral side of the pubis.

injury. An inverted U-shaped vaginal incision was made (Figure 6). The suburethral portion of the sling was identified and meticulously isolated. Dissection was then continued laterally and deeply on both the left and right sides. Subsequently, the dissection was resumed from the abdominal cavity.

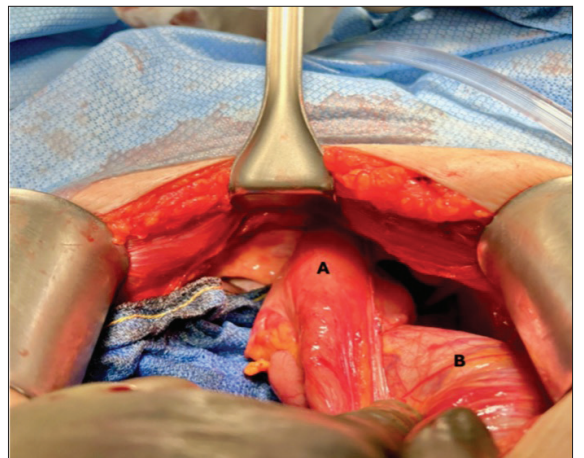
The retropubic portions of the sling arms were identified in the space of Retzius and dissected to connect with the portions already isolated during the vaginal



**Figure 2.** Diagnostic computed tomography scan with contrast enhancement showing the fistulous tract.

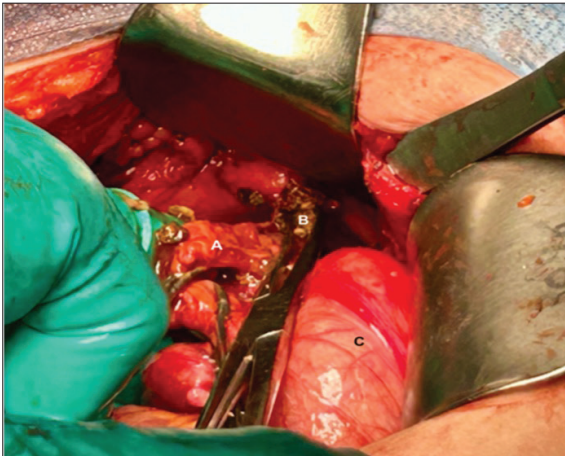


**Figure 3.** Diagnostic colonoscopy showing transvaginal tape (TVT) mesh protruding into the cecum. (A) Foreign body embedded in a fecalith. (B) Blue filament of the TVT mesh.

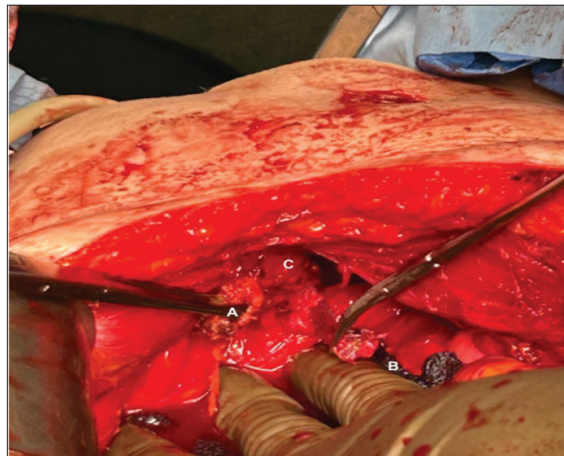


**Figure 4.** Exposure of the enterocutaneous fistula: (A) cecum retracted toward the fistulous tract; (B) ascending colon.

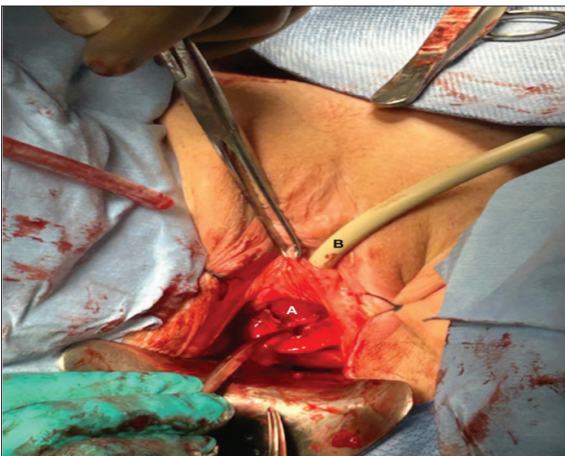
approach. The subcutaneous pathways of the sling were also dissected. The suburethral portion of the sling was then divided, allowing the TVT mesh to be completely removed in two separate segments (Figure 7). The pelvic cavity was irrigated with warm normal saline to clear debris and reduce the risk of contamination. Estimated blood loss was minimal, and the procedure was well tolerated.



**Figure 5.** Cecectomy and transvaginal tape (TVT) mesh segment intertwined with fecalith. (A) Cecectomy; (B) TVT mesh segment intertwined with fecalith; (C) ascending colon.



**Figure 7.** Abdominal transvaginal tape (TVT) excision. (A) Left lateral arm of the TVT; (B) right lateral arm of the TVT; (C) space of Retzius.



**Figure 6.** Vaginal transvaginal tape (TVT) excision. (A) Inverted U-shaped vaginal incision; (B) urinary catheter.

Recovery was initially favorable but complicated by prolonged ileus and adhesive small bowel obstruction, requiring a second laparotomy with adhesiolysis. Bowel function improved gradually with parenteral nutrition, prokinetics, and close monitoring.

## DISCUSSION

This case presents a rare yet severe delayed complication of TVT surgery: enterocutaneous fistula due to mesh erosion into the cecum.

Fistula caused by mesh erosion is a well-documented complication of TVT, typically involving the vagina or bladder, with incidences ranging from 0.6–5.4%;<sup>5</sup> however, bowel perforation is exceedingly rare, with an estimated incidence of 0.036%.<sup>8</sup> In our literature review, multiple cases of bowel perforation caused by TVT have been published.<sup>6,9-13</sup> Reported delays in

symptom onset range from one day to seven years postoperatively. Most perforations involved the small bowel or the sigmoid; cecum perforation occurred only in three cases.

Compared to small bowel perforation, which often presents with peritonitis and sepsis, significant bowel complications tend to present later and incidentally. In this case, symptoms developed more than 10 years after TVT placement, the most extended delay reported to date. This underscores the insidious course of mesh-related complications, warranting long-term clinical vigilance. Prompt imaging and endoscopy are essential for diagnosis and to guide timely surgical management.

Despite one study reporting a fatal small bowel injury in a patient with a BMI of 33 kg/m<sup>2</sup>,<sup>14</sup> most literature highlights low BMI and prior pelvic surgery as key risk factors.<sup>9,13,15</sup> Patients with a low BMI, such as ours (18.5 kg/m<sup>2</sup>), may be at an increased risk due to reduced subcutaneous fat. In both obese and thin individuals, anatomical variability complicates blind TVT passage and increases procedural risk.

While exploratory laparotomy remains the most commonly reported approach, successful laparoscopic resections, partial or complete, combined with vaginal mesh removal, have also been described.<sup>9</sup> In our case, a shared decision was made with the patient to proceed with complete TVT mesh excision to minimize the risk of future complications. Laparotomy was preferred to ensure thorough resection of both the mesh and the fistulous tract. Partial mesh removal has also shown favorable outcomes, with continence preserved.<sup>6,10,12</sup>

Variable approaches have been described to treat recurrent SUI after TVT removal. Mayhew et al performed the placement of a fascial pubovaginal sling dur-

ing the same operation, achieving satisfactory results at six-month followup.<sup>9</sup> Alternatively, delayed intervention may be considered. A fascial pubovaginal sling should be preferred, although a synthetic midurethral sling may be considered.<sup>10,11</sup>

## CONCLUSIONS

This case highlights a rare and delayed complication of TVT surgery, an enterocutaneous fistula due to mesh erosion into the cecum. While bowel perforation is rare, this case demonstrates that symptoms can occur years after the surgery, emphasizing the need for a high index of suspicion and timely diagnosis. Managing mesh-related complications requires a multidisciplinary approach involving both urology and general surgery. This case also underscores the importance of careful patient selection and clear preoperative counseling, especially for those with risk factors such as a history of pelvic surgery or extreme BMI. Transparency and informed consent are crucial to ensure that patients understand the potential risks associated with TVT procedures.

COMPETING INTERESTS: The authors do not report any competing personal or financial interests related to this work.

This paper has been peer-reviewed.

## REFERENCES

- Carlson K, Andrews M, Bascom A, et al. 2024 Canadian Urological Association guideline: Female stress urinary incontinence. *Can Urol Assoc J* 2024;18:83-102. <https://doi.org/10.5489/cuaj.8751>
- Petros PE, Ulmsten UI. An integral theory of female urinary incontinence. Experimental and clinical considerations. *Acta Obstet Gynecol Scand Suppl* 1990;153:7-31. <https://doi.org/10.1111/j.1600-0412.1990.tb08027.x>
- Ford A. A, Taylor V, Ogah J, et al. Midurethral slings for treatment of stress urinary incontinence review. *Neurourol Urodyn* 2019;38:570-5. <https://doi.org/10.1002/nau.24030>
- Geller EI. Prevention and management of postoperative urinary retention after urogynecologic surgery. *Int J Womens Health* 2014;6:829-38. <https://doi.org/10.2147/IJWH.S55383>
- Novara G, Galfano A, Boscolo-Berto R, et al. Complication rates of tension-free midurethral slings in the treatment of female stress urinary incontinence: a systematic review and meta-analysis of randomized controlled trials comparing tension-free mid-urethral tapes to other surgical procedures and different devices. *Eur Urol* 2008;53:288-308. <https://doi.org/10.1016/j.euro.2007.10.073>
- Huang X, Jiang H, Xie L. Case report of sigmoid colon perforation and colocutaneous fistula due to retropubic mid-urethral sling placement for stress urinary incontinence. *BMC Urol* 2020;20:33. <https://doi.org/10.1186/s12894-020-00600-x>
- Wu K, Huang E, Kobashi KC. Evolution of stress urinary incontinence (SUI) outcomes assessment: A narrative review. *Gynecol Pelvic Med* 2024;7. <https://doi.org/10.21037/gpm-24-21>
- Tamussino KF, Hanzal E, Kölle D, et al. Tension-free vaginal tape operation: Results of the Austrian registry. *Obstet Gynecol* 2001;98:732-6. <https://doi.org/10.1097/00006250-200111000-00005>
- Mayhew AC, Ford AT, Northington GM, et al. Delayed presentation of cecal perforation with tension-free vaginal tape. *Obstet Gynecol* 2018;131:499-502. <https://doi.org/10.1097/AOG.0000000000002495>
- Fourie T, Cohen PL. Delayed bowel erosion by tension-free vaginal tape (TVT). *Int Urogynecol J Pelvic Floor Dysfunct* 2003;14:362-4. <https://doi.org/10.1007/s00192-003-1068-x>
- Lee IK, Sohn DW. Delayed sigmoid colon perforation and enterocutaneous fistula due to tension free transvaginal tape operation for stress urinary incontinence. *Can Urol Assoc J* 2015;9:E208-9. <https://doi.org/10.5489/cuaj.2680>
- Meschia M, Busacca M, Pifarotti P, et al. Bowel perforation during insertion of tension-free vaginal tape (TVT). *Int Urogynecol J Pelvic Floor Dysfunct* 2002;13:263-5. <https://doi.org/10.1007/s001920200055>
- Elliott JE, Maslow KD. Remote discovery of an asymptomatic bowel perforation by a mid-urethral sling. *Int Urogynecol J* 2012;23:243-5. <https://doi.org/10.1007/s00192-011-1510-4>
- Kascak P, Kopcan B. Fatal Injury of the Small Intestine during retropubic sling placement. *Case Rep Obstet Gynecol* 2015;2015:164545. <https://doi.org/10.1155/2015/164545>
- Phillips L, Flood CG, Schulz JA. Case report of tension-free vaginal tape-associated bowel obstruction and relationship to body habitus. *Int Urogynecol J Pelvic Floor Dysfunct* 2009;20:367-8. <https://doi.org/10.1007/s00192-008-0722>

CORRESPONDENCE: Dr. Xavier Paré, Division of General Surgery, Hospital Affiliated University Regional-CIUSS-MCQ, Trois-Rivières, QC, Canada; [xavier.pare@umontreal.ca](mailto:xavier.pare@umontreal.ca)