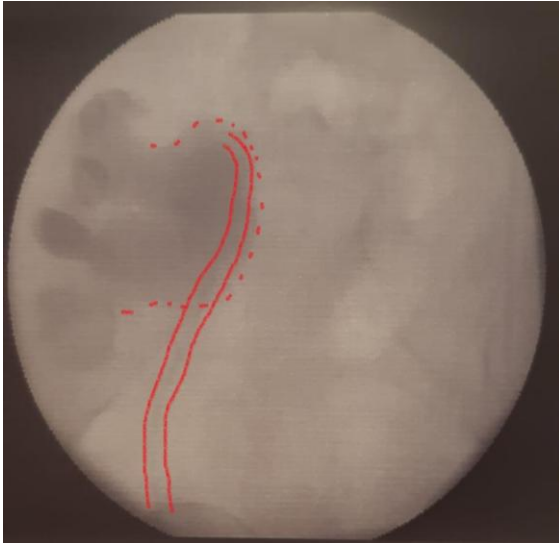


**APPENDIX**

**Supplementary Figure 1.** Pyelography demonstrating pelvic dilation in an inverted kidney allograft (IKA) patient.



**Supplementary Figure 2.** Mid-ureter obstruction in an inverted kidney allograft (IKA) patient.

