

# Case series – Beyond the stones: Thulium fiber laser-induced renal damage in children with proximal ureteral narrowing

Hooman Ebrahimi<sup>1</sup>, Samer Maher<sup>1</sup>, Joana Dos Santos<sup>2</sup>, Frank Papanikolaou<sup>3</sup>, Armando Lorenzo<sup>1,4</sup>, Mandy Rickard<sup>1</sup>, Yonah Krakowsky<sup>4,5</sup>, Michael Chua<sup>1,4,6</sup>

<sup>1</sup>Division of Urology, Hospital for Sick Children, Toronto, ON, Canada; <sup>2</sup>Division of Pediatric Medicine, Department of Pediatrics, The Hospital for Sick Children, Toronto, ON, Canada; <sup>3</sup>Division of Urology, Trillium Health Partners, Mississauga, ON, Canada; <sup>4</sup>Division of Urology, Department of Surgery, University of Toronto, Toronto, ON, Canada; <sup>5</sup>Women's College Research Institute, Women's College Hospital, Toronto, ON, Canada; <sup>6</sup>Institute of Urology, St. Luke's Medical Center, Quezon City, NCR, Philippines

Cite as: Ebrahimi H, Maher S, Dos Santos J, et al. Case series – Beyond the stones: Thulium fiber laser-induced renal damage in children with proximal ureteral narrowing. *Can Urol Assoc J* 2026;20(1):E63-6. <http://dx.doi.org/10.5489/auaj.9304>

Published online September 23, 2025

## INTRODUCTION

The global incidence of pediatric nephrolithiasis continues to rise, driving advancements in diagnosis and treatment.<sup>1</sup> Compared to adults, pediatric stone management demands greater consideration due to anatomic and physiologic differences, including smaller operative fields, ongoing renal development, and more frequent congenital anomalies, necessitating treatment choices that prioritize efficacy and safety.<sup>2</sup>

Endoscopic laser lithotripsy has emerged as the preferred modality for pediatric stone management, offering high precision, minimal invasiveness, and excellent stone clearance rates.<sup>3</sup> The photothermal mechanism of laser lithotripsy enables fragmentation by vaporizing water molecules near the stone surface, generating shockwaves that effectively disintegrate calculi.<sup>4</sup> While the Holmium:YAG (Ho:YAG) laser has long been the standard for lithotripsy, the thulium fiber laser (TFL) has gained recent attention due to smaller fiber diameter, increased ablation efficiency, and shorter operative times.<sup>5,6</sup> TFL's higher water absorption coefficient enables more localized energy delivery and potentially reduces thermal spread.<sup>7</sup>

Recent studies have raised concern over the thermal safety of TFL, especially in anatomically complex or high-power scenarios. While complications like ureteral stricture have been increasingly reported in adults, there is a lack of corresponding pediatric data.<sup>8,9</sup> Reporting these two cases highlights potential TFL-

related complications in children with proximal ureteral narrowing and underscores the need for clinical vigilance and adapted techniques in high-risk scenarios.

## CASE REPORTS

### Case 1

A previously healthy four-year-old boy presented with painless gross hematuria. Renal imaging revealed a 1.3 cm left lower pole stone with focal caliectasis (Figure 1A). Subsequent metabolic evaluation diagnosed the patient with primary hyperoxaluria type 3. He was scheduled for ureteroscopy with laser lithotripsy.

Intraoperatively, retrograde pyelogram revealed a significant proximal ureteral stenosis (Figure 1B). Initial 6 Fr double-J (DJ) stenting was performed in the first surgery for passive ureteral dilation; however, failed attempts to traverse the narrowing during the subsequent operation prompted further passive dilation with an 8.5 Fr DJ stent.

In the third procedure, a 9.5 Fr access sheath was placed distal to the ureteral narrowing, allowing successful advancement of the 7.5 Fr ureteroscope into the renal pelvis. Laser lithotripsy was performed using dusting settings (20 W, 200 Hz, 0.1 J) for nearly 13 minutes with approximately 137 900 pulses and a total delivered energy of 13.79 kJ.

Upon completion of the procedure, the collecting system was flushed and evacuated without complication. After one month, second-look ureteroscopy was performed; proximal ureteral narrowing persisted, and the patient did not require additional lithotripsy.

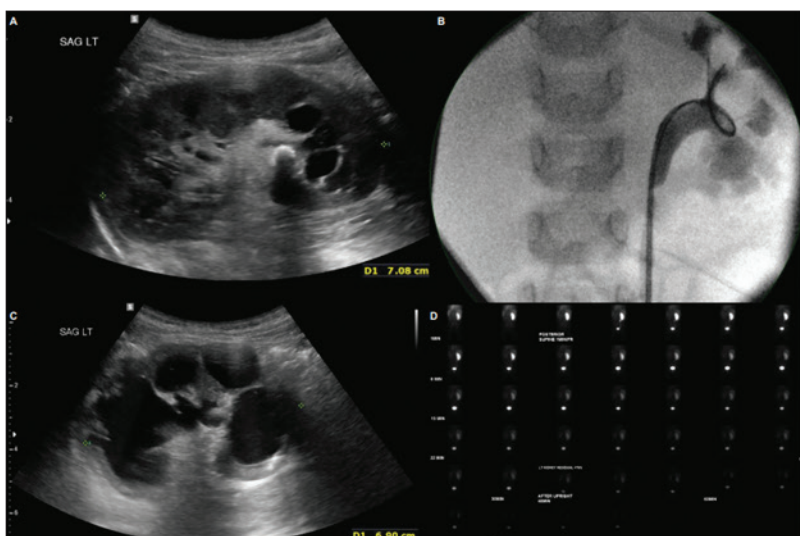
Approximately six months later, the patient developed new-onset hypertension, requiring escalating doses of amlodipine up to 4 mg/day. Ultrasound demonstrated calyceal dilation, parenchymal thinning of the left kidney, and renal pelvis contraction (Figure 1C). A Lasix renography showed negligible tracer uptake of the left kidney.

The dimercaptosuccinic acid (DMSA) scan revealed severely diminished differential renal function of 3% in the left kidney (Figure 1D). Due to persistent hypertension and a non-functioning kidney, a left nephrectomy was performed.

Final histopathology revealed global cortical and medullary atrophy, diffuse interstitial fibrosis, dilated but

## KEY MESSAGES

- High-power thulium fiber laser (TFL) lithotripsy can lead to thermal injury in children with proximal ureteral narrowing.
- Ureteral narrowing restricts fluid irrigation return flow, thereby increasing the risk of elevated intrarenal temperature during TFL lithotripsy.
- Consider using cold or room temperature fluid irrigation, power settings <16 W, and evaluate preoperative dilation or PCNL for complex cases.



**Figure 1.** (A) Initial ultrasound. (B) Proximal ureteral stenosis on retrograde pyelogram. (C) Seven-month ultrasound followup, demonstrating parenchymal thinning and significant calyceal dilation. (D) Lasix scan with severe reduced uptake and retention.

scarred calyces, and a contracted renal pelvis. Minimal glomerulosclerosis was also present. Postoperatively, the patient's blood pressure normalized rapidly, allowing discontinuation of antihypertensive therapy within one month. The patient was metabolically managed by nephrology and controlled, with no stone recurrence after 24 months.

### Case 2

A 21-month-old boy with no prior history presented with gross hematuria, fever, and vomiting for one week. Imaging showed significant stone burden: multiple large bladder stones (6–7 cm total) and a 2.1 cm left renal calculus (Figure 2A), with the right kidney largely unaf-

fected. Metabolic workup confirmed primary hyperoxaluria type 2. Initial treatment included cystoscopic laser lithotripsy for bladder stones and left ureteral stent placement. While bladder stones were cleared, persistent left nephrolithiasis required further intervention.

The patient subsequently underwent ureteroscopy with laser lithotripsy targeting the renal calculi. Intraoperatively, two narrowed segments were identified at the proximal ureter (Figure 2B); a 9.5 Fr access sheath was parked distal to the narrowed segment, and a 7.5 Fr ureteroscope was advanced. Laser lithotripsy was performed using 20 W power, 200 Hz frequency, and 0.1 J pulse energy, with cumulative energy delivered of 39 kJ and a total laser time of 34 minutes. A second session addressed residual stones, but a subsequent retrograde-nephroscopy was aborted due to inability to traverse the narrowed ureteral segment.

Followup ultrasound showed reduced corticomedullary differentiation, indicating irreversible parenchymal damage. Also, the renal pelvis was not visualized (Figure 2C). Postoperative Lasix renography revealed 32% left kidney function, absent of lower pole tracer uptake, with severely delayed drainage without the renal pelvis outline ( $T_{1/2}$ =57 minutes; 96% retention at 20 minutes) (Figure 2D). Pyeloplasty was initially planned; however, intraoperatively, the renal pelvis was noted to be contracted. Ureterocalycostomy was ultimately performed to preserve residual function.

### DISCUSSION

Management of pediatric nephrolithiasis has introduced significant clinical challenges due to anatomical, metabolic, and developmental differences compared to adults. Children are more likely to have congenital anomalies, reduced spontaneous stone passage, and increased risk for recurrent stones, all of which complicate treatment.<sup>10</sup>

While the emergence of TFL provides improved stone ablation and smaller fiber diameters, increasing reports have raised concerns about thermal damage associated with high-power and prolonged activation, particularly in cases with poor irrigation outflow.<sup>8,9</sup> Ureteral narrowing allows partial urine passage but compromises ureteroscopic manipulation, fluid drainage, and further instrumentation, such as access sheath usage. This partial obstruction alters intraoperative dynamics, including irrigation outflow and pressure regulation.

Despite appropriate passive dilatation using a ureteral stent in both cases, access sheath placement remained difficult during endoscopic stone manage-

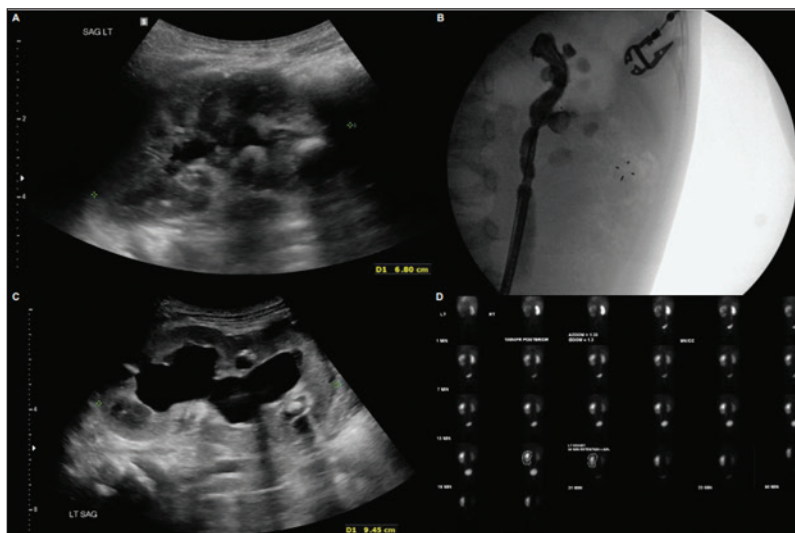
ment proximal to the ureteral narrowing. Coupled with impaired irrigation fluid outflow, this likely contributed to excessive intrarenal temperature elevations during TFL lithotripsy. Although TFL generates less deep tissue heating, inadequate irrigation can still lead to significant temperature rise and thermal injury.<sup>11</sup> While guidelines discourage routine pre-stenting before ureteroscopy, they may not apply to complex pediatric anatomy. Pre-stenting can serve as passive dilation in such contexts, improving access and irrigation.<sup>12</sup>

In our experience, one patient required staged dilation via stenting to permit safe access, while in the other, a narrow but passable lumen allowed initial access, although complications still ensued. These cases highlight the need for flexibility in applying adult-derived guidelines to children with complex anatomy.

Temperature control during laser lithotripsy should be a critical safety consideration. Standards recommend warmed isotonic irrigation fluids to prevent systemic hypothermia.<sup>10</sup> Emerging in vitro studies suggest that cooler irrigation can reduce localized thermal build-up during high-energy lithotripsy; however, this must be balanced against the risk of systemic hypothermia due to higher pediatric surface-area-to-volume ratio.<sup>13</sup> Moreover, low irrigation flow rates, especially when restricted by strictures, are associated with greater intrarenal temperature increases.<sup>14,15</sup>

These two pediatric cases highlight the rare but serious risk of thermal injury and irreversible renal parenchymal loss after TFL lithotripsy in the presence of proximal ureteral narrowing. While TFL improves stone clearance during retrograde intrarenal surgery (RIRS), impaired urinary drainage can lead to fluid retention and elevated intrarenal temperatures. In response to the two presented cases and growing concerns surrounding thermal injury during lithotripsy, we not only recommend but have also implemented the following safety measures at our institution:

- Employing cold or room-temperature irrigation when thermal risk is high, limiting laser power to under 16 W, per manufacturer's recent recall, ensuring continuous irrigation with frequent decompression, and access sheath placement into renal pelvis whenever feasible.
- In anatomically complex cases, addressing ureteral narrowing preoperatively via prolonged stenting or surgical correction may be warranted.
- A percutaneous approach may offer a safer alternative for patients with high stone burden and compromised drainage.



**Figure 2.** (A) Initial ultrasound. (B) Retrograde pyelogram, with stenotic rings at proximal ureter. (C) Five-month followup ultrasound, with high-grade renal dilation and reduced corticomedullary differentiation. (D) Lasix scan, illustrating function reduction and severely delayed drainage.

These cases highlight the need for thorough pre- and intraoperative assessment, and tailored planning to prevent thermal injury with TFL in complex pediatric patients.

## CONCLUSIONS

While TFL has theoretical benefits for pediatric lithotripsy, its use in congenital proximal ureteral narrowing requires caution. These cases underscore the need for individualized preoperative planning, dilation strategies, and close intraoperative monitoring of irrigation and temperature. Given the risk of long-term renal damage, future research should develop pediatric-specific guidelines on laser physics, anatomical variation, and renal preservation to improve outcomes in high-risk patients.

COMPETING INTERESTS: The authors do not report any competing personal or financial interests related to this work.

## REFERENCES

1. Tasian GE, Ross ME, Song L, et al. Annual incidence of nephrolithiasis among children and adults in South Carolina from 1997 to 2012. *Clin J Am Soc Nephrol* 2016;11:488-96. <https://doi.org/10.2215/CJN.07610715>
2. Kalarin CM, Zabinski A, Okpareke I, et al. Pediatric urinary stone disease—does age matter? *J Urol* 2009;181:2267-71. <https://doi.org/10.1016/j.juro.2009.01.050>
3. Whatley A, Jones P, Aboumarzouk O, et al. Safety and efficacy of ureteroscopy and stone fragmentation for pediatric renal stones: A systematic review. *Transl Androl Urol* 2019;8:442-7. <https://doi.org/10.21037/tau.2019.08.23>
4. Chan KF, Vassar GJ, Pfefer TJ, et al. Holmium:YAG laser lithotripsy: A dominant photothermal ablative mechanism with chemical decomposition of urinary calculi. *Lasers Surg Med* 1999;25:22-37. [https://doi.org/10.1002/\(SICI\)1096-9101\(1999\)25:1<22::AID-LSM4>3.0.CO;2-6](https://doi.org/10.1002/(SICI)1096-9101(1999)25:1<22::AID-LSM4>3.0.CO;2-6)
5. Chua ME, Bobrowski A, Ahmad I, et al. Thulium fibre laser vs holmium:YAG laser lithotripsy for urolithiasis: Meta-analysis of clinical studies. *BJU Int* 2023;131:383-94. <https://doi.org/10.1111/bju.15921>

6. Ulvik Ø, Aesøy MS, Julieba-Jones P, et al. Thulium fibre laser versus holmium:YAG for ureteroscopic lithotripsy: Outcomes from a prospective randomised clinical trial. *Eur Urol* 2022;82:73-9. <https://doi.org/10.1016/j.eururo.2022.02.027>
7. Kronenberg P, Traxer O. The laser of the future: Reality and expectations about the new thulium fiber laser—a systematic review. *Transl Androl Urol* 2019;8:398-417. <https://doi.org/10.21037/tau.2019.08.01>
8. Wanderling C, Saxton A, Phan D, et al. Getting hot in here! comparison of holmium vs thulium laser in an anatomic hydrogel kidney model. *Urolithiasis* 2024;52:49. <https://doi.org/10.1007/s00240-024-01541-y>
9. Aesøy MS, Julieba-Jones P, Beisland C, et al. Temperature profiles during ureteroscopy with thulium fiber laser and holmium:YAG laser: Findings from a pre-clinical study. *Scand J Urol* 2022;56:313-9. <https://doi.org/10.1080/21681805.2022.2104367>
10. Lao M, Kogan BA, White MD, et al. High recurrence rate at 5-year followup in children after upper urinary tract stone surgery. *J Urol* 2014;191:440-4. <https://doi.org/10.1016/j.juro.2013.09.021>
11. Ortner G, Rice P, Nagele U, et al. Tissue thermal effect during lithotripsy and tissue ablation in endourology: A systematic review of experimental studies comparing holmium and thulium lasers. *World J Urol* 2023;41:1-12. <https://doi.org/10.1007/s00345-022-04242-6>
12. Pearle MS, Goldfarb DS, Assimos DG, et al. Medical management of kidney stones: AUA guideline. *J Urol* 2014;192:316-24. <https://doi.org/10.1016/j.juro.2014.05.006>
13. Dau JJ, Hall TL, Maxwell AD, et al. Effect of chilled irrigation on caliceal fluid temperature and time to thermal injury threshold during laser lithotripsy: In vitro model. *J Endourol* 2021;35:700-5. <https://doi.org/10.1089/end.2020.0896>
14. Hein S, Petzold R, Schoenthaler M, et al. Thermal effects of Ho:YAG laser lithotripsy: Real-time evaluation in an in vitro model. *World J Urol* 2018;36:1469-75. <https://doi.org/10.1007/s00345-018-2303-x>
15. Liang H, Liang L, Yu Y, et al. Thermal effect of holmium laser during ureteroscopic lithotripsy. *BMC Urol* 2020;20:69. <https://doi.org/10.1186/s12894-020-00639-w>

CORRESPONDENCE: Dr. Hooman Ebrahimi, Division of Urology, Hospital for Sick Children, Toronto, ON, Canada; ahooman.ebr@gmail.com