

Techniques – A new method to insert indwelling ureteral stent through the flexible cystoscopy working channel in challenging cases

Nasir Mahmood

Western Memorial Regional Hospital, Corner Brook, NL, Canada

Cite as: Mahmood N. Techniques – A new method to insert indwelling ureteral stent through the flexible cystoscopy working channel in challenging cases. *Can Urol Assoc J* 2025 July 28; Epub ahead of print. <http://dx.doi.org/10.5489/cuaj.9169>

Published online July 28, 2025

Corresponding author: Dr. Nasir Mahmood, Western Memorial Regional Hospital, Corner Brook, NL, Canada; nmnasirmahmood@gmail.com

INTRODUCTION

I introduced a new method of inserting an indwelling ureteral stent (IUS) through the flexible cystoscopy working channel, preventing guide wire buckling in the urinary bladder. This technique appears to be previously undocumented.

METHOD

The use of flexible cystoscopy for the insertion of J stents under local anesthesia in a cystoscopy suite, rather than the main operating room, is becoming increasingly common.^{1,2,3,4} However, the guidewire can sometimes buckle in the bladder, making it time-consuming and frustrating to straighten. Previously, we described a technique to address this issue. Here, I present an improved method that utilizes instruments already available in the flexible cystoscopy tray.⁵ The required instruments include a flexible cystoscope, a IUS 4.8 x multi-length (Contour VL by Boston Scientific), a guide wire (150 cm x 0.35 inches Motion Hybrid wire guide by Cook), and a 5F open-ended ureteric catheter.

After inserting the guidewire through the ureteric catheter and confirming its proper placement in the renal pelvis via fluoroscopy after retrograde pyelogram, the ureteric catheter is removed. At this stage, the ureteric catheter is cut 10 cm from the flexible end containing markings. (Picture 1). This shortened segment will serve as a pusher for stent positioning. The shortening allows the guide wire to exit through the proximal end of the ureteric catheter after being loaded behind the IUS. The wire is then backloaded through the working channel of the flexible cystoscope. (Picture 2)

The IUS is inserted over the guidewire through the working channel of the flexible cystoscope, which is positioned at the bladder neck. (Picture 3). Subsequently, the IUS is

advanced over the guidewire through the working channel using the stiffer unmarked end of the ureteric catheter as a pusher. (Picture 4)

Once the IUS is properly positioned in the renal pelvis under fluoroscopy, the guidewire is removed while the lower end of the IUS is released at the bladder neck under direct vision with the flexible cystoscope. (picture 5). The position of the upper end is confirmed with fluoroscopy.

CONCLUSIONS

If the guidewire buckles in the bladder during JS insertion, use the flexible cystoscopy's working channel to stabilize the wire and insert JS easily. This can often eliminate the need for performing the procedure in the operating room under general anesthesia.

DRAFT

REFERENCES

1. Sivalingam S, Tamm-Daniels I, Nakada SY. Office-based ureteral stent placement under local anesthesia for obstructing stones is safe and efficacious. *Urology* 2013;81:498-502. <https://doi.org/10.1016/j.urology.2012.10.021>
2. Carrion A, D'Anna M, Costa-Grau M, et al. Office stent placement under local anesthesia is a safe and efficient procedure for the management of multiple ureteral disorders. *Actas Urol Esp (Engl Ed)* 2018;42:126-32. <https://doi.org/10.1016/j.acuro.2017.06.006>
3. Nourparvar P, Leung A, Shrewsbury AB, et al. Safety and efficacy of ureteral stent placement at the bedside using local anesthesia. *J Urol* 2016;195:1886-90. <https://doi.org/10.1016/j.juro.2015.11.083>
4. Cheon PM, Visram K, Malik S, et al. MP04-14 ureteral stent insertion under local anesthesia: A single-centre experience. *J Urol* 2024;211:e40. <https://doi.org/10.1097/01.JU.0001008708.00982.a9.14>
5. Mahmood N, Pasha T. A new technique to prevent curling of guide wire in urinary bladder during J stent insertion with flexible cystoscope. *Can Urol Assoc J* 2016;10:E34-5. <https://doi.org/10.5489/cuaj.3079>

DRAFT

FIGURES AND TABLES

Figure 1. Ureteric catheter shortened.

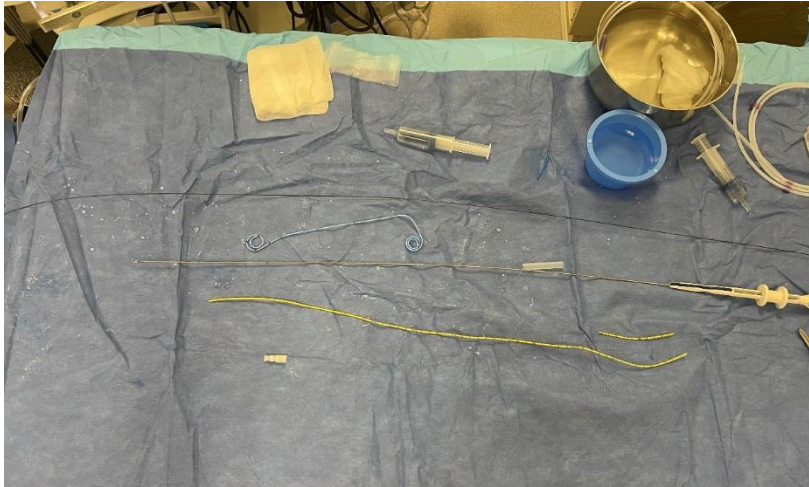

Figure 2. Guidewire backloaded in working channel.

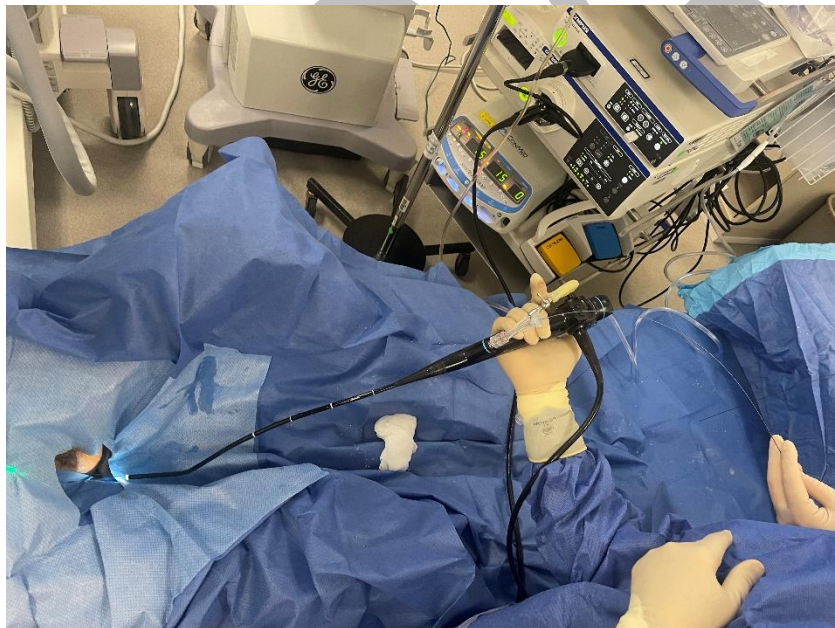

Figure 3. Indwelling ureteral stent loaded over guidewire.

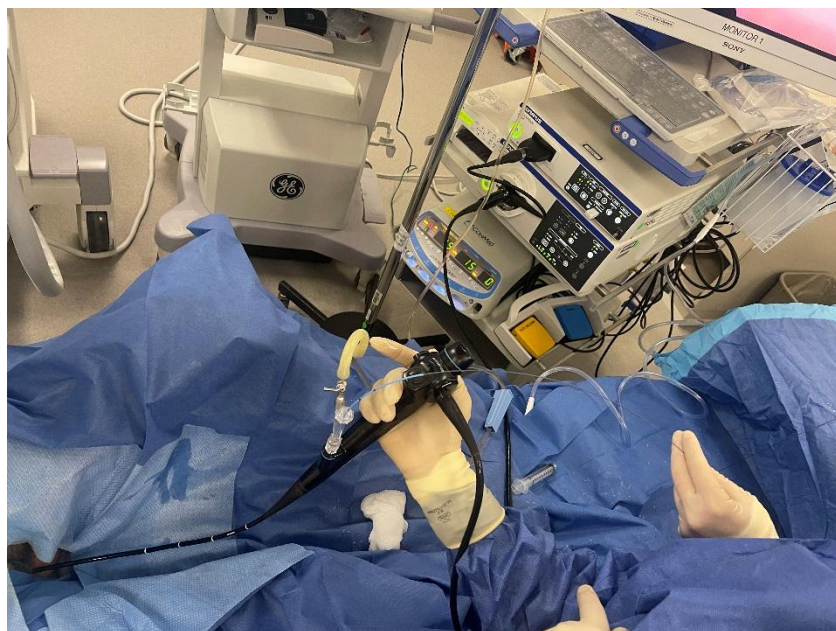

Figure 4. Ureteric catheter loaded as pusher.

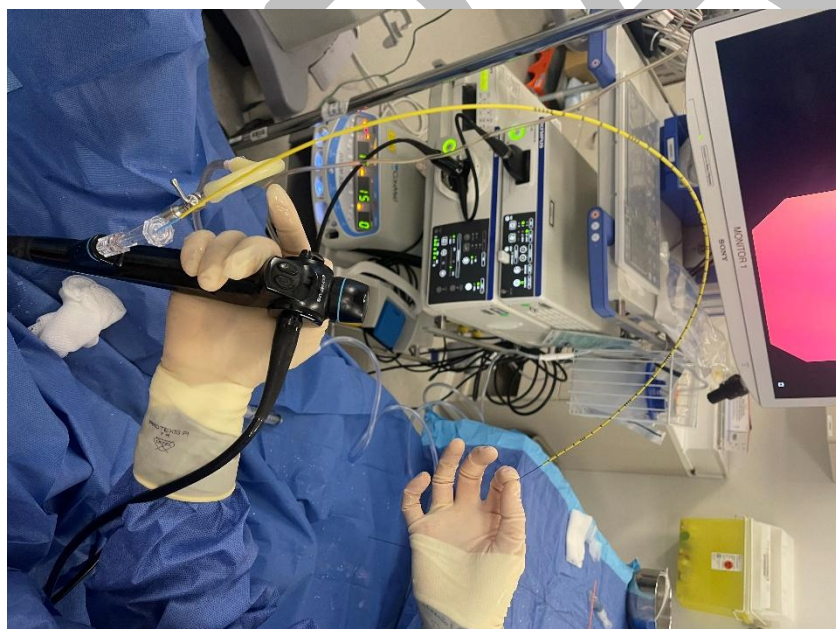


Figure 5. Ureteric catheter holding indwelling ureteral stent distal end in position.

