

Does the digital rectal exam still provide value in the age of MRI?

Patrick Albers¹, Noushin Miandashti¹, Stacey Broomfield¹, Adam Kinnaird^{1,2,3,4,5}

¹Division of Urology, Department of Surgery, University of Alberta, Edmonton, AB, Canada; ²Alberta Prostate Cancer Research Initiative (APCaRI), Edmonton, AB, Canada; ³Cancer Research Institute of Northern Alberta (CRINA), University of Alberta, Edmonton, AB, Canada; ⁴Alberta Centre for Urologic Research and Excellence (ACURE); ⁵Department of Oncology, University of Alberta, Edmonton, AB, Canada

Cite as: Albers P, Miandashti N, Broomfield S, et al. Does the digital rectal exam still provide value in the age of MRI? *Can Urol Assoc J* 2025;19(10):357-60. <http://dx.doi.org/10.5489/cuaj.9164>

Published online July 8, 2025

ABSTRACT

INTRODUCTION: Accurate staging of prostate cancer is essential for treatment planning and prognosis. While digital rectal exam (DRE) has traditionally been used, its limitations in detecting extracapsular extension (ECE) have led to increased reliance on multiparametric magnetic resonance imaging (mpMRI).

METHODS: This study compared outcomes between T3 prostate cancer diagnosed by DRE vs. mpMRI only (i.e., not T3 by DRE) using data from the Alberta Prostate Cancer Research Initiative. The cohort included all 536 patients with cT3NxMx prostate cancer diagnosed between July 2014 and July 2024. The primary outcome was overall survival, with secondary outcomes including age at diagnosis, prostate-specific antigen (PSA) at diagnosis, treatment modality, Gleason grade group, and metastasis at diagnosis.

RESULTS: Patients diagnosed as T3 by DRE were significantly older (71.6 vs. 67.9, $p < 0.001$), had higher PSA levels (32% vs. 11% PSA > 20 ng/ml, $p < 0.001$), and higher Gleason grade groups (39% vs. 15% GG4+, $p < 0.001$) compared to those diagnosed by mpMRI. DRE-diagnosed patients underwent radiation therapy and primary androgen deprivation therapy more frequently than MRI-diagnosed patients. DRE-diagnosed patients also had higher rates of metastases at diagnosis (16% vs. 5%, $p < 0.001$) and worse overall survival (hazard ratio 4.6, 95% confidence interval 1.4–15.0, $p = 0.002$).

CONCLUSIONS: T3 prostate cancer diagnosed by DRE is associated with more advanced disease, higher metastasis rates, and worse survival compared to mpMRI-diagnosed T3 disease. These findings suggest that T3 disease identified by DRE represents a more aggressive cancer subtype and should be considered higher-risk in clinical decision-making.

INTRODUCTION

Prostate cancer staging plays a crucial role in determining treatment strategies and predicting patient outcomes.^{1,2} Traditionally, digital rectal exam (DRE) has been used for prostate cancer screening and clinical staging; however, its subjective nature and limited ability to detect extracapsular extension (ECE) in early stages have raised concerns about its accuracy in identifying T3 disease.^{3,4}

In contrast, multiparametric magnetic resonance imaging MRI (mpMRI) offers high-resolution imaging of the prostate and surrounding structures, allowing for improved detection of ECE. The enhanced precision enables more nuanced patient risk stratification, potentially reclassifying individuals into higher-risk categories. This refined categorization, which currently does not differentiate between T3 tumors identified by mpMRI vs. DRE, carries profound implications for treatment protocols and prognostic assessments.⁵

There remains a need for analyses directly comparing outcomes between T3 prostate cancer diagnosed by mpMRI vs. DRE. Our study aimed to address this knowledge gap by comparing these two groups using data from the Alberta Prostate Cancer Research Initiative (APCaRI).

METHODS

A total of 536 patients with clinical T3 prostate cancer at diagnosis, whether by mpMRI alone (with DRE staging less than T3) or by DRE, were included from APCaRI, a prospective cohort collected from the two primary urology referral centers

KEY MESSAGES

- DRE-identified T3 disease predicts worse prognosis than mpMRI-identified T3 disease.
- This distinction highlights the need for refined risk stratification.

in Alberta.⁶ This study included all patients with clinical T3 prostate cancer at diagnosis enrolled from July 1, 2014, to July 16, 2024. There were 367 men diagnosed with cT3NxMx by DRE (regardless of MRI disease) and 169 men diagnosed with cT3NxMx by MRI, with DRE staging \leq cT2. Staging and enrollment of patients in the APCaRI cohort is by any of the urologists at the University of Alberta or the University of Calgary that treat patients with prostate cancer. Clinical staging at the time of diagnosis is taken from the urologists' clinical judgement and notes. This study protocol was approved by the Health Research Ethics Board of Alberta (HREBA.CC-23-0100).

The primary outcome of this study was overall survival for T3 disease diagnosed by mpMRI vs DRE. Secondary variables include age at diagnosis, prostate-specific antigen (PSA) at diagnosis, initial treatment modality, Gleason grade group, metastasis at diagnosis, and metastasis-free survival. Statistical analyses were performed using Chi-squared, independent t-test, Fisher's exact test, Kaplan-Meier survival estimates and Cox regression analysis where appropriate. All statistical tests were two-tailed, with a significance level set at $p < 0.05$. The study adhered to the STROBE guidelines for cohort studies. SPSS version 29 was used for all statistical analysis.

RESULTS

Patient demographics and tumor characteristics at the time of T3 prostate cancer diagnosis are shown in Table 1. In this cohort, men diagnosed with T3 disease by DRE were significantly older at diagnosis compared to those diagnosed by mpMRI (71.6 vs. 67.9 years, $p < 0.001$), had a higher PSA (31.9% vs. 10.7% PSA > 20 ng/mL, $p < 0.001$), and significantly higher Gleason grade group (38.4% vs. 14.8% \geq GG4, $p < 0.001$). There was no significant difference in the median followup duration between the men diagnosed by DRE or by mpMRI (39 vs. 37.3 months, $p = 0.24$) or in Charlson comorbidity index (96% vs. 93% ≥ 2 , $p = 0.09$). Men diagnosed with T3 disease by DRE had significantly different methods

Table 1. Baseline demographics

	T3 DRE (n=367)	T3 MRI only (n=169)	p
Age, mean (SD)	71.6 (7.7)	67.9 (6.1)	<0.001
Charlson comorbidity index, n (%)			0.09
0	0 (0)	0 (0)	
1	14 (4)	12 (7)	
≥ 2	353 (96)	157 (93)	
Ethnicity, n (%)			<0.001
Asian	17 (5)	6 (4)	
Black	4 (1)	1 (1)	
Caucasian	261 (71)	100 (59)	
Indigenous	8 (2)	2 (1)	
Hispanic	2 (1)	1 (1)	
Middle Eastern	0 (0)	1 (1)	
Other/unknown	75 (20)	58 (34)	
Family history of prostate cancer, n (%)	60 (16)	31 (18)	0.65
PSA, n (%), ng/mL			<0.001
<10	140 (38)	115 (68)	
10-20	110 (30)	36 (21)	
>20	117 (32)	18 (11)	
Gleason grade group			<0.001
1	10 (3)	43 (25)	
2	104 (28)	79 (47)	
3	111 (30)	22 (13)	
4	36 (10)	14 (8)	
5	106 (29)	11 (7)	
Initial treatment			<0.001
Active surveillance	1 (0)	28 (17)	
Radical prostatectomy	70 (19)	84 (50)	
Radiation	263 (72)	54 (32)	
Primary ADT	32 (9)	2 (1)	
Cryablation	1 (0)	1 (1)	

ADT: androgen deprivation therapy; BMI: body mass index; DRE: digital rectal exam; IQR: interquartile range; MRI: magnetic resonance imaging; PSA: prostate-specific antigen; SD: standard deviation.

of initial treatment ($p < 0.001$), with the majority undergoing radiation (72% vs. 32%), and a higher proportion undergoing primary androgen deprivation therapy (ADT) (9% vs. 1%) and an associated significantly lower number of men undergoing radical prostatectomy (19% vs 50%) and active surveillance (0% vs 17%).

A significantly higher proportion of men found to have T3 disease by DRE were found to have at least lymph node metastatic disease at the time of diagnosis (16% vs. 5%, $p < 0.001$). When analyzing only men without metastasis at diagnosis, there was no statistically significant difference in metastasis-free survival between those with cT3 disease identified by MRI and identified by DRE (hazard ratio [HR] 1.97, 95% confidence interval [CI] 0.86-4.50) (Table 2). Overall survival was significantly worse for men with clinical T3 disease

diagnosed by DRE (HR 4.6, 95% CI 1.4–15.0, $p=0.002$) and remained significant on multivariate analysis (Table 3). Figure 1 shows the Kaplan-Meier curve for overall survival between DRE and mpMRI, showing significant worse overall survival for the T3 DRE group.

DISCUSSION

This study reveals significant disparities in prostate cancer outcomes between men with T3 disease diagnosed by DRE compared to those diagnosed by mpMRI. Our findings demonstrate that patients with T3 disease identified through DRE were significantly older and had higher PSAs and higher Gleason grade group at diagnosis. They underwent radiation therapy and primary ADT at a higher rate, had higher rates of metastatic disease at diagnosis, and worse overall mortality.

A study looking at staging by MRI and DRE, though solely for localized prostate cancer, was reported by Rakauskas et al. They demonstrated a significant difference in outcomes between patients staged as T3 by DRE vs. mpMRI.⁵ In their study, patients with T3 disease on DRE had worse progression-free survival (PFS) compared to those with T3 disease on mpMRI. Their results corroborate our findings, suggesting that T3 disease identified by DRE indeed indicates worse outcomes compared to T3 disease identified by mpMRI.

Furthermore, they proposed that T3 disease by DRE should be reclassified as higher risk than T3 disease by mpMRI, a finding that our study supports. Refined classification models, such as the imaging-based risk stratification proposed by Baboudjian et al, hold promise for improving prognostic accuracy;⁷ however, prospective validation studies are essential to ascertain their clinical utility and ensure their reliable integration into patient management strategies.

Prior to any tissue diagnosis, T3 staging by DRE provides valuable predictive information for long-term outcomes in prostate cancer patients. These patients were more likely to be diagnosed with higher Gleason grade group, have metastatic disease at diagnosis, and have a worse overall mortality. The continued use of the DRE in this context is recommended for prognostication and even to drive earlier imaging or interventions based on higher clinical risk.

The treatment patterns observed in our cohort demonstrate a clear divergence. This disparity in treatment approaches may be attributed to several factors, including advanced age, discrepancy in metastasis, and perceived extent of disease in the DRE-detected cases. The higher incidence of metastasis at diagnosis in the DRE

Table 2. Cox’s proportional hazard regression analysis of metastasis

Variable	Univariate analysis		Multivariate analysis	
	HR (95% CI)	p	HR (95% CI)	p
DRE or MRI	1.97 (0.86–4.50)	0.11		
Age (years)	1.04 (0.99–1.09)	0.06		
PSA		0.11		
0–10	1.00 (reference)	1.00 (reference)		
10–20	1.76 (0.82–3.79)	0.15		
>20	2.28 (0.99–5.29)	0.05		
Family history	0.89 (0.51–1.56)	0.69		

CI: confidence interval; DRE: digital rectal exam; HR: hazard ratio; MRI: magnetic resonance imaging; PSA: prostate-specific antigen.

Table 3. Cox’s proportional hazard regression analysis of overall mortality

Variable	Univariate analysis		Multivariate analysis	
	HR (95% CI)	p	HR (95% CI)	p
DRE or MRI	4.6 (1.42–15.02)	0.002	4.04 (1.24–13.21)	0.02
Age (years)	1.01 (0.97–1.05)	0.74		
PSA		0.02		0.08
0–10	1.00 (reference)	1.00 (reference)	1.00 (reference)	1.00 (reference)
10–20	1.74 (0.84–3.62)	0.22	1.62 (0.78–3.37)	0.20
>20	2.60 (1.29–5.21)	0.007	2.20 (1.09–4.43)	0.03
Family history	0.76 (0.32–1.81)	0.54		

CI: confidence interval; DRE: digital rectal exam; HR: hazard ratio; MRI: magnetic resonance imaging; PSA: prostate-specific antigen.

group further supports the notion that DRE-detected T3 disease represents a more advanced stage of cancer.

T3 disease detected by DRE represents gross ECE, while T3 disease on MRI encompasses a spectrum from microscopic to gross ECE. We believe microscopic or early MRI-detected ECE should not be considered equivalent to palpable, gross ECE found during DRE. Several recent studies have addressed this and found that up to 1/3 of patients are upstaged with mpMRI results compared to DRE, with T3 disease being one of the primary drivers.^{8,9} Many of these patients underwent different treatments as a result of the classification from MRI staging.⁹

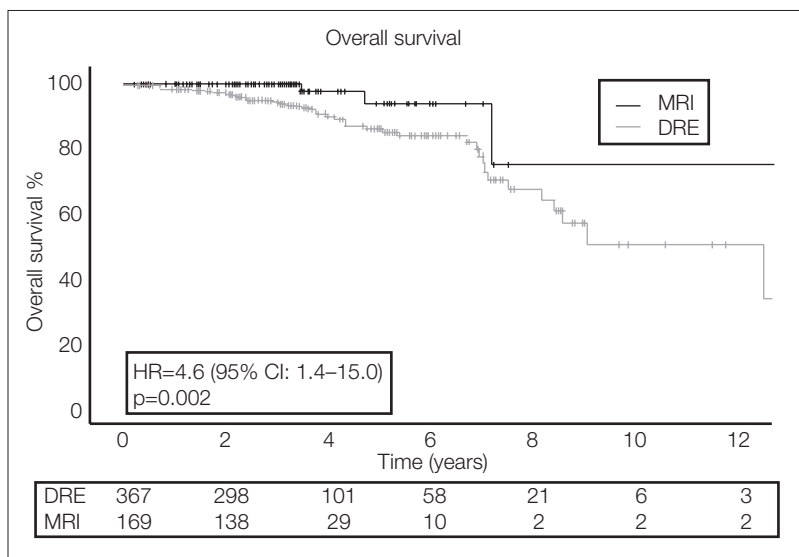


Figure 1. Kaplan-Meier curve comparing overall mortality by T3 multiparametric magnetic resonance imaging (mpMRI) (red) vs. T3 digital rectal exam (DRE) (blue). CI: confidence interval; HR: hazard ratio.

Limitations

This study has several limitations. Its retrospective nature and reliance on non-standardized diagnostic protocols introduce potential biases. The APCaRI cohort’s variability in diagnostic workups, determined by individual urologists, may reflect a cohort with lower suspicion of advanced disease. Changes in MRI technology and interpretation over time could affect staging accuracy. DRE findings are typically documented before MRI, but this cannot always be guaranteed.

Additionally, the lack of a standardized MRI protocol may contribute to selection bias. Furthermore, some patients may have been metastatic at diagnosis, which could confound results due to distinct clinical and prognostic considerations. These limitations underscore the need for prospective studies with uniform protocols to validate findings more robustly.

CONCLUSIONS

This study demonstrates that men with T3 prostate cancer diagnosed by DRE experience significantly poorer outcomes compared to those diagnosed by mpMRI, with higher rates of metastasis, mortality, and more advanced disease characteristics.

COMPETING INTERESTS: The authors do not report any competing personal or financial interests related to this work.

FUNDING: Alberta Cancer Foundation, Bird Dogs, University Hospital Foundation

REFERENCES

- Schoeffler EM, Srinivas S, Adra N, et al. NCCN guidelines version 4.2023 prostate cancer. 2023. Available at: <https://www.nccn.org/home/>
- Edn. Presented at the EAU Annual Congress Paris. EAU guidelines. April 2024. Accessed August 5, 2024. Available at: <https://uroweb.org/guidelines/prostate-cancer>
- Shish L, Zabell J. Digital rectal exam in prostate cancer screening and elevated PSA work-up — Is there a role anymore? *Curr Urol Rep* 2024;25:193-9. <https://doi.org/10.1007/s11934-024-01218-4>
- Wei JT, Barocas D, Carlsson S, et al. Early detection of prostate cancer: AUA/SUO guideline part I: Prostate cancer screening. *J Urol* 2023;210:46-53. <https://doi.org/10.1097/JU.0000000000003491>
- Rakauskas A, Peters M, Ball D, et al. The impact of local staging of prostate cancer determined on MRI or DRE at time of radical prostatectomy on progression-free survival: A Will Rogers phenomenon. *Urol Oncol* 2023;41:106.e9-16. <https://doi.org/10.1016/j.urolonc.2022.10.023>
- Vasquez C, Kolinsky M, Djebah R, et al. Cohort profile: The Alberta Prostate Cancer Research Initiative (APCaRI) Registry and Biorepository facilitates technology translation to the clinic through the use of linked, longitudinal clinical and patient-reported data and biospecimens from men in Alberta, Canada. *BMJ Open* 2020;10:e037222. <https://doi.org/10.1136/bmjopen-2020-037222>
- Baboudjian M, Gondran-Tellier B, Touzani A, et al. Magnetic resonance imaging-based T-staging to predict biochemical recurrence after radical prostatectomy: A step towards the iTNM classification. *Eur Urol Oncol* 2023;6:406-13. <https://doi.org/10.1016/j.euo.2022.09.005>
- Soeterik TFW, van Melick HHE, Dijkstra LM, et al. Multiparametric magnetic resonance imaging should be preferred over digital rectal examination for prostate cancer local staging and disease risk classification. *Urology* 2021;147:205-12. <https://doi.org/10.1016/j.urology.2020.08.089>
- Draulans C, Everaerts W, Isebaert S, et al. Impact of magnetic resonance imaging on prostate cancer staging and European Association of Urology risk classification. *Urology* 2019;130:113-9. <https://doi.org/10.1016/j.urology.2019.04.023>

CORRESPONDENCE: Dr. Adam Kinnaird, Division of Urology, Department of Surgery, University of Alberta, Edmonton, AB, Canada; ask@ualberta.ca