

**Case – Novel transurethral repair of an intraperitoneal bladder rupture**Mariah Keeling<sup>1</sup>, Geemitha Ratnayake Mudiyansele<sup>2</sup>, Yanbo Guo<sup>2</sup><sup>1</sup>Michael G. DeGroot School of Medicine, McMaster University, Hamilton, ON, Canada; <sup>2</sup>Division of Urology, Department of Surgery, McMaster University, Hamilton, ON, Canada**Cite as:** Keeling M, Mudiyansele GR, Guo Y. Case – Novel transurethral repair of an intraperitoneal bladder rupture. *Can Urol Assoc J* 2025 May 16; Epub ahead of print. <http://dx.doi.org/10.5489/cuaj.9154>

Published online May 16, 2025

**Corresponding author:** Dr. Yanbo Guo, McMaster University, St. Joseph’s Healthcare Hamilton, Hamilton, ON, Canada; [Guoy7@mcmaster.ca](mailto:Guoy7@mcmaster.ca)

\*\*\*

**INTRODUCTION**

Bladder injuries are relatively uncommon and often the result of trauma or iatrogenic injuries. While the majority are extraperitoneal, and can often be managed conservatively, intraperitoneal bladder ruptures (IBRs) account for 30% of bladder injuries.<sup>1</sup> These occur predominantly at the dome of the bladder, where full-thickness ruptures lead to urine leakage into the peritoneal cavity.<sup>2,3</sup> If untreated, this can progress to peritonitis and potentially fatal complications.

While IBRs are mainly associated with blunt force trauma to a distended bladder, spontaneous IBRs may also occur. Contributing factors include bladder outlet obstruction, overdistention and inflammation, or more uncommonly malignancy.<sup>1,4,5</sup> Spontaneous IBRs are rare, with an incidence of 1 per 126 000 individuals.<sup>6</sup>

Standard of care for IBR is operative repair, done either laparoscopically or open. In select cases involving small injuries from endoscopic surgery or patients with significant comorbidities, conservative management can be attempted.<sup>3</sup> Transurethral suturing techniques have previously been described to in the closure of vesicovaginal fistulas.<sup>7</sup> To our knowledge, this is the first report of a transurethral repair of a cystographically confirmed IBR.

**KEY MESSAGES**

- This case demonstrates successful closure of a recurrent IBR using a novel transurethral repair
- This technique decreased procedural time and avoids invasive abdominal surgery
- Transurethral repair potentially represents an alternative option to laparoscopic repair of IBRs in select cases

**CASE REPORT**

A 47-year-old female presented to the emergency department (ED) with complaints of abdominal pain and dysuria. Her medical history is significant for a kidney transplant 21 years ago, which was followed by another operation two months later for suspected lymphocele exploration. Although no lymphocele was found, the procedure was complicated by an iatrogenic injury to the bladder dome, which was repaired intraoperatively.

Since then, she experienced recurrent spontaneous bladder ruptures, occurring 3 years and 12 years after the initial injury. During both episodes, she expressed reluctance to undergo surgical repair. As per her preference, these ruptures were successfully managed conservatively with Foley catheterization for four weeks.

Her transplant has continued to function well and she has remained on routine maintenance immunosuppression with prednisone, tacrolimus and mycophenolate. Her medical history also was notable for recurrent deep vein thrombosis (DVT), IgA nephropathy, and hypertension.

She then again presented to the ED with abdominal pain similar to her last rupture. A CT cystogram revealed an intraperitoneal bladder rupture at the dome of the bladder, similar to her previous ruptures. She initially requested discharge with a foley catheter in similar fashion to her previous IBRs. Over the next month, she continued to re-present to the emergency department with ongoing abdominal pain but was still not interested in surgical management. 25 days after her initial ED visit, she again returned to the ED with abdominal pain. At this point, we had a frank discussion regarding her persistent, symptomatic, and recurrent bladder rupture. Although we initially recommended a laparoscopic repair, she remained very reluctant to proceed with any intra-abdominal surgery. We discussed the possibility of a transurethral repair and she was willing to undergo this.

Urine cultures were drawn pre-operatively and were positive for *pseudomonas putida* and *elizabethkingia meningoseptica*. The infectious disease service was involved and started her on vancomycin and ciprofloxacin.

Under general anesthetic, the urethra was entered with a 22 French rigid cystoscope. A patent transplant ureteric orifice was appreciated. The visible defect was noted in the right dome, correlating with the site seen on cystogram (Figure 1 & Figure 2A).

A 3-0 V-Loc™ suture was placed using a laparoscopic needle driver through the sheath of the rigid cystoscope. Once the entire suture was fed through the sheath and atraumatically placed in the bladder, the 22 French sheath was removed. The cystoscopy camera itself (4mm or 12 French) was then placed into the bladder to ensure adequate visualization. A laparoscopic needle driver (5mm or 15 French) was placed through the urethra, alongside the cystoscopy camera (Figure 2B). The defect was then closed using a running suture. Given that V-Loc™ is a barbed suture, we did not suture the distal end of the closure and allowed the barbs to keep the closure tight. The driver was then removed and a 22 French cystoscope with the irrigation sheath was then placed to confirm closure of the defect and hemostasis. Finally, rigid biopsy forceps

were used to cut the tail of the suture and remove the needle through the cystoscope sheath. A foley was then replaced with continuous bladder irrigation.

The patient recovered nicely from surgery. Postoperatively, she finished her course of ciprofloxacin and was switched to minocycline for discharge for a total course of seven days. Postoperative urine cultures were negative. She was discharged on postoperative day three. Cystogram on postoperative day 17 (Figure 3) confirmed good healing and the patient is doing well and her creatinine remains at baseline.

## DISCUSSION

Standard of care for repair of intraperitoneal bladder ruptures per the AUA guidelines is in an open fashion with laparotomy.<sup>3</sup> While the gold standard, this presents many surgical risks, especially among comorbid patients. A laparoscopic approach compared to open surgery reduces operative time, costs, postoperative pain, and major complications, however it is also not complication free. The only recorded instance of a transurethral bladder rupture repair was in 1998, following an inadvertent cystotomy from an endoscopic procedure. Here we demonstrate a case of a 47-year-old female who had bladder injury initially during an exploration after transplant for possible lymphocele, that was repaired and over the next 21 years had recurrent spontaneous IBRs at the site of initial injury. Both subsequent ruptures were treated nonoperatively with foley catheterization per the patient request. Unfortunately, she re-presented this third time with an IBR that was cystographically confirmed. Given its persistent and recurrent nature, we strongly recommended surgical closure. However, given the patient's reluctance for any intra-abdominal, open or laparoscopic surgery, we attempted a minimally invasive natural orifice transurethral approach. To our knowledge, this is the first description of a cystographically confirmed IBR to be repaired in this manner. This technique involved a short operative time, could theoretically be done without a general anesthetic, and avoids entry into the abdomen which is of great value in a highly comorbid patient.

This patient represents a unique case given her strong request for avoiding intra-abdominal treatment options. We routinely would consider laparoscopic repair in patients who are comorbid or would prefer to avoid a laparotomy. Additionally, this technique is highly dependent on the location of the perforation. An anteriorly located rupture would be much more challenging to repair in this way. Finally, this technique would not be possible in male patients.

## CONCLUSIONS

To our knowledge this is the first instance of a transurethral repair of a cystographically confirmed IBR. This suggests further exploration of this technique is warranted, especially given the instruments and skills required are well within standard urological care. This is an especially useful technique in the comorbid patient who would prefer to avoid a larger operation.

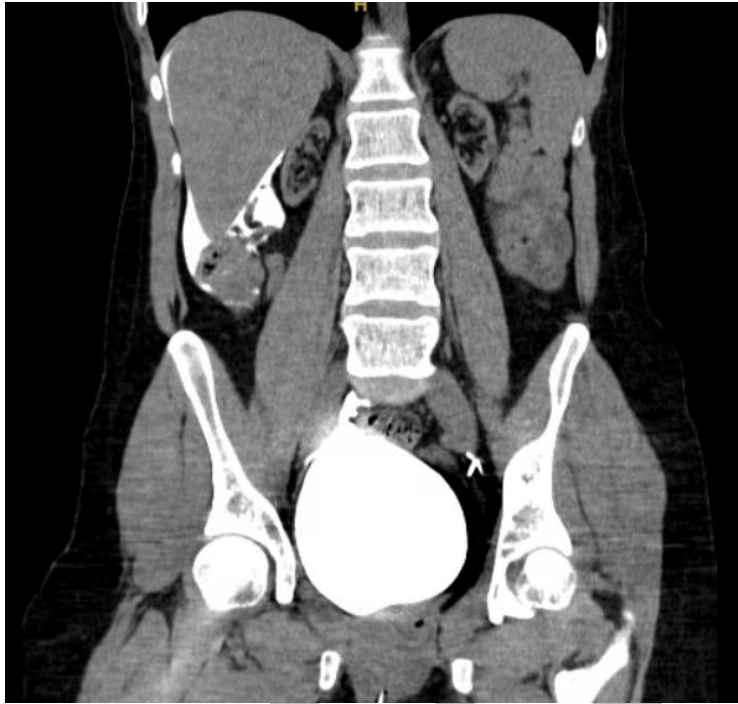
## REFERENCES

1. Matlock KA, Tyroch AH, Kronfol ZN, et al. Blunt traumatic bladder rupture: A 10-year perspective. *Am Surg* 2013;79:589-93. <https://doi.org/10.1177/000313481307900619>
2. Elkbuli A, Ehrhardt JD, Hai S, et al. Management of blunt intraperitoneal bladder rupture: Case report and literature review. *Int J Surg Case Rep* 2019;55:160-3. <https://doi.org/10.1016/j.ijscr.2019.01.038>
3. Morey AF, Brandes S, Dugi DD, et al. Urotrauma: AUA guideline. *J Urol* 2014;192:327-35. <https://doi.org/10.1016/j.juro.2014.05.004>
4. Gomez RG, Ceballos L, Coburn M, et al. Consensus statement on bladder injuries. *BJU Int* 2004;94:27-32. <https://doi.org/10.1111/j.1464-410X.2004.04896.x>
5. Da Huang J, Shao EX, Tham CM, et al. Bladder malignancy as a cause of spontaneous bladder rupture: A systematic review. *BJUI Compass* 2024;5:12-6. <https://doi.org/10.1002/bco2.281>
6. Kurniawan D, Pramod SV. Spontaneous intraperitoneal bladder rupture managed conservatively. *Urol Case Rep* 2022;45:102220. <https://doi.org/10.1016/j.eucr.2022.102220>
7. Duque-Galán M, Hidalgo-Cardona A, López-Girón MC, et al. Natural orifice transluminal endoscopic surgery for correction of vesicovaginal fistulas after hysterectomy due to morbidly adherent placenta. *J Obstet Gynaecol Can* 2021;43:237-41. <https://doi.org/10.1016/j.jogc.2020.06.029>

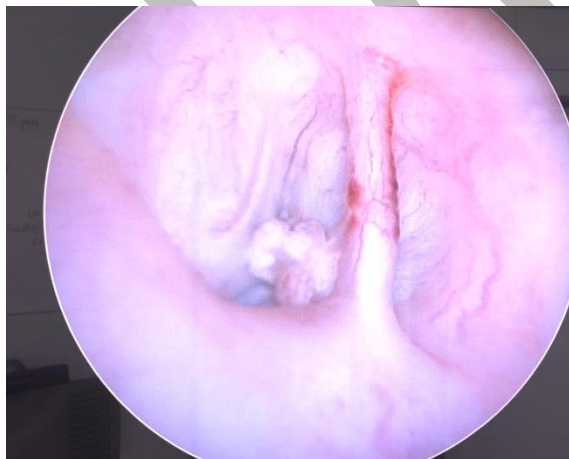DRAFT

## FIGURES AND TABLES.

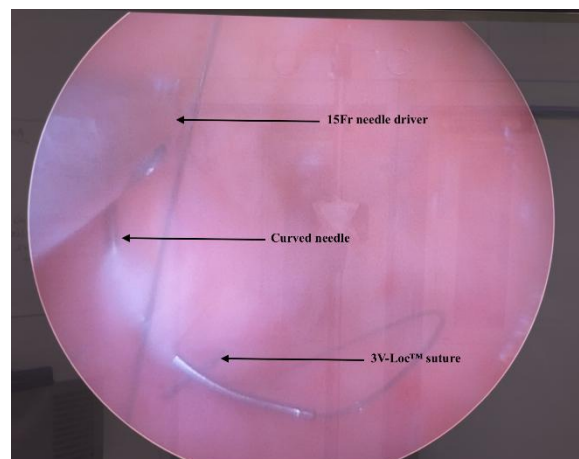
**Figure 1.** Computed tomography cystogram on initial presentation demonstrating intraperitoneal bladder ruptures (IBR) with contrast seen around the liver.



**Figure 2.** Transurethral repair of the intraperitoneal bladder ruptures (IBR). (A) demonstrates the identification of the injury via cystoscope. The 3-0 V-Loc™ suture was placed as seen in (B) continuing in a running fashion for 3 bites. This resulted in complete closure of the IBR.

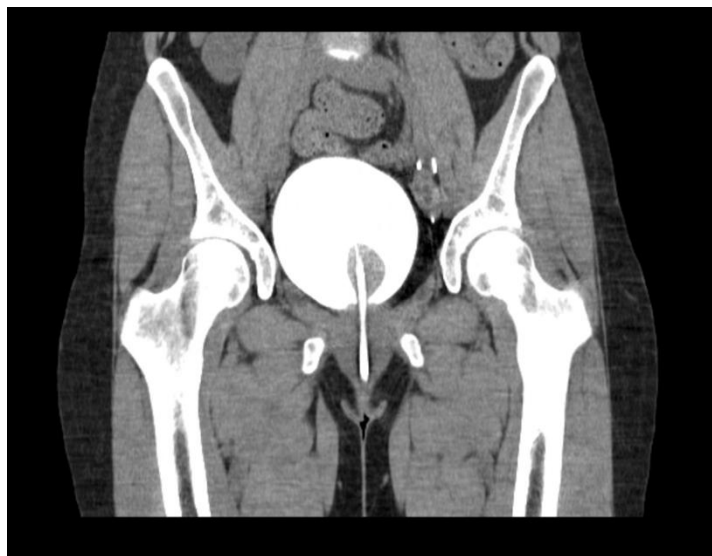


A.



B.

**Figure 3.** Computed tomography cystogram from postoperative day 17, seen in an outpatient setting, confirming successful closure of the previously identified intraperitoneal bladder ruptures on the right dome.



DRAFT