

## Association of surgical margin positivity with preoperative mpMRI-identified index lesions in radical prostatectomy

### A retrospective study

Ahmet Halis<sup>1</sup>, Mucahit Gelmis<sup>2</sup>, Ufuk Caglar<sup>1</sup>, Ibrahim Hacibey<sup>3</sup>, Sami Sekkeli<sup>1</sup>, Huseyin Burak Yazılı<sup>1</sup>, Ali Ayranci<sup>1</sup>, Faruk Ozgor<sup>1</sup>

<sup>1</sup>Department of Urology, Haseki Training and Research Hospital, Istanbul, Turkey; <sup>2</sup>Department of Urology, Gaziosmanpasa Training and Research Hospital, Istanbul, Turkey; <sup>3</sup>Department of Urology, Bagcilar Training and Research Hospital, Istanbul, Turkey

Cite as: Halis A, Gelmis M, Caglar U, et al. Association of surgical margin positivity with preoperative mpMRI-identified index lesions in radical prostatectomy: A retrospective study. *Can Urol Assoc J* 2025;19(9):E312-6. <http://dx.doi.org/10.5489/cuaj.9103>

Published online May 16, 2025

### ABSTRACT

**INTRODUCTION:** Prostate cancer remains the second most common malignancy in men worldwide. Positive surgical margins (PSMs) following radical prostatectomy are associated with an increased risk of biochemical recurrence. This study investigated the relationship between preoperative multiparametric magnetic resonance imaging (mpMRI)-detected index lesions and PSMs, aiming to assess whether specific lesion locations correlate with margin involvement.

**METHODS:** A retrospective cohort study was conducted at Health Sciences University Haseki Training and Research Hospital, analyzing 148 patients who underwent radical prostatectomy between 2017 and 2023. Patients were stratified based on surgical margin status, with comparisons made between mpMRI features, pathologic outcomes, and the anatomical distribution of PSMs. Binary logistic regression was used to identify independent predictors of PSMs.

**RESULTS:** Of the 148 patients, 49 had PSMs. Higher preoperative prostate-specific antigen levels, prostate-specific antigen density, and Prostate Imaging-Reporting and Data System (PI-RADS) scores were significantly associated with PSMs. Multivariate analysis revealed that PI-RADS 5, International Society of Urological Pathology grade 4 or above, and extraprostatic extension were independent predictors of PSMs. Although lesions in the apical and posterior regions showed higher rates of PSMs, the regional differences were not statistically significant.

**CONCLUSIONS:** Our findings suggest that mpMRI plays a critical role in preoperative risk stratification and may guide surgical planning to reduce PSMs; however, further prospective studies are needed to validate these results and explore the potential benefits of targeted resections in high-risk regions for improving oncologic outcomes.

### INTRODUCTION

Prostate cancer ranks as the second most prevalent malignancy among men worldwide, following lung cancer. Annually, over one million new cases are diagnosed, with the disease accounting for more than 300 000 deaths, representing approximately 3.8% of all cancer-related mortality in men. The median age at diagnosis is around 65 years, and mortality rates rise substantially with advancing age.<sup>1</sup>

The diagnostic workup for prostate cancer typically begins with elevated serum prostate-specific antigen (PSA) levels, accompanied by abnormal findings on digital rectal examination (DRE). A definitive diagnosis is established through histopathologic analysis of tissue samples obtained via systematic transrectal ultrasound-guided prostate biopsies. These biopsies not only confirm malignancy but also provide crucial insights into Gleason grading, which, alongside PSA levels and DRE findings, are integrated into nomograms to inform clinical decision-making and prognostic evaluations.<sup>2</sup>

The standard transrectal ultrasound-guided prostate biopsy approach involves retrieving 12 systematic, random Tru-Cut cores;<sup>3</sup> however, due to the inherent sampling limitations, there is a risk of missing clinically significant cancer, leading to recent updates in clinical guidelines. The European Association of Urology (EAU) now advocates for the use of multiparametric magnetic resonance imaging (mpMRI) prior to biopsy, particularly in individuals with elevated PSA levels. Multiparametric

MRI facilitates targeted biopsies of suspicious regions, demonstrating superior detection rates for clinically significant prostate cancer compared with traditional systematic biopsies.<sup>4</sup> Despite its diagnostic advantages, mpMRI-targeted biopsy is not without limitations, such as the potential for undersampling, false-negative findings, and inter-institutional variability in mpMRI interpretation, which may reduce sensitivity, particularly for smaller or multifocal tumors.<sup>5</sup>

Multiparametric MRI has now become a pivotal tool in both the detection and staging of prostate cancer. Numerous studies highlight its high sensitivity for identifying suspicious lesions, and MRI-targeted biopsies are shown to more accurately predict Gleason scores compared with systematic biopsies, especially when correlated with radical prostatectomy outcomes.<sup>6,7</sup> Beyond lesion detection, mpMRI provides essential staging information and is currently considered the most accurate imaging modality for assessing extraprostatic extension and determining the tumor's T-stage, with the EAU guideline supporting its use for local staging prior to biopsy.<sup>8,9</sup>

In this study, we aimed to compare the index lesion locations identified on preoperative mpMRI with the anatomical sites of positive surgical margins (PSMs) in patients who underwent radical prostatectomy for prostate cancer and were found to have positive margins on final pathologic analysis.

## METHODS

This retrospective cohort study was conducted at the Health Sciences University Haseki Training and Research Hospital, Urology Clinic, with ethical approval (No. 220-2023, dated 06/12/2023). Patients included in the study were diagnosed with prostate cancer via MRI/ultrasound fusion-guided biopsy between January 2017 and July 2023 and subsequently underwent radical prostatectomy. Data were systematically extracted from the hospital's electronic medical records.

A total of 148 patients were eligible for inclusion, of whom 99 had negative surgical margins and 49 had PSMs following radical prostatectomy. Patients who were under active surveillance, diagnosed through transrectal ultrasound-guided biopsy, or had incomplete records were excluded from the analysis.

The collected data comprised demographic information (age, body mass index, comorbidities), preoperative PSA levels, and mpMRI findings, including lesion size, lesion location, and Prostate Imaging-Reporting and Data System (PI-RADS) v2 score. Additionally, pathologic results were evaluated, including Gleason scores,

pathologic staging (tumor, nodes, and metastasis classification), and surgical margin status.

Patients were divided into two groups based on surgical margin status: those with PSMs (SM+) and those with negative surgical margins (SM-). Comparisons between these groups were made regarding demographic characteristics, mpMRI features, and histopathologic outcomes. Particular attention was given to assessing the relationship between the index lesion location and the region of PSMs. Additionally, potential risk factors predicting PSMs were explored.

## Statistical analysis

All statistical analyses were conducted using IBM SPSS Statistics for Windows, Version 27.0 (IBM Corp., Armonk, NY, U.S.). The normality of data distribution was determined using the Kolmogorov-Smirnov test. Continuous variables were expressed as mean  $\pm$  standard deviation for normally distributed data and as median (interquartile range) for non-normally distributed data. For normally distributed continuous variables, the independent samples t-test was used, and the Mann-Whitney U test was employed for non-normally distributed variables. Categorical variables were compared using the Chi-squared test or Fisher's exact test, as appropriate. Binary logistic regression analysis was performed to identify independent factors associated with PSMs. We included the variables that were statistically significant in the univariate analysis in the multivariate analysis. A  $p < 0.05$  was considered statistically significant.

## RESULTS

In this study, the average age of the patients was  $61.7 \pm 6.3$  years, with a mean body mass index of  $27.1 \pm 3.5$  kg/m<sup>2</sup>. The most common comorbidities included hypertension (33.8%), diabetes mellitus (18.9%), coronary artery disease (10.1%), and chronic obstructive pulmonary disease (10.8%). The mean PSA level was 8.2 ng/ml, and the mean prostate volume was 43.5 cc, yielding an average PSA density of 0.19. Suspicious findings on DRE were noted in 15.5% of the cases. Patients with SM+ demonstrated significantly higher PSA levels ( $p = 0.022$ ) and PSA density ( $p = 0.021$ ) than those with SM-. Although prostate volume did not differ significantly between groups ( $p = 0.191$ ), suspicious findings on DRE were more frequent in the SM+ group ( $p = 0.009$ ) (Table 1).

The relationship between International Society of Urological Pathology (ISUP) grades and the presence of PSMs was evaluated. A statistically significant associa-

tion was found between increasing ISUP grade and the incidence of PSMs ( $p=0.035$ ). Specifically, patients with higher ISUP grades were more likely to have positive margins. For example, the rate of PSMs was around 10% in ISUP 1, whereas it increased to approximately 40% in ISUP 5. This trend suggests that higher ISUP grades are strongly correlated with the presence of PSMs (Figure 1).

Although seminal vesicle invasion was more common in the SM+ group (14.3% vs. 8.1%), this difference was not statistically significant ( $p=0.239$ ); however, extraprostatic extension was significantly more frequent in the SM+ group ( $p=0.007$ ) (Table 2).

Lesion location analysis revealed regional variability in surgical margin involvement. Lesions in the apical and posterior regions showed higher rates of margin

involvement, although the differences were not statistically significant ( $p=0.690$  and  $p=0.578$ , respectively).

Similarly, analysis of PI-RADS scores demonstrated a statistically significant association with positive surgical margin (PSM) incidence ( $p=0.017$ ). As shown in Figure 2, the rate of PSMs increased progressively with higher PI-RADS scores, from 23.8% in PI-RADS 3 to 51.3% in PI-RADS 5.

Multivariate analysis identified PI-RADS score 5 ( $p=0.037$ ), final pathology ISUP grade 4 and above ( $p=0.007$ ), and extraprostatic extension ( $p=0.021$ ) as independent predictors of PSMs (Table 3).

## DISCUSSION

The presence of PSMs following radical prostatectomy remains a critical prognostic factor in prostate cancer, particularly concerning biochemical recurrence.<sup>10</sup> In this study, we aimed to explore the relationship between preoperative mpMRI findings, specifically the index lesion location, and PSMs. Our results indicated that although patients with PSMs demonstrated higher PSA levels, PSA density, and PI-RADS scores, the correlation between lesion location and margin involvement showed regional variability. Notably, lesions in the apical and posterior regions exhibited higher rates of margin involvement; however, these differences were not statistically significant ( $p=0.690$  and  $p=0.578$ , respectively). Despite the lack of statistical significance, the observed trends suggest that preoperative mpMRI may still provide valuable guidance for targeted surgical strategies, potentially improving oncologic outcomes by reducing PSM rates, particularly in high-risk regions.

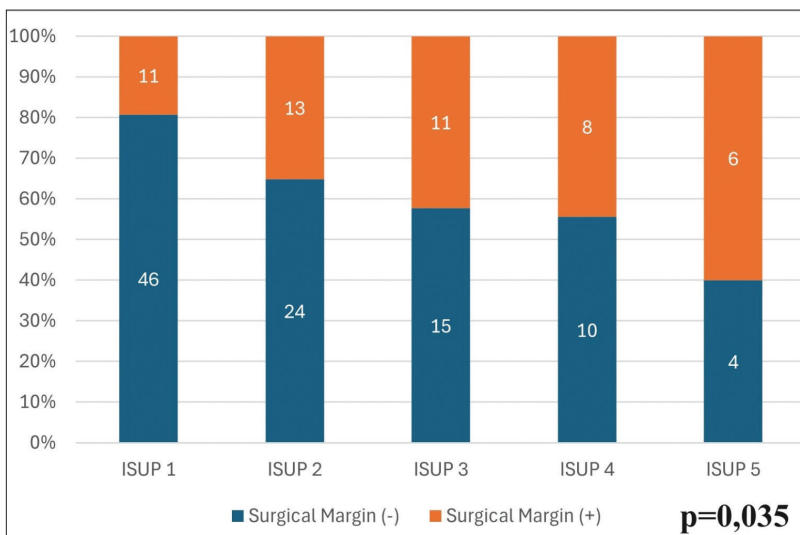
Quentin et al identified higher PSA levels and PSA density as significant predictors of PSMs, findings that align closely with our results;<sup>11</sup> however, a notable divergence between our study and that of Quentin et al lies in the relationship between the ISUP grade at biopsy and PSMs. Although Quentin et al did not report a significant difference in ISUP grade at biopsy between patients with and without PSMs, our study revealed a clear association in this respect. Despite this difference, both studies demonstrated significant variations in ISUP grades following radical prostatectomy, underscoring the prognostic relevance of final pathology in assessing tumor aggressiveness and predicting surgical outcomes.

Furthermore, both analyses identified a strong correlation between PSMs and extraprostatic extension, emphasizing the critical need for accurate preoperative identification of extraprostatic extension to enhance surgical planning and improve clinical management.<sup>11</sup>

**Table 1. Clinical characteristics of patients**

Variable	Overall (n=148)	SM (-) (n=98)	SM (+) (n=50)	p
Age (years)*	61.7 ± 6.3	61.6±6.1	61.9±6.7	0.724
BMI (kg/m <sup>2</sup> )*	27.1 ± 3.5	27.0±3.4	27.3±3.7	0.780
PSA (ng/ml)**	8.2 (5.8–13.0)	7.6±2.1	9.4±2.7	<b>0.022</b>
Prostate volume (cc)**	43.5 (33.0–62.0)	42.0±9.5	45.2±10.1	0.191
PSA density**	0.19 (0.12–0.30)	0.1±0.05	0.23±0.07	<b>0.021</b>
Suspicious DRE (%)	15.5	9.2	25.6	<b>0.009</b>

\*Mean ± standard deviation. \*\*Median (interquartile range). Bolded values indicate statistical significance. SM (-): negative surgical margins; SM (+): positive surgical margins; BMI: body mass index; DRE: digital rectal examination; PSA: prostate-specific antigen.



**Figure 1.** The distribution of positive and negative surgical margins across different International Society of Urological Pathology (ISUP) grades ( $p=0.035$ ).

**Table 2. Association between surgical margins and pathological features**

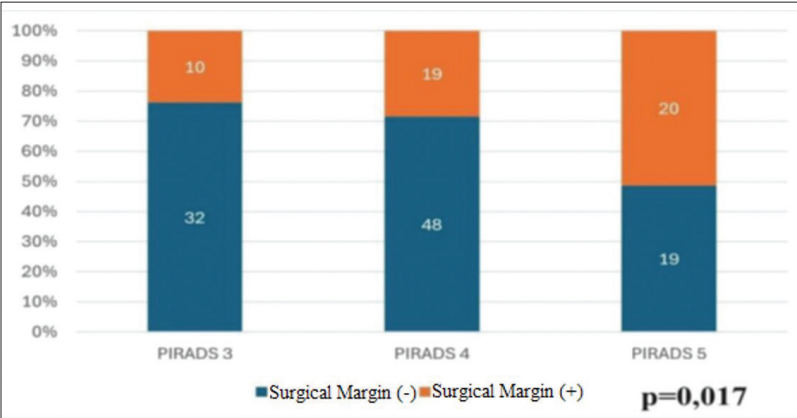
Feature	SM (-) (n=98)	SM (+) (n=50)	p
Extraprostatic extension (%)	21.4	42.9	<b>0.007</b>
Seminal vesicle invasion (%)	8.1	14.3	0.239

Bolded value indicates statistical significance. Similarly, analysis of Prostate Imaging-Reporting and Data System (PI-RADS) scores demonstrated a statistically significant association with positive surgical margin (PSM) incidence (p=0.017). As shown in Figure 2, the rate of PSMs increased progressively with higher PI-RADS scores, from 23.8% in PI-RADS 3 to 51.3% in PI-RADS 5 (Figure 2). SM (-): negative surgical margins; SM (+): positive surgical margins.

**Table 3. Multivariate analysis of predictors for positive surgical margins**

Variable	OR	95% CI	p
PSA	0.971	0.911–1.035	0.195
PSA density	3.751	0.369–7.627	0.306
PI-RADS score 5	2.721	1.042–7.070	<b>0.037</b>
Suspicious DRE	2.272	0.765–6.746	0.150
ISUP grade ≥4 (biopsy)	2.004	0.740–5.398	0.167
ISUP grade ≥4 (final pathology)	4.756	1.580–14.307	<b>0.007</b>
Extraprostatic extension	3.315	1.192–9.225	<b>0.021</b>

Bolded values indicate statistical significance. CI: confidence interval; DRE: digital rectal examination; ISUP: International Society of Urological Pathology; OR: odds ratio; PSA: prostate-specific antigen; PI-RADS: Prostate Imaging-Reporting and Data System.



**Figure 2.** Association between Prostate Imaging-Reporting and Data System (PI-RADS) scores and positive surgical margins (p=0.017).

Similarly, Alessi et al investigated mpMRI features predictive of PSMs and reported significant differences in PSA density and PI-RADS scores between positive and negative surgical margin groups, aligning with our findings;<sup>13</sup> however, unlike our study, they did not observe a significant difference in ISUP grades between these groups, potentially attributable to variations in patient populations or surgical techniques. This discrepancy underscores the need for further research to fully elucidate the relationship between ISUP grading and PSMs. Nevertheless, both studies emphasize the pivotal role of mpMRI in preoperative planning, particularly in identifying patients at elevated risk for PSMs.<sup>13</sup>

Our study further examined the anatomical distribution of PSMs, revealing that the posterior apex and mid-gland were the most frequently involved regions, whereas the anterior prostate and base showed fewer positive margins. These observations are consistent with previous research, which indicates that posterior regions, particularly the apex, are more prone to PSMs due to their complex anatomy and proximity to critical structures.<sup>14,15</sup> Although the differences in PSM rates across regions were not statistically significant in our cohort, these findings underscore the need for heightened surgical precision in anatomically challenging areas.

**Limitations**

Although our study offers valuable insights into the relationship between preoperative mpMRI findings and PSMs, several limitations warrant consideration.

The retrospective design of our study may introduce selection bias, and the relatively small sample size may restrict the generalizability of our results. Furthermore, although we identified a significant correlation between the index lesion location and PSMs, our study did not investigate whether targeted resection of these areas

These findings collectively underscore the importance of rigorous preoperative evaluation in optimizing surgical outcomes for prostate cancer patients.

The predictive value of mpMRI, particularly PI-RADS scores, in preoperative risk stratification is well-established. Sciarra et al demonstrated that higher PI-RADS scores were significantly associated with an increased risk of PSMs, consistent with our findings.<sup>12</sup> In our cohort, patients with higher PI-RADS scores were more likely to present with PSMs, reinforcing the role of mpMRI in guiding surgical decision-making. Additionally, both our study and that of Sciarra et al found that extraprostatic extension was significantly more prevalent among patients with PSMs, suggesting that mpMRI not only aids in tumor localization but also provides critical insights into the extent of disease, thereby assisting in the identification of patients at increased risk for PSMs.<sup>12</sup>

would result in reduced PSM rates. Also, the potential impact of lesion size on PSMs was not evaluated in this study.

Prospective, multicenter studies with larger patient cohorts are necessary to validate our findings and assess the potential benefits of more aggressive resection at the index lesion site for reducing PSMs and enhancing long-term oncologic outcomes.

## CONCLUSIONS

Our study identifies a correlation between the preoperative mpMRI-detected index lesion and PSMs following radical prostatectomy, despite the lack of statistically significant regional variability in margin involvement. These findings underscore the potential of mpMRI in preoperative planning and risk stratification. Nonetheless, the retrospective design, small sample size, and non-significant regional differences warrant further prospective research to validate these observations and explore the efficacy of mpMRI-guided surgical approaches in enhancing oncologic outcomes.

COMPETING INTERESTS: The authors do not report any competing personal or financial interests related to this work.

## REFERENCES

1. Ferlay J, Soerjomataram I, Dikshit R, et al. Cancer incidence and mortality worldwide: Sources, methods and major patterns in GLOBOCAN 2012. *Int J Cancer* 2015;136:E359-86. <https://doi.org/10.1002/ijc.29210>
2. Heidenreich A, Abrahamsson PA, Artibani W, et al. Early detection of prostate cancer: European Association of Urology recommendation. *Eur Urol* 2013;64:347-54. <https://doi.org/10.1016/j.eururo.2013.06.051>
3. Hodge KK, McNeal JE, Terris MK, et al. Random systematic versus directed ultrasound guided transrectal core biopsies of the prostate. *J Urol* 1989;142:71-5. [https://doi.org/10.1016/s0022-5347\(17\)38664-0](https://doi.org/10.1016/s0022-5347(17)38664-0)
4. Ahmed HU, Bosaily AES, Brown LC, et al. Diagnostic accuracy of multi-parametric MRI and TRUS biopsy in prostate cancer (PROMIS): A paired validating confirmatory study. *Lancet* 2017;389:815-22.
5. Puech P, Rouvière O, Renard-Penna R, et al. Prostate cancer diagnosis: Multiparametric MR-targeted biopsy with cognitive and transrectal US-MR fusion guidance versus systematic biopsy—prospective multicenter study. *Radiology* 2013;268:461-9.
6. Kasivisvanathan V, Rannikko AS, Borghi M, et al. MRI-targeted or standard biopsy for prostate-cancer diagnosis. *N Engl J Med* 2018;378:1767-77. <https://doi.org/10.1056/NEJMoa1801993>
7. Moore CM, Robertson NL, Arsanian N, et al. Image-guided prostate biopsy using magnetic resonance imaging-derived targets: A systematic review. *Eur Urol* 2013;63:125-40. <https://doi.org/10.1016/j.eururo.2012.06.004>
8. Barentsz JO, Weinreb JC, Verma S, et al. Synopsis of the PI-RADS v2 guidelines for multiparametric prostate magnetic resonance imaging and recommendations for use. *Eur Urol* 2016;69:41-9. <https://doi.org/10.1016/j.eururo.2015.08.038>
9. Mattet N, van den Bergh RCN, Briers E, et al. EAU-EANM-ESTRO-ESUR-SIOG guidelines on prostate cancer—2020 update. Part 1: Screening, diagnosis, and local treatment with curative intent. *Eur Urol* 2021;79:243-62. <https://doi.org/10.1016/j.eururo.2020.09.042>
10. Cho KS, Hong SJ, Chung BH. The impact of positive surgical margins on biochemical recurrence after radical retropubic prostatectomy. *Korean J Urol* 2004;416-22.
11. Quentin M, Schimmöller L, Ullrich T, et al. Pre-operative magnetic resonance imaging can predict prostate cancer with risk for positive surgical margins. *Abdom Radiol (NY)* 2022;47:2486-93. <https://doi.org/10.1007/s00261-022-03543-z>
12. Sciarra A, Frisenda M, Maggi M, et al. Prospective comparative trial on nerve-sparing radical prostatectomy using a robot-assisted versus laparoscopic technique: Expectation vs. satisfaction and impact on surgical margins. *Cent Eur J Urol* 2021;74:169-77. <https://doi.org/10.5173/cej.2021.0017.R3>
13. Alessi S, Maggioni R, Luzzago S, et al. Apparent diffusion coefficient and other preoperative magnetic resonance imaging features for the prediction of positive surgical margins in prostate cancer patients undergoing radical prostatectomy. *Clin Genitourin Cancer* 2021;19:e335-45. <https://doi.org/10.1016/j.clgc.2021.04.004>
14. Salomon L, Anastasiadis AG, Levrel O, et al. Location of positive surgical margins after retropubic, perineal, and laparoscopic radical prostatectomy for organ-confined prostate cancer. *Urology* 2003;61:386-90. [https://doi.org/10.1016/s0090-4295\(02\)02255-0](https://doi.org/10.1016/s0090-4295(02)02255-0)
15. Wieder JA, Soloway MS. Incidence, etiology, location, prevention and treatment of positive surgical margins after radical prostatectomy for prostate cancer. *J Urol* 1998;160:299-315. [https://doi.org/10.1016/S0022-5347\(01\)62881-7](https://doi.org/10.1016/S0022-5347(01)62881-7)

CORRESPONDENCE: Dr. Ahmet Halis, Department of Urology, Haseki Training and Research Hospital, Istanbul, Turkey; drahmethls@gmail.com