

Case – Emergent management of severe penile and scrotal edema due to prolonged metallic ring entrapment

Mohamad Baker Berjaoui¹, David-Dan Nguyen¹, Zizo Al-Daqqaq², Justin Y. H. Chan¹, Yonah Krakowsky^{1,3}

¹Division of Urology, Department of Surgery, University of Toronto, Toronto, ON, Canada; ²Temerty Faculty of Medicine, University of Toronto, Toronto, ON, Canada; ³Division of Urology, Department of Surgery, Women's College Hospital and Mount Sinai Hospital, Toronto, ON, Canada

Cite as: Berjaoui MB, Nguyen DD, Al-Daqqaq Z, et al. Case – Emergent management of severe penile and scrotal edema due to prolonged metallic ring entrapment. *Can Urol Assoc J* 2025;19(3):E119-21. <http://dx.doi.org/10.5489/auaj.8874>

Published online November 4, 2024

INTRODUCTION

Penile constriction, historically used for enhancing sexual pleasure, has been documented since 1755. The practice involves constricting blood outflow from the penis, prolonging erections.¹⁻⁴ Penile entrapment can lead to varying degrees of vascular obstruction, ranging from mild, edematous cases to severe gangrene. Materials, such as rubber bands, wedding rings, hammerheads, bullrings, and plastic bottlenecks, have been employed,^{4,5} with application advised not to exceed 30 minutes.⁶ Prolonged constriction can result in severe ischemia and edema, potentially leading to necrosis and self-amputation. Urgent intervention is vital, and different treatment options have been elaborated. This article presents a recent case and reviews management options.

CASE REPORT

A 40-year-old male with previously known erectile dysfunction presented with severe penile and scrotal edema due to entrapment by a metallic penile ring. The patient had the penile ring applied and forgot to remove it before going to sleep. When he awoke, he had significant penile and scrotal edema that prevented the removal of the penile ring. The patient delayed seeking medical attention due to embarrassment. Twenty-four hours after penile entrapment, he began to experience significant pain and presented to the emergency department after 48 hours when the pain progressed and became intolerable.

The emergency department consulted with urology. On our assessment, the patient had significant penile and scrotal edema, with no ecchymosis or

surface necrosis to the penis or the scrotum. The metallic penile ring was found to be entrapping both the scrotum and the penis (Figures 1, 2). An initial attempt at manually decompressing the edema failed. Another attempt to manually decompress the scrotal and penile edema was performed under sedation. The penile edema responded relatively well to manual decompression, but the scrotal edema persisted without significant change. At that point, both the orthopedic team and maintenance department were called for assistance but were not able to aid with useful tools to remove the entrapped ring due to the significant edema preventing the passage of any of the available tools between the scrotal skin and penile ring.

Ultimately, the firefighting department was called into the emergency department. Following thorough deliberation between our medical team and the firefighters, a decision was made to employ an electrical grinder metal cutter for the extraction procedure. Plastic cards and a tongue depressor were passed under the penile ring to shield the skin from potential electric sparks and heat (Figures 3, 4). Manual irrigation with water was consistently applied throughout the procedure to facilitate the cooling down of the metals. An infrared thermometer was used to monitor and ensure the temperature remained at or below body temperature (Figure 5).

DISCUSSION

Penile ring entrapment, a rare urologic emergency, poses risks of edema, strangulation, ischemia, gangrene, and urethral injury, especially when applied for longer than 30 minutes.^{7,8} Cases often result from attempts at sexual enhancement or self-treatment of erectile dysfunction. Delayed medical attention due to embarrassment is common.

In our case, the patient presented 48 hours after the penile ring was inserted. He presented with edema and there was no evidence of skin ulceration or urethral injury, which makes it a grade I injury according to the Bhat penile strangulation classification system (Table 1).⁹

Healthcare professionals may select diverse approaches contingent upon the composition of the penile ring, severity of injury, and duration of entrapment. Previous case reports have outlined favorable outcomes achieved through compression, lubrication, and the implementation of fasciotomies, either individu-

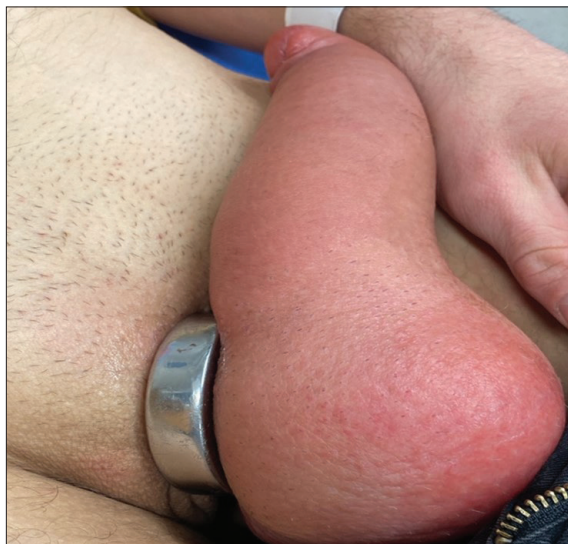

Figure 1. Patient presentation.

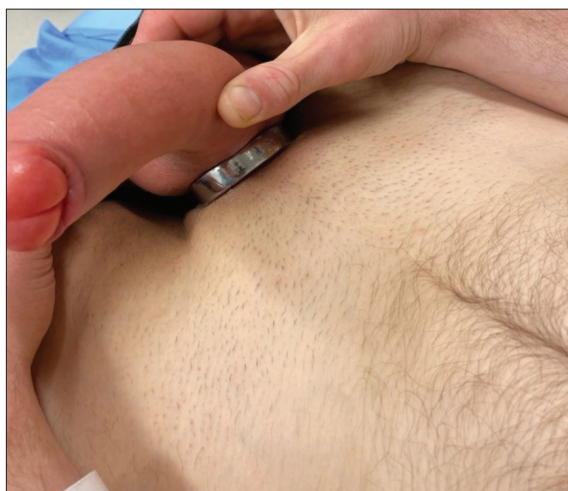

Figure 2. Patient presentation.

ally or in combination, for the removal of penile rings;^{10,11} however, in cases characterized by pronounced penile edema, conventional methods may prove inadequate, as evidenced in our patient's scenario. Notably, Kyomukama et al have documented the effective use of an angle grinder metal cutter, complemented by accessories, offering an alternative technique for ring extrication.¹²

The primary objective of intervention is the expeditious restoration of arterial inflow, venous, and lymphatic drainage to avert further damage. Delay in reinstating proper blood flow and drainage has been associated with instances of penile amputation.¹¹

Trivedi et al emphasize the diverse clinical presentation and management approaches encountered with penile constriction devices.¹³ Consequently, individualized judgment on a case-by-case basis has proven

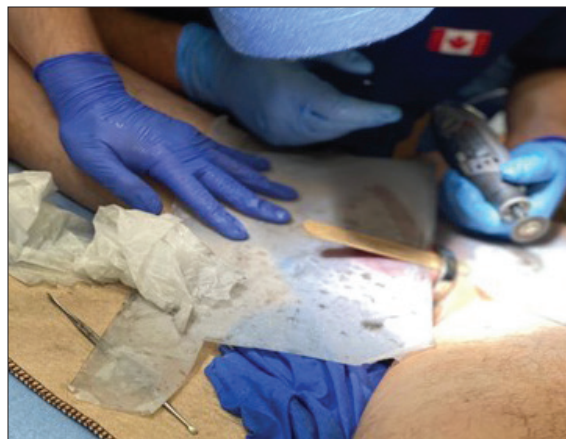

Figure 3. Plastic cards used to protect skin.



Figure 4. Tongue depressor under the penile ring to protect skin.

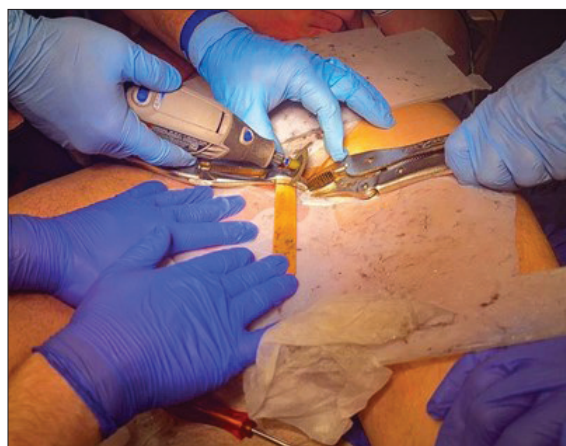


Figure 5. Electrical grinder metallic cutter used to cut penile ring.

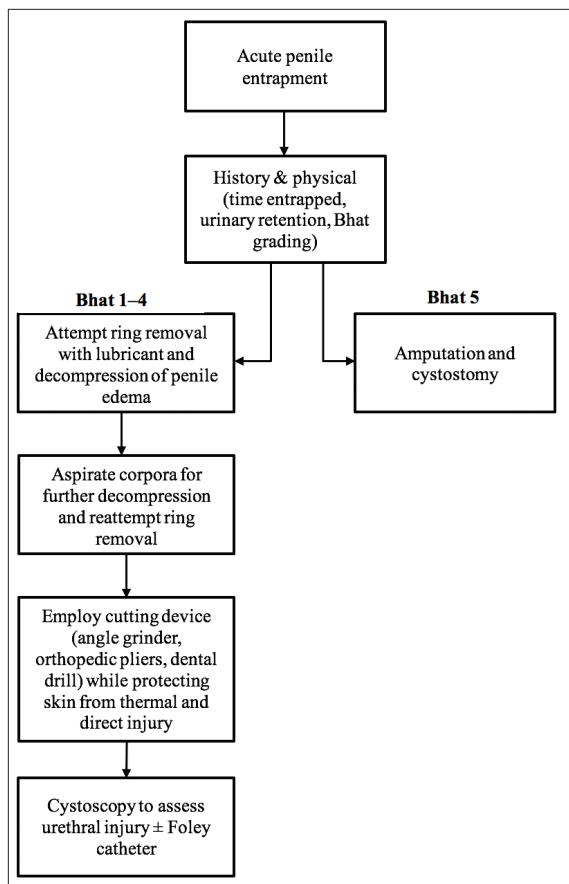


Figure 6. Proposed treatment algorithm for acute penile entrapment

Table 1. Penile strangulation classification system by Bhat et al	
Grade I	Distal penis edema. No evidence of skin ulceration or urethral injury.
Grade II	Distal penile edema with decreased sensation. Injury to skin, constriction of corpus spongiosum. No urethral injury.
Grade III	Injury to skin and urethra, without urethral fistula. Loss of distal penile sensation.
Grade IV	Complete division of corpus spongiosum leading to urethral fistula and constriction of corpus cavernosum with loss of distal penile sensation.
Grade V	Gangrene, necrosis, or complete amputation of penis.

instrumental in enhancing the surgical outcomes for these patients.^{10,14}

Presently, there exists no universally agreed-upon followup protocol, with post-treatment plans typically contingent on the severity of the case and the preferences of the attending surgeon. We suggest an algorithm, as shown in Figure 6, to be followed when similar cases present to the emergency department.

This algorithm is based on our review of the existing literature and clinical judgement.

CONCLUSIONS

The exigency of removing constriction devices causing penile strangulation underscores the importance of a prompt and suitable intervention involving mechanical or electrical tools within an emergency context. This article underscores the merit of adopting a case-specific strategy, particularly when distal tissue edema is evident. The absence of a standardized followup protocol highlights the imperative for personalized care, emphasizing its tailoring to the severity of the case and the surgeon's discretion.

COMPETING INTERESTS: Dr. Krakowsky has been an advisory board member for Acerus, Felix Pharma, and Viatrix; is on the speakers' bureau for Humber River Hospital; and has received grant(s) or an honorarium from Coloplast. The remaining authors do not report any competing personal or financial interests related to this work.

This paper has been peer reviewed.

REFERENCES

- Poonam S, Kshetrimayum N, Rana I. Penile strangulation by iron metal ring: A novel and effective method of management. *Urol Ann* 2017;9:74-6. <https://doi.org/10.4103/0974-7796.198873>
- Alkhureeb M. Case report of early release of penile strangulation by metallic rings. *International Journal of Science and Research (USR)* 2016;5:1442-4. <https://doi.org/10.21275/v5i11.nov1531363>
- Nuhu A, Edino ST, Agbese GO, et al. Penile gangrene due to strangulation by a metallic nut: A case report. *West Afr J Med* 2009;28:340-2. <https://doi.org/10.4314/wajim.v28i5.55018>
- Sawant AS, Patil SR, Kumar V, et al. Penile constriction injury: An experience of four cases. *Urol Ann* 2016;8:512-5. <https://doi.org/10.4103/0974-7796.192101>
- Sharma PK, Vijay M, Das RK, et al. Metallic ring used for autoerotic purpose leading to serious strangulating penile injury and its management. *UroToday Int J* 2011;04. <https://doi.org/10.3834/uj.1944-5784.2011.12.08>
- How do erectile dysfunction rings work? 2013. Available at: <https://prostate.net/articles/how-do-erectile-dysfunction-rings-work>. Accessed on Feb. 4, 2019
- Dawood O, Tabibi S, Fiuk J, et al. Penile ring entrapment - A true urologic emergency: Grading, approach, and management. *Urol Ann* 2020;12:15-8. https://doi.org/10.4103/UA.UA_16_19
- N.S. Williams, in: N.S. Williams (Ed.), *Bailey & Love's Short Practice of Surgery*, 27th ed., 2020.
- Bhat G. Penile entrapment: A case where innovation is the need of the hour. *Acta Medica International* 2018;5:90. https://doi.org/10.4103/ami.ami_87_17
- Koifman L, Hampf D, Silva MI, et al. Treatment options and outcomes of penile constriction devices. *Int Braz J Urol* 2019;45:384-91. <https://doi.org/10.1590/S1677-5538.IBJU.2018.0667>
- Saraj JK, Ahmad A, Sachan A, Yadav G. Penile strangulation due to metallic ring: A surgical emergency. *Int Surg J* 2019;6:4160. <https://doi.org/10.18203/2349-2902.isj20195145>
- Kyomukama LA, Ssebuufu R, Wani SA, et al. Penile ring entrapment and strangulation: A case report at Kampala International University Teaching Hospital in Western Uganda. *Int J Surg Case Rep* 2021;80:104982. <https://doi.org/10.1016/j.ijscr.2020.09.080>
- Trivedi S, Attam A, Kerketa A, et al. Penile incarceration with metallic foreign bodies: Management and review of literature. *Curr Urol* 2013;7:45-50. <https://doi.org/10.1159/000343554>
- Saha PK, Alam SM, Amin AN, et al. Surgical outcome for treating penile strangulation by heavy metallic ring. *J Surg Sci* 2019;17:96-8. <https://doi.org/10.3329/jss.v17i2.43784>

CORRESPONDENCE: Dr. Mohamad Baker Berjaoui, Division of Urology, Department of Surgery, University of Toronto, Toronto, ON, Canada; mohamadbaker.berjaoui@gmail.com