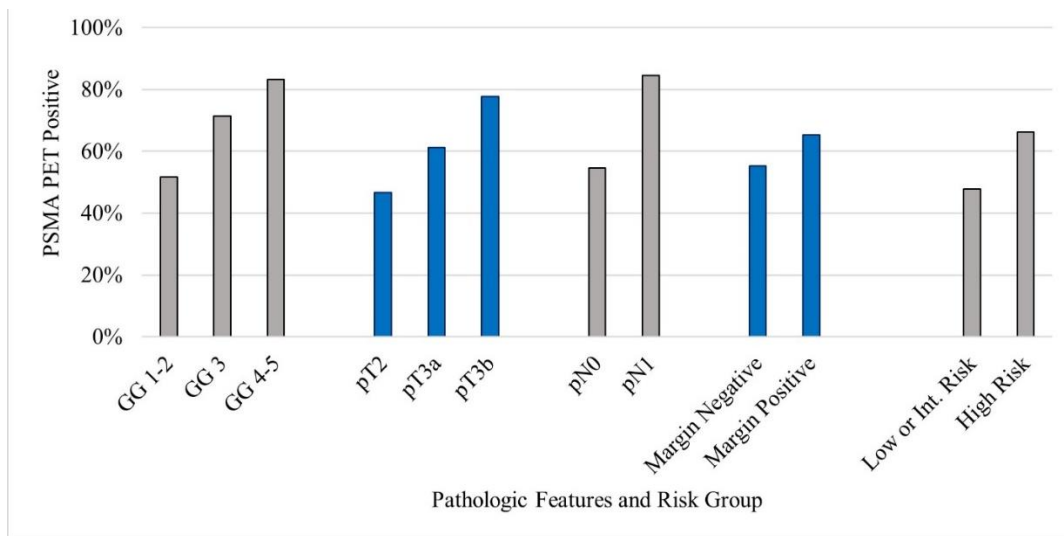


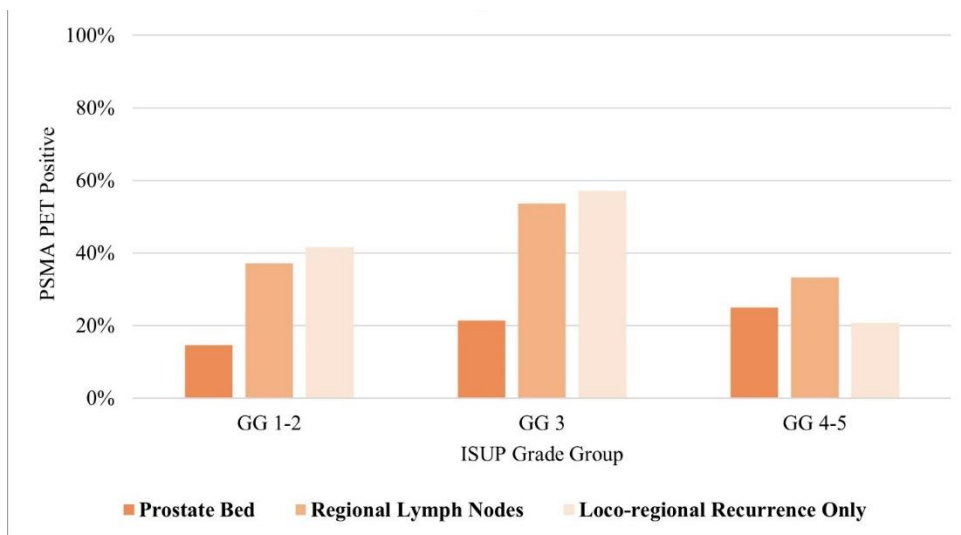
Sigurdson et al. Patterns of failure with ¹⁸F-DCFPyL PSMA-PET/CT in the post-prostatectomy setting: A regional cohort analysis

APPENDIX

Supplementary Figure 1. Overall prostate-specific member antigen-positron emission tomography/computed tomography (PSMA-PET) positivity rate.

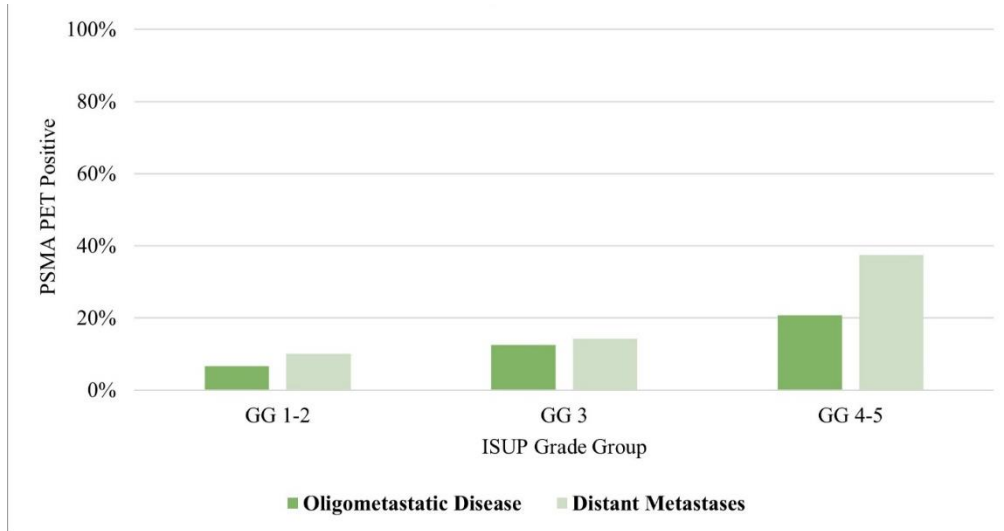


Supplementary Figure 2. International Society of Urological Pathology (ISUP) grade group: Local recurrence. PSMA-PET: prostate-specific member antigen-positron emission tomography.

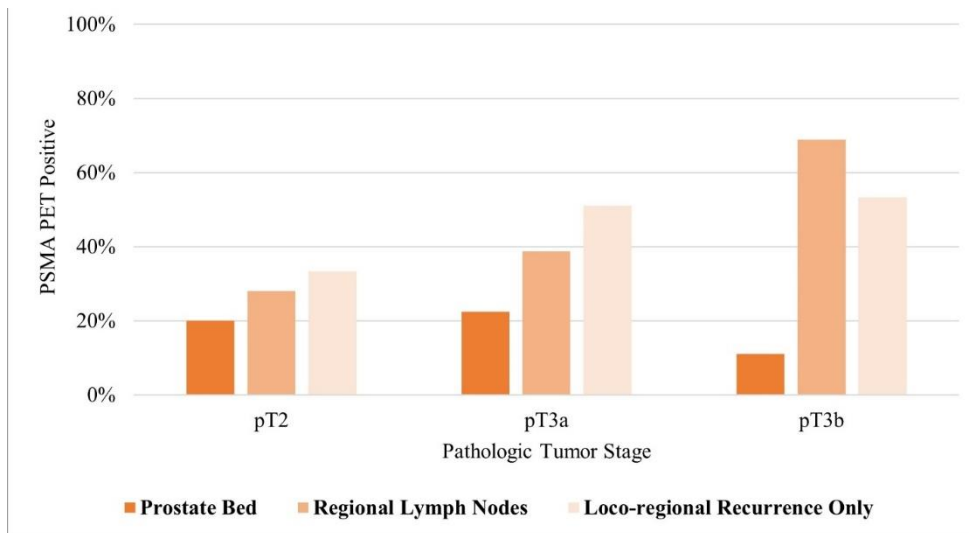


Sigurdson et al. Patterns of failure with ¹⁸F-DCFPyL PSMA-PET/CT in the post-prostatectomy setting: A regional cohort analysis

Supplementary Figure 3. International Society of Urological Pathology (ISUP) grade group: Distant recurrence. PSMA-PET: prostate-specific member antigen-positron emission tomography.

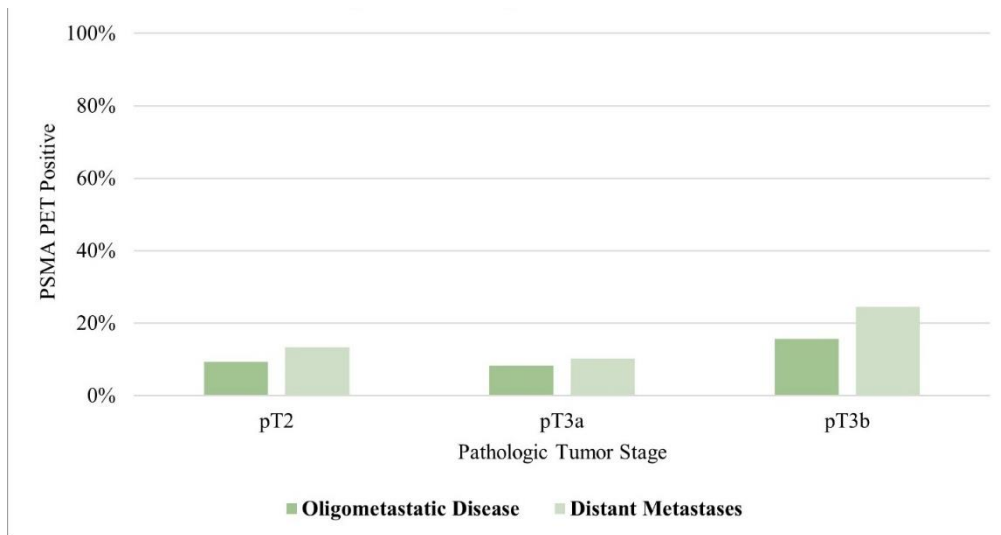


Supplementary Figure 4. Pathologic tumor stage: Local recurrence. PSMA-PET: prostate-specific member antigen-positron emission tomography.

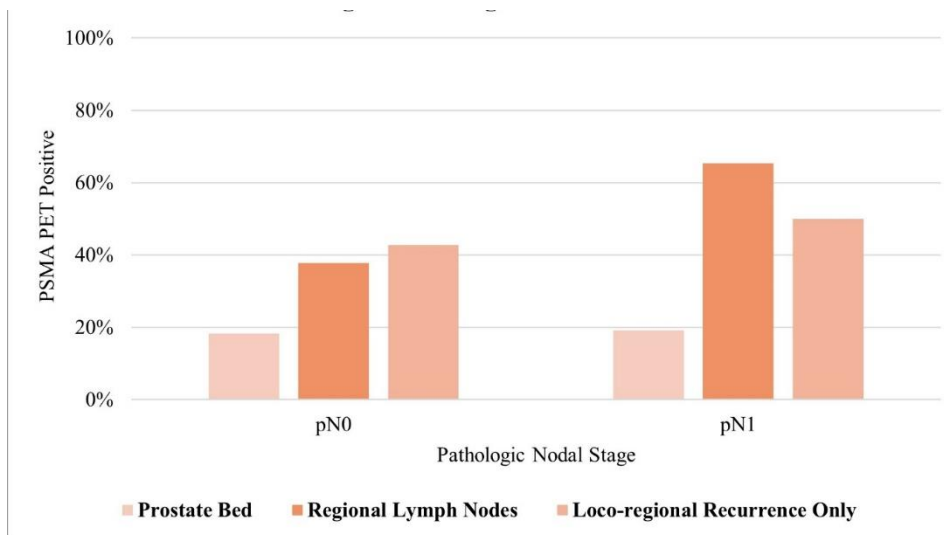


Sigurdson et al. Patterns of failure with ¹⁸F-DCFPyL PSMA-PET/CT in the post-prostatectomy setting: A regional cohort analysis

Supplementary Figure 5. Pathologic tumor stage: Distant recurrence. PSMA-PET: prostate-specific member antigen-positron emission tomography.

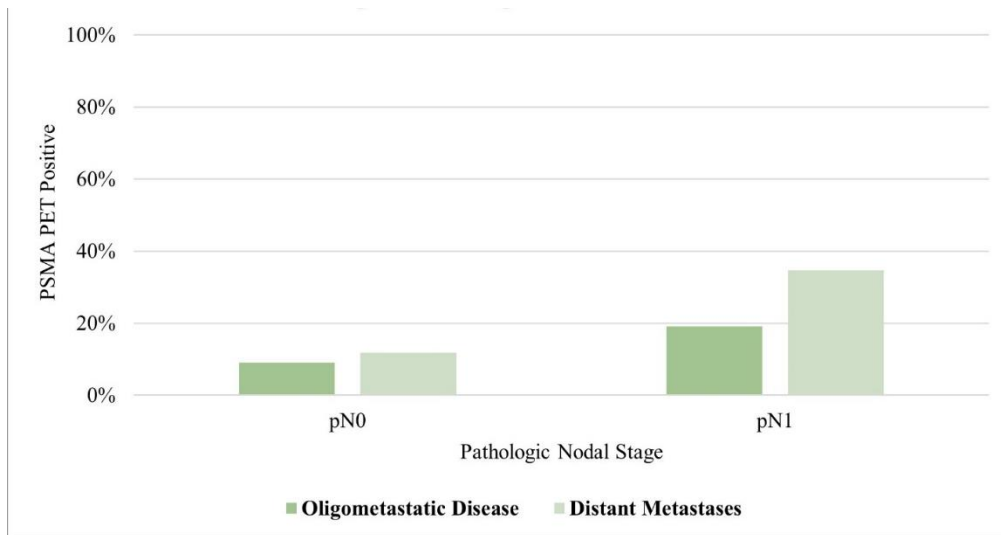


Supplementary Figure 6. Pathologic nodal stage: Local recurrence. PSMA-PET: prostate-specific member antigen-positron emission tomography.

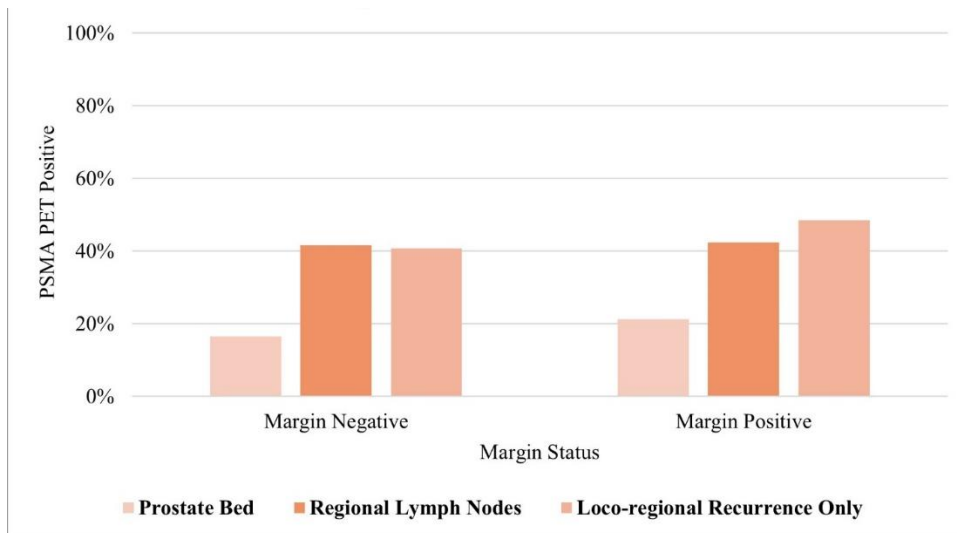


Sigurdson et al. Patterns of failure with ¹⁸F-DCFPyL PSMA-PET/CT in the post-prostatectomy setting: A regional cohort analysis

Supplementary Figure 7. Pathologic nodal stage: Distant recurrence. PSMA-PET: prostate-specific member antigen-positron emission tomography.

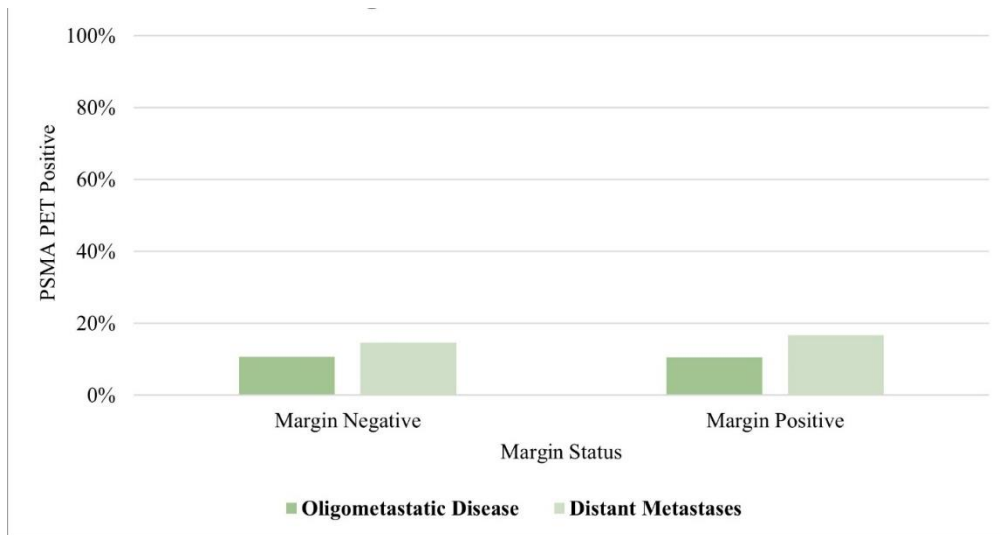


Supplementary Figure 8. Margin status: Local recurrence. PSMA-PET: prostate-specific member antigen-positron emission tomography.

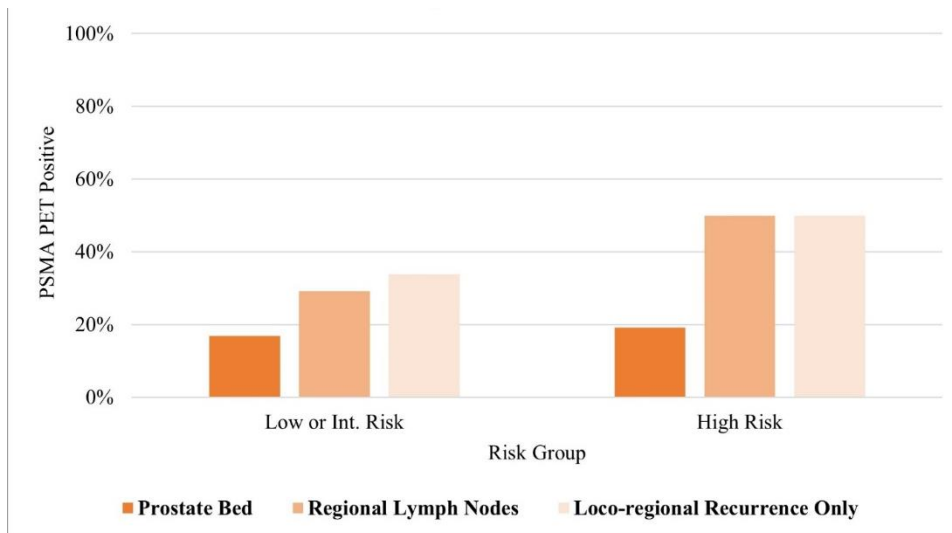


Sigurdson et al. Patterns of failure with ¹⁸F-DCFPyL PSMA-PET/CT in the post-prostatectomy setting: A regional cohort analysis

Supplementary Figure 9. Margin status: Distant recurrence. PSMA-PET: prostate-specific member antigen-positron emission tomography.



Supplementary Figure 10. Risk group: Local recurrence. PSMA-PET: prostate-specific member antigen-positron emission tomography.



Sigurdson et al. Patterns of failure with ¹⁸F-DCFPyL PSMA-PET/CT in the post-prostatectomy setting: A regional cohort analysis

Supplementary Figure 11. Risk group: Distant recurrence. PSMA-PET: prostate-specific member antigen-positron emission tomography.

