

Case series - Laparoscopic radical nephrectomy for kidney cancer in pregnancy

Braden Millan¹, Katherine Steckham², Meghan Elizabeth Ough Vlasschaert^{2,3}, David Hogarth⁴, Geoffrey Gotto⁴

¹Department of Surgery, McMaster Institute of Urology, McMaster University, Hamilton, ON, Canada; ²Department of Medicine, University of Calgary, Calgary, AB, Canada; ³Department of Obstetrics and Gynecology, University of Calgary, Calgary, AB, Canada; ⁴Department of Surgery, Southern Alberta Institute of Urology, University of Calgary, Calgary, AB, Canada

Cite as: Millan B, Steckham K, Vlasschaert MEO, et al. Case – Laparoscopic radical nephrectomy for kidney cancer in pregnancy. *Can Urol Assoc J* 2025;19(9):E341-3 <http://dx.doi.org/10.5489/cuaj.8842>

Published online May 16, 2025

INTRODUCTION

Kidney cancer (KC) accounts for approximately 2% of all adult neoplasms, and renal cell carcinoma (RCC) accounts for approximately 90% of all cases.¹ KC is primarily a disease of older adults and, therefore, rarely seen in pregnancy.²⁻⁵ It is expected that the number of pregnancies complicated by KC will rise due to the increased prevalence of 1) risk factors for KC in pregnant patients, including obesity, hypertension, and chronic kidney disease; and 2) advanced maternal age.² While guideline-directed treatment options for localized KC are based on multiple factors, there are no published consensus guidelines on the management of KC in pregnancy.^{6,7}

Maternal renal masses may be found incidentally during routine fetal ultrasonography. Signs and symptoms of KC can be non-specific and, therefore, mistakenly attributed to pregnancy. Magnetic resonance imaging (MRI) without gadolinium is a safe alternative to computed tomography (CT) in pregnancy.⁸ A biopsy may be considered for indeterminate masses; however, this requires discussion with patients about potential complications and limitations of pathologic results.⁹

Following diagnosis, the management in pregnancy poses a challenge, as the safety of both mother and fetus must be considered when discussing treatment and timing of intervention. Given the complexity of a diagnosis of KC in pregnancy, a multidisciplinary approach is recommended to formulate an individualized treatment plan.

Many T1a small renal masses <4 cm, and especially those <2 cm, can be managed with surveillance,

including repeat imaging at six months. Surgical management of localized T1a RCC has excellent cancer-specific outcomes, with a local recurrence rate of 5% at five years, and can typically be delayed by several months without a negative impact on prognosis.⁷ Local recurrence rates increase to 15% for T1b, regardless of surgical approach (radical vs. partial nephrectomy), and surveillance is not recommended in these cases.¹⁰ In young patients, particularly with clinical T1b RCC, surgical extirpation is the gold-standard treatment; however, it can be challenging to determine if surgery should be performed or delayed during pregnancy. We report the outcomes of three cases of RCC in pregnancy at a tertiary care center in Canada from 2021–2023 and review the available literature on the management of KC in pregnancy.

CASE SERIES

The cases are summarized in Table 1. The mean maternal age at time of diagnosis was 35±4 years (range 31–41), with the renal masses identified during the first or second trimester. Ultrasound-guided biopsy was completed in two patients who were identified as having renal masses in their second trimesters. No patient had evidence of metastatic disease on chest X-ray or MRI of the abdomen and pelvis (Figure 1).

All three patients underwent preoperative assessment by maternal-fetal medicine (MFM) and anesthesia. Uncomplicated laparoscopic radical nephrectomy was performed in the second trimester for all three patients. Changes in renal function were as expected, with an observed decline in the estimated glomerular filtration rate (eGFR) for all three patients (Figure 2).

Final pathology showed pT1b RCC in all cases (one clear-cell, two chromophobe). All three pregnancies had term deliveries. Cesarean section was performed in two pregnancies for reasons unrelated to the RCC diagnosis or surgery. Postpartum hypertension complicated two pregnancies. With a median followup of 19 months, no patient has evidence of disease on repeat radiographic imaging, although followup imaging modality was not consistent.

DISCUSSION

We have shown that laparoscopic radical nephrectomy is a safe treatment option for pT1b KC in preg-

ID	Age	BMI	GP	Diagnosis	Surgery	Pregnancy/delivery	Followup
1	41	31.9	G6P4	<ul style="list-style-type: none"> – Incidental finding on dating US at 8w2d GA – 4.2 x 4.9 x 3.7 cm on MR abdomen – No evidence of metastatic disease on CXR 	<ul style="list-style-type: none"> – Laparoscopic right radical nephrectomy at 20w6d GA – Pathology: Clear-cell renal cell carcinoma – Stage: pT1bNx – No postoperative complications 	<ul style="list-style-type: none"> – ASA 162 mg nightly for preeclampsia risk reduction until 36 weeks – 3rd trimester fetal assessment: Size AGA – Vaginal delivery at 38w2d following induction – Postpartum hypertension 	<ul style="list-style-type: none"> – NED on KUB US and CXR at 15 months postoperatively
2	31	N/A	G1P0	<ul style="list-style-type: none"> – Renal US at 20w3d GA for pyelonephritis showed renal mass – 4.7 x 5.8 x 6.2 cm on MR abdomen – No evidence of metastatic disease on CXR 	<ul style="list-style-type: none"> – Laparoscopic right radical nephrectomy at 22w3d GA – Pathology: Chromophobe renal cell carcinoma – Stage: pT1bNx – No postoperative complications 	<ul style="list-style-type: none"> – 3rd trimester fetal assessment: Size AGA and normal Dopplers – Cesarean section at 38w5d for breech presentation – Postpartum hypertension 	<ul style="list-style-type: none"> – NED on MR A/P at 20 months postoperatively (done for abdominal pain in subsequent pregnancy)
3	32	21.8	G4P1	<ul style="list-style-type: none"> – Incidental finding of abdominal US for proctitis flare at 17w2d GA – 6.7 x 6.2 x 7.0 cm on MR abdomen – No evidence of metastatic disease on CXR 	<ul style="list-style-type: none"> – Laparoscopic right radical nephrectomy at 23w1d GA – Pathology: Chromophobe renal cell carcinoma – Stage: pT1bNx – No postoperative complications 	<ul style="list-style-type: none"> – 3rd trimester fetal assessment: Size AGA – Repeat Cesarean delivery at 39w4d – No HDP – No postpartum follow-up 	<ul style="list-style-type: none"> – NED on CT A/P at 23 months postoperatively

AGA: appropriate for gestational age; CT A/P: computed tomography of the abdomen and pelvis; CXR: chest X-ray; G: gravida; GA: gestational age; HDP: hypertensive disorder of pregnancy; MR: magnetic resonance; NED: no evidence of disease; P: parity; US: ultrasound.

nancy. The first step in managing KC during pregnancy involves accurately diagnosing and staging the disease. In our case series, MRI without gadolinium (n=3) and renal mass biopsy (n=2) were performed to confirm the diagnosis of RCC and help determine optimal timing of surgery. Chest X-ray was used for staging purposes to rule out lung metastases.

For small, localized tumors, active surveillance during pregnancy with deferred treatment until after delivery may be an option. Regular monitoring and imaging to determine tumor growth are crucial if opting for surveillance. This approach is based on the relatively slow growth rate of localized KC, the known safety of surveillance for small renal masses (<4 cm), and the desire to avoid unnecessary interventions during pregnancy.⁷

In cases where the KC is more advanced or aggressive, treatment during pregnancy may be necessary, ideally during the second trimester to reduce the risk of spontaneous miscarriage (first trimester) and preterm labor (third trimester).¹¹ In a 2021 literature review including 29 cases by Maggen et al, 17 (59%) of which underwent elective surgery from 7–29 weeks' gestation, surgery was delayed until the postpartum period in 12 cases (41%), which were all stage I (clinical T1) at diagnosis. Twenty-one pregnancies (81%) resulted

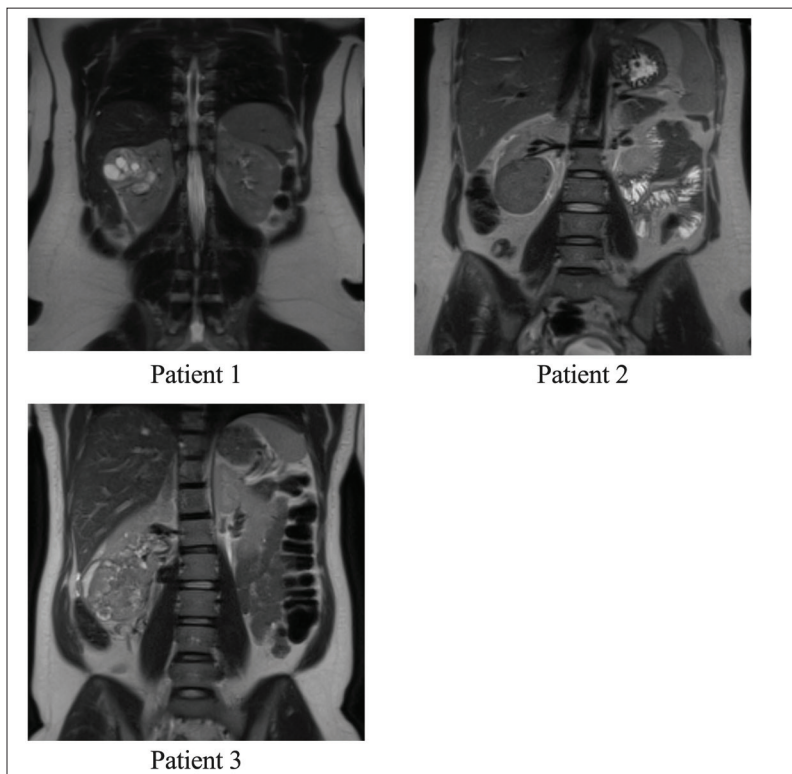


Figure 1. Preoperative staging non-contrast magnetic resonance imaging of all three patients (labeling per Table 1).

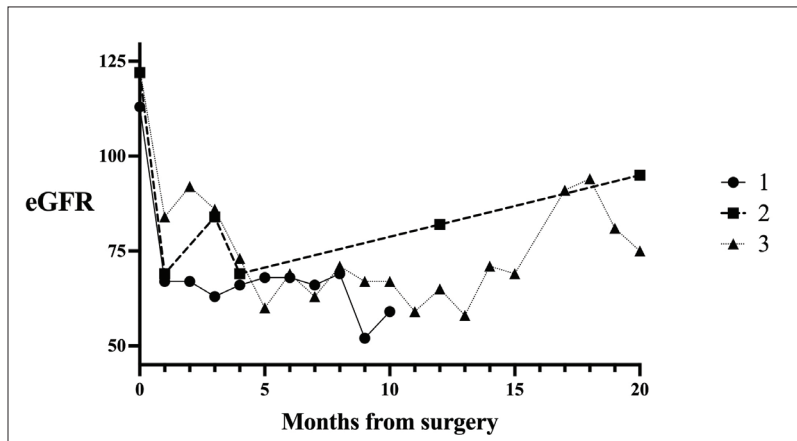


Figure 2. Postoperative/postpartum changes in in estimated glomerular filtration rate (eGFR) for all three patients (labeling per Table 1).

in live birth. There was one spontaneous miscarriage following nephrectomy. There were two stillbirths, one of which was the result of hemorrhagic shock from renal tumor rupture, which also resulted in maternal death. Nineteen of 29 patients had oncologic followup available out to a median of 30 months. Of these 19 patients, 15 (79%) had no evidence of cancer recurrence.⁴ These results highlight both the surgical risks and oncologic challenges associated with KC, and the importance of timely management in pregnancy.

A review by Dell'Atti et al identified 91 pregnant patients with RCC, 66 (73%) of whom underwent surgery. Laparoscopic surgery was performed in only 13 (20%) of the cases.³ Specific considerations for laparoscopic surgery in pregnancy are paramount, including more cranial positioning of port sites, gradual inflation of pneumoperitoneum, close monitoring of maternal carbon dioxide levels, and prevention of maternal hypotension.^{3,12,13} Both the transperitoneal and retroperitoneoscopic routes have been used in pregnancy. Similar to non-pregnant patients, the benefits of laparoscopic surgery include a faster recovery, shorter length of stay, and a trend toward lower wound infection rates.¹³

Postpartum management will depend on the treatment completed in pregnancy. In general, surveillance is determined by the cancer stage and risk of developing recurrence or metastases, as outlined in recent guidelines.¹⁴ The role of adjuvant systemic immunotherapy is not clearly defined and should be considered on a case-by-case basis.¹⁵

CONCLUSIONS

The management of KC during pregnancy requires an individualized approach that carefully weighs the risks

and benefits for both mother and fetus. Collaboration between medical specialties, including MFM, obstetric medicine, and anesthesiology, is essential to optimize outcomes. The goal is to provide effective cancer treatment while ensuring maternal and fetal well-being. Laparoscopic radical nephrectomy appears to be a safe option, although further studies are needed to confirm our findings and explore alternative management approaches.

COMPETING INTERESTS: The authors do not report any competing personal or financial interests related to this work.

REFERENCES

- Sung H, Ferlay J, Siegel RL, et al. Global Cancer Statistics 2020: GLOBOCAN estimates of incidence and mortality worldwide for 36 cancers in 185 countries. *CA Cancer J Clin* 2021;71:209-49. <https://doi.org/10.3322/caac.21660>
- Bukavina L, Bensalah K, Bray F, et al. Epidemiology of renal cell carcinoma: 2022 update. *Eur Urol* 2022;82:529-42. <https://doi.org/10.1016/j.eururo.2022.08.019>
- Dell'Atti L, Borghi C, Galosi AB. Laparoscopic approach in management of renal cell carcinoma during pregnancy: State of the art. *Clin Genitourin Cancer* 2019;17:e822-30. <https://doi.org/10.1016/j.clgc.2019.05.025>
- Maggen C, Linsen J, Gziri MM, et al. Renal and bladder cancer during pregnancy: A review of 47 cases and literature-based recommendations for management. *Urology* 2021;151:118-28. <https://doi.org/10.1016/j.urol.2020.08.084>
- Khaled H, Lahloubi NA, Rashad N. Review on renal cell carcinoma and pregnancy: A challenging situation. *J Adv Res* 2016;7:575-80. <https://doi.org/10.1016/j.jare.2016.03.007>
- Campbell SC, Clark PE, Chang SS, et al. Renal mass and localized renal cancer: Evaluation, management, and follow-up: AUA Guideline: Part I. *J Urol* 2021;206:199-208. <https://doi.org/10.1097/JU.0000000000001911>
- Richard PD, Violette PD, Bhindi B, et al. Canadian Urological Association guideline: Management of small renal masses - Full-text. *Can Urol Assoc J* 2022;16:E61-75. <https://doi.org/10.5489/cuaj.7763>
- Mathur S, Pillenahalli Maheshwarappa R, Fouladirad S, et al. Emergency imaging in pregnancy and lactation [Formula: see text]. *Can Assoc Radiol J* 2020;71:396-402. <https://doi.org/10.1177/0846537120906482>
- Lavallee LT, McAlpine K, Kapoor A, et al. Kidney Cancer Research Network of Canada (KCRNC) consensus statement on the role of renal mass biopsy in the management of kidney cancer. *Can Urol Assoc J* 2019;13:377-83. <https://doi.org/10.5489/cuaj.6176>
- Dabestani S, Thorstenson A, Lindblad P, et al. Renal cell carcinoma recurrences and metastases in primary non-metastatic patients: A population-based study. *World J Urol* 2016;34:1081-6. <https://doi.org/10.1007/s00345-016-1773-y>
- Pearl JP, Price RR, Tonkin AE, et al. SAGES guidelines for the use of laparoscopy during pregnancy. *Surg Endosc* 2017;31:3767-82. <https://doi.org/10.1007/s00464-017-5637-3>
- Zhao Y, Yang Z, Xu W, et al. Management of renal tumors during pregnancy: Case reports. *BMC Nephrol* 2021;22:127. <https://doi.org/10.1186/s12882-021-02318-w>
- Ball E, Waters N, Cooper N, et al. Evidence-based guideline on laparoscopy in pregnancy: Commissioned by the British Society for Gynaecological Endoscopy (BSGE) endorsed by the Royal College of Obstetricians & Gynaecologists (RCOG). *Facts Views Vis Obgyn* 2019;11:5-25.
- Kassouf W, Monteiro LL, Drachenberg DE, et al. Canadian Urological Association guideline for followup of patients after treatment of non-metastatic renal cell carcinoma. *Can Urol Assoc J* 2018;12:231-8. <https://doi.org/10.5489/cuaj.5462>
- Lalani AA, Kapoor A, Basappa NS, et al. Adjuvant therapy for renal cell carcinoma: 2023 Canadian Kidney Cancer Forum consensus statement. *Can Urol Assoc J* 2023;17:E154-E163. <https://doi.org/10.5489/cuaj.8381>

CORRESPONDENCE: Dr. Braden Millan, Department of Surgery, McMaster Institute of Urology, McMaster University, Hamilton, ON, Canada; braden.millan@medportal.ca