

Outcomes following inguinal and subinguinal urologic procedures under deep intravenous sedation

Maximilian G. Fidel¹, Jainik Shah¹, Dhiraj S. Bal¹, Yool Ko¹, Connor Roque¹, Harliv Dhillon², David Chung³, Alagarsamy Pandian⁴, Jasmir G. Nayak^{2,3}, Premal Patel^{2,3}

¹Max Rady College of Medicine, Rady Faculty of Health Sciences, University of Manitoba, Winnipeg, MB, Canada; ²Men's Health Clinic Manitoba, Winnipeg, MB, Canada; ³Section of Urology, Department of Surgery, Rady Faculty of Health Sciences, University of Manitoba, Winnipeg, MB, Canada; ⁴Department of Anesthesia, Rady Faculty of Health Sciences, University of Manitoba, Winnipeg, MB, Canada

Cite as: Fidel MG, Shah J, Bal DS, et al. Outcomes following inguinal and subinguinal urologic procedures under deep intravenous sedation. *Can Urol Assoc J* 2024;18(10):335-40. <http://dx.doi.org/10.5489/cuaj.8841>

Published online June 10, 2024

ABSTRACT

INTRODUCTION: We aimed to investigate the surgical outcomes following inguinal and subinguinal urologic procedures under deep intravenous sedation (DIVS) with multimodal local anesthesia (LA).

METHODS: We conducted a retrospective cohort study from September 2022 to December 2023 including adult patients deemed eligible for day surgery (American Society of Anesthesiologist score 1–3) undergoing radical orchiectomy (RO), microscopic varicocelectomy (MV), or microscopic denervation of the spermatic cord (MDSC). All procedures were performed at a single urologic ambulatory surgical center and outpatient clinic, and by a single surgeon (PP). Procedures were performed through a subinguinal or inguinal approach with DIVS and adjunctive multimodal LA. We evaluated intraoperative complications and relevant surgical outcomes and parameters.

RESULTS: A total of 103 patients were included in the analysis with a mean age \pm standard deviation of 37.3 ± 9.6 . This included 25 patients who underwent RO, 54 patients who underwent MV, and 24 patients who underwent MDSC. All procedures were completed successfully without intraoperative complications. Oncologic outcomes were preserved, fertility outcomes improved, and pain scores reduced similarly to the expected rates in the literature.

CONCLUSIONS: Our preliminary results demonstrate the safety, effectiveness, and feasibility of performing inguinal and subinguinal urologic procedures under DIVS with LA. These findings suggest that this technique preserves high-quality care while avoiding the unnecessary risks of general or spinal anesthesia, representing an opportunity to transfer these cases outside of hospitals' operating rooms into outpatient ambulatory centers.

INTRODUCTION

Inguinal and subinguinal surgical approaches are commonly used in urologic procedures to treat testicular malignancies as well as benign conditions including infertility and chronic orchialgia. Inguinal incisions are classically used for radical orchiectomies for ligation of the spermatic cord at the level of the internal ring. At the same time, the subinguinal approach is often used to treat benign urologic conditions, offering reduced pain by avoiding the need to open the external oblique aponeurosis.^{1,2}

Traditionally, these approaches are thought to necessitate general (GA) or spinal anesthesia (SA), with the choice of anesthetic being driven largely by safety, feasibility, and patient comfort;^{3,4} however, given the severe surgical backlog, which has only further accumulated following the COVID-19 pandemic, it has become increasingly difficult to complete cases requiring a hospital operating room (OR) in a timely fashion.⁵

Deep intravenous sedation (DIVS) in conjunction with local anesthetic (LA) is an alternative choice of anesthetic that can be used in the ambulatory surgical setting. DIVS is often regarded as a safer alternative to GA, having shown a stronger safety profile, greater perioperative patient comfort, and improved recovery compared to traditional forms of anesthesia.^{6,7} Notably, DIVS negates the need for intubation as spontaneous ventilation is maintained, reducing the risks of upper airway trauma and patient-

KEY MESSAGES

- Limited evidence exists supporting the use of local anesthesia with adjunctive deep intravenous sedation (DIVS) for inguinal and subinguinal surgical approaches in urologic settings.
- DIVS with local anesthesia allowed patients to be safely discharged earlier while maintaining favorable outcomes.
- Further implementation of this technique may allow patients to receive similar quality of care while avoiding the unnecessary risks associated with general or spinal anesthesia, in addition to facilitating more optimal use of resources.

related factors complicating anesthesia, while providing the capability of being used in an office-based setting under the supervision of an anesthesiologist. DIVS has also been used to perform more invasive office-based procedures, reducing the use of a hospital OR and associated resources.⁶⁻⁹ Similarly to GA, SA carries its own risks including post-dural puncture headaches and urinary retention, in addition to the time required to establish successful anesthesia.¹⁰ Currently, limited definitive evidence exists supporting the use of DIVS with LA for inguinal and subinguinal surgical approaches within urologic settings.

This study sought to retrospectively assess the surgical outcomes and parameters of urologic procedures performed through an inguinal or subinguinal approach under DIVS with adjunctive multimodal LA. The primary objectives included the evaluation of complication frequency and outcomes following radical orchiectomies (ROs) using the inguinal approach, and microscopic varicocelectomies (MV) or microscopic denervation of spermatic cords (MDSC) via the subinguinal method.

The secondary objective was to assess effectiveness by characterizing surgical success rates for all procedures and comparing them to reported procedures performed under GA or SA documented in existing literature. We hypothesize that both inguinal and subinguinal urologic procedures can be safely and effectively performed under DIVS with adjunctive multimodal LA, increasing accessibility to these procedures while utilizing overnight facilities more effectively.

METHODS

A retrospective cohort study was performed for patients undergoing a RO, MV, or MDSC under DIVS with adjunctive multimodal LA at a single outpatient ambulatory surgical center. Approval for this study was obtained from the University of Manitoba's Health and Research Ethics Board (HS26301).

Study population and data collection

All procedures were performed at a single urologic ambulatory surgical center and outpatient clinic from September 2022 to December 2023. All procedures were performed by a single surgeon (PP). Inclusion criteria included adult patients who were deemed eligible for day surgery, classified by the American Society of Anesthesiologists (ASA) as 1–3, and undergoing either a RO, MV, or MDSC under DIVS. Exclusion criteria included patients receiving an RO for reasons other than a suspected testicular tumor and patients classified as ASA 3 with severe obstructive sleep apnea who were not CPAP-compliant.

Baseline demographic information included patient body mass index (BMI) and a comorbidity score as assessed by the Charlson Comorbidity Index. Preoperative ultrasound results were collected to assess the characteristics of suspected tumors and to describe the presence and size of varicoceles. Bloodwork was collected prior to RO procedures to assess for serum tumor markers including alpha-fetoprotein, human chorionic gonadotropin, and lactate dehydrogenase. Varicoceles were graded clinically according to the Dubin and Amela classification system by the surgeon prior to MV. Baseline semen analysis (SA) was conducted before all MV procedures, with the most favorable values being used to calculate the baseline total motile sperm count (TMSC).

For all procedures, various intraoperative complications were assessed: conversion to GA, perioperative patient procedure intolerance, concerns related to anesthesia, and procedure abortion. Intraoperative complications were monitored for by the surgeon and anesthesiologist, and were only recorded in the OR and anesthesia record upon occurrence. Surgical parameters were collected and analyzed following all procedures, assessing for the duration of the surgery (defined as the time of incision to time of dressing) and sedation recovery time (defined as the time of entry into the post-anesthesia recovery room to time of discharge). Tumor histopathology, surgical margins, and tumor size were assessed and recorded following RO procedures. Pain resolution for MDSC was reported by

patients as no pain, minimal pain, moderate pain, and severe pain. SA was repeated at least three months postoperatively following all MV procedures and was used to calculate postoperative TMSC.

Procedural and anesthetic protocol

All procedures were performed with a standard inguinal or subinguinal approach, with all patients receiving a combination of sedation, peripheral nerve block, and local anesthetic.¹¹⁻¹³ Intravenous sedation was administered by an anesthesiologist with induction involving intravenous midazolam (5 mg) and ketamine (20 mg), and continuous infusion of propofol (30–50 mcg/kg/min) and remifentanyl (0.05 mcg/kg/min).

Perioperative prophylactic antibiotics (1–2 g of cefazolin) were administered one hour before the procedure. Peripheral nerve block was achieved with the guidance of point-of-care ultrasound by the anesthesiologist following identification of the ilioinguinal nerve. Following antiseptic preparation of the overlying skin, a 22G 50 mm Pajunk needle was inserted using an in-plane approach from a point of view just below the inferior border of the ultrasound transducer towards the ilioinguinal nerve.

A small amount of LA was injected to confirm correct positioning at which point 10 mL of 0.25% bupivacaine and 1% lidocaine were injected, after careful aspiration, in 5 mL aliquots. The surgeon injected 20 mL of the identical local anesthetic mixture into the spermatic cord. The surgeon also administered the local anesthetic mixture into the dermal layer at the site of incision. Patients were discharged on the same day from the facility, prescribed tramadol-acetaminophen and were seen four to six weeks postoperatively for followup.

Data analysis

Patient charts were accessed for data collection retrospectively, with de-identified data exported into Microsoft Excel (Microsoft Office, Microsoft Corporation, Redmond, WA). Baseline demographics, preoperative data, surgical parameters and outcomes, and intraoperative complications were analyzed descriptively. Statistical analysis was performed for TMSC values following MV procedures using Welch’s t-test to account for unequal variances between baseline and postoperative TMSC values, with $p < 0.05$ being considered statistically significant.

RESULTS

Between September 2022 and December 2023, 103 patients met the study criteria and were included, with

25 patients undergoing a RO, 54 patients undergoing a MV, and 24 patients undergoing a MDSC. Patient enrolment is described in Figure 1 following the Strengthening the Reporting of Observational Studies in Epidemiology (STROBE) observational study guidelines. Baseline characteristics including number of patients per procedure, age, BMI, Charlson Comorbidity Index, ASA classification, and laterality of procedure are depicted in Table 1. The grading of varicoceles is shown in Table 2, with 53% of all left-sided varicoceles being grade 2 and 43% of all right-sided varicoceles having been grade 1. All procedures were performed successfully without any intraoperative complications reported.

Histopathology, pathology, and relevant surgical parameters following RO are described in Table 3. Negative surgical margins were demonstrated in 100% of patients who underwent a RO (n=23), with surgical margins not having been described in secondary tumors. The mean surgery duration ± SD for RO procedures was 39.6±17.4 minutes, with a mean recovery time of 56.5±18.8 minutes.

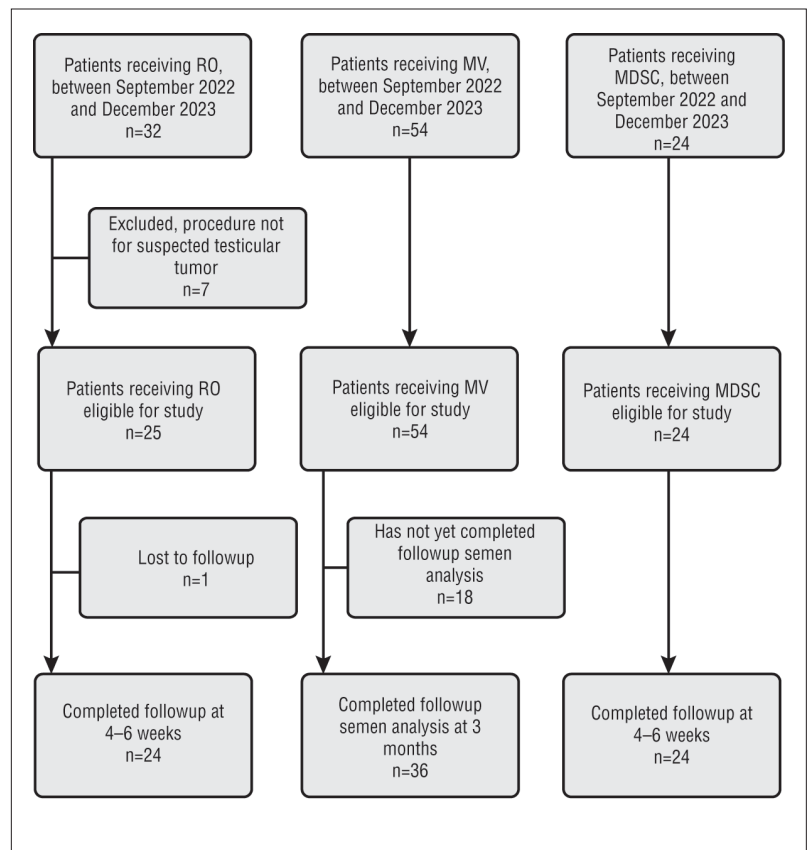


Figure 1. Report numbers of individuals at each stage of study as per STROBE guidelines. MDSC: microscopic denervation of the spermatic cord; MV: microscopic varicocelectomy; RO: radical orchiectomy.

Table 1. Baseline patient characteristics

	Procedure type		
	Radical orchiectomy	Microscopic varicocelectomy	Microscopic denervation of the spermatic cord
Patient characteristics			
Number of patients	25	54	24
Mean age (years)	38.8±14.7	35.1±5.2	40.5±14.0
Mean BMI (kg/m ²)	27.7±4.9	27.6±4.7	27.9±6.1
CCI	0.1	0.1	0.2
ASA score			
ASA 1 (%)	56	72	54
ASA 2 (%)	36	26	29
ASA 3 (%)	8	2	17
Laterality			
Left-sided (%)	52	59	52
Right-sided (%)	48	2	26
Bilateral (%)	0	39	22

ASA: American Society of Anesthesiologists Physical Status Classification System; BMI: body mass index; CCI: Charlson Comorbidity Index.

Table 2. Varicocele grades prior to microscopic varicocelectomy

Side of varicocele	Grade 1 (%)	Grade 2 (%)	Grade 3 (%)
Left	11	53	36
Right	43	36	21

For MV procedures, the mean baseline TMSC ± SD was $18.2 \times 10^6 \pm 31.5 \times 10^6$ (n=48), with the mean postoperative TMSC increasing to $29.1 \times 10^6 \pm 60.3 \times 10^6$ (n=36), $p = 0.3228$. As described in Figure 1, 18 patients have not completed their three-month postoperative semen analysis but were still included in the intraoperative complications analysis. The mean surgery duration for MV procedures was 49.1 ± 15.1 minutes and the mean recovery time was 56.5 ± 18.8 minutes.

The mean duration of surgery for MDSC procedures was 39.8 ± 12.9 minutes, with the mean recovery time being 52.7 ± 26.8 minutes. Following MDSC, 54% of patients (n=13) reported completely resolved orchialgia, 38% (n=9) reported minimal pain, and 8% (n=2) reported experiencing a moderate amount of pain, when compared to their original pain.

DISCUSSION

This retrospective study assessed the safety and feasibility of various inguinal and subinguinal urologic procedures under DIVS with multimodal LA as an adjunct. Our study demonstrates that conducting these commonly performed urologic procedures with either surgical approach can be safely, effectively, and feasibly performed under DIVS with adjunctive LA, without compromising intraoperative complexity.

In the context of limited OR time and resources, the ability to refer less complicated patients, such as those described in this study, to an outpatient ambulatory surgical center can optimize the use of healthcare resources while expanding the urologic workforce. The diversion of less complex patients facilitated the use of a main hospital's OR resources for more complicated patients and procedures while increasing accessibility for patients.

Sedation has also been previously demonstrated to be less costly when compared to GA, with one study having found the mean cost (in USD) of sedation per patient by an anesthesiologist to be \$84.2, compared to \$605.4 for GA.¹⁴ Although not measured in this study, the use of sedation may also alleviate a portion of the burden mounting on fiscal healthcare resources. Additionally, DIVS can be administered by registered nursing staff trained and certified in sedation.¹⁵ Further implementation of nursing staff trained in sedation can optimize the use of anesthesiologists, further contributing to improved resource allocation. These findings are of particular interest for universal healthcare systems, such as Canada, as longer wait times for patients and limited healthcare resources are frequently seen.

Patient safety and comfort are of the utmost importance in the selection of an anesthetic approach, the consideration of which should be prioritized when optimizing an anesthetic protocol. Despite being standard practice, both GA and SA are still associated with risks to the patient.^{3,6} Still, GA and SA have been the anesthesia of choice for inguinal and subinguinal procedures, as they can both effectively accommodate the perioperative stretch of the spermatic cord, which can elicit a vagal reflex with ensuing bradycardia and pain for the patient.¹⁶

Multimodal anesthetic approaches have long been used for open inguinal hernia repairs, eliciting similar spermatic cord stimulation to the procedures investigated in our study, with minimal complications.¹⁷ A previously published pilot study demonstrated that deploying a multimodal LA approach in combination with DIVS, during a RO under an inguinal approach,

further reduced any pain experienced by the patient following spermatic cord stimulation, with the benefit of retrograde amnesia.¹⁸

Similarly, it has been recently demonstrated that MV procedures using a subinguinal approach can be safely and effectively performed under multimodal LA alone, with postoperative patient tolerability remaining trivial.⁴ Our study furthered these findings by demonstrating perioperative tolerability in patients undergoing an MV under multimodal LA, which in part may be attributed to the DIVS used in our approach. Additionally, this study was able to successfully build upon findings in prior work by increasing the sample size in the inguinal cohort and demonstrating a variety of procedures using subinguinal approaches.

Following MV, patients demonstrated a non-statistically significant improvement in their TMSC. The lack of statistical significance may be a result of the small sample size or due to the followup semen analysis occurring at three months, with changes in TMSC typically being significant six months postoperatively.¹⁹ All patients who underwent a MDSC reported either a complete or partial improvement in their pain at their 4–6-week postoperative interview, which is comparable to outcomes reported in the literature.²⁰

The average duration of our RO procedures was 39.6±17.4 minutes, which is comparable to the 30 minutes reported in previous literature.²¹ Similarly, for subinguinal procedures, the mean duration of surgery for MV and MSCD procedures was 49.1±15.1 minutes and 39.8±12.9 minutes, which is comparable to the average durations cited in the literature of 38.6±10.7 minutes and 86 (75–110) minutes, respectively.^{22,23} All patients were safely discharged within one hour following their procedure, within a mean stay in postoperative recovery of 44.4±14.7 minutes in MV procedures and 56.5±18.8 minutes in RO procedures. These times are notably shorter than the reported post-anesthetic recovery times for GA, which averages 116 minutes for safe discharge, and SA, requiring 150–180 minutes for full ambulation.^{24,25}

These findings demonstrate that the use of DIVS with adjunctive LA allowed patients to be safely discharged earlier while maintaining favorable surgical outcomes without compromising intraoperative complexity — an important consideration in the outpatient ambulatory surgical setting.

Limitations

The limitations of this study are mainly attributed to its retrospective and non-randomized design, which pre-

Table 3. Histopathology, pathology, and relevant surgical parameters following radical orchiectomy

Histopathology		
Primary tumors	Seminoma, n (%)	12 (48)
	Non-seminoma, n (%)	8 (32)
Secondary tumors	Large B-cell lymphoma, n	2
Benign tumors	Leydig cell tumor, n	1
	Epididymal cyst, n	1
Negative*, n		1
Pathology		
pT1, n (%)		15 (75)
pT2, n (%)		5 (25)
Surgical parameters		
Size of tumor, cm (range)		3.6 (0.7–9.3)
Negative margin status, n (%)		23** (100)
*Pathology indicated specimen negative for malignancy. **Surgical margins were not described for the two secondary tumors.		

vented a more objective and complete measurement of variables and outcomes. As a result, the data in this study was mainly described descriptively.

Another limitation of this study was the subjective assessment of patient-reported postoperative sedation tolerability, and pain following MDSC procedures being limited to no pain, minimal pain, moderate pain, and severe pain. Furthermore, all data was collected in a single outpatient ambulatory surgical center with all procedures being performed by a single surgeon (PP), which may limit the external validity of our findings.

A further limitation was in the collection of surgery durations, which did not factor in the time for anesthesia induction. This prevented this study from making a more meaningful comparison of the impact of various anesthetics on OR times. Additionally, we recognize that our study only described patients who were classified ASA 1–3 and on average did not have any significant comorbidities that may further limit the validity of our findings beyond outpatient ambulatory surgical centers.

Future prospective studies should involve an objective and standardized method of formally assessing patient postoperative tolerability of sedation.

CONCLUSIONS

Inguinal and subinguinal urologic procedures performed under DIVS in combination with multimodal LA are safe, effective, and feasible in an outpatient ambulatory surgical center. Further implementation of this technique may allow patients to receive similar quality of care while avoiding the unnecessary risks associated with GA or SA. Additionally, these practices may facilitate more optimal use of OR resources in healthcare, particularly those that are publicly funded, while increasing accessibility for patients.

COMPETING INTERESTS: Dr. Patel is a consultant for Boston Scientific Corporation. The remaining authors do not report any competing personal or financial interests related to this work.

FUNDING: Coloplast – Investigator-initiated grant

This paper has been peer reviewed.

REFERENCES

- Gontero P, Pretti G, Fontana F, et al. Inguinal vs. subinguinal varicocele vein ligation using magnifying loupe under local anesthesia: Which technique is preferable in clinical practice? *Urology* 2005;66:1075-9. <https://doi.org/10.1016/j.urology.2005.05.009>
- Pan F, Pan L, Zhang A, et al. Comparison of two approaches in microsurgical varicocelelectomy in Chinese infertile males. *Urol Int* 2013;90:443-8. <https://doi.org/10.1159/000345606>
- Li L, Pang Y, Wang Y, et al. Comparison of spinal anesthesia and general anesthesia in inguinal hernia repair in adult: A systematic review and meta-analysis. *BMC Anesthesiol* 2020;20:64. <https://doi.org/10.1186/s12871-020-00980-5>
- Wang X, Pan C, Li J, et al. Prospective comparison of local anesthesia with general or spinal anesthesia in patients treated with microscopic varicocelelectomy. *J Clin Med* 2022;11:6397. <https://doi.org/10.3390/jcm11216397>
- Waiting your turn: Wait times for healthcare in Canada, 2022 Report. Fraser Institute. Published December 8, 2022. Available at: <https://bit.ly/311dgRx>. Accessed March 20, 2024.
- Bharadwaj S, Dougherty W. Anesthesia for office-based facial plastic surgery procedures. *World J Otorhinolaryngol* 2023;9:200-5. <https://doi.org/10.1002/wjo2.131>
- Jumaily JS, Jumaily M, Donnelly T, et al. Quality of recovery and safety of deep intravenous sedation compared to general anesthesia in facial plastic surgery: A prospective cohort study. *Am J Otolaryngol* 2022;43:103352. <https://doi.org/10.1016/j.amjoto.2021.103352>
- Tikka T, Hilmi OJ. Upper airway tract complications of endotracheal intubation. *Br J Hosp Med* 2019;80:441-7. <https://doi.org/10.12968/hmed.2019.80.8.441>
- Shiley SG, Lalwani K, Milczuk HA. Intravenous sedation vs general anesthesia for pediatric otolaryngology procedures. *Arch Otolaryngol Head Neck Surg* 2003;129:637-41. <https://doi.org/10.1001/archotol.129.6.637>
- Agarwal A, Kishore K. Complications and controversies of regional anesthesia: A review. *Indian J Anaesth* 2009;53:543-53.
- Koschel SG, Wong LM. Radical inguinal orchidectomy: The gold standard for initial management of testicular cancer. *Transl Androl Urol* 2020;9:3094-102. <https://doi.org/10.21037/tau.2019.12.20>
- Mehta A, Goldstein M. Microsurgical varicocelelectomy: A review. *Asian J Androl* 2013;15:56-60. <https://doi.org/10.1038/aja.2012.98>
- Sun HH, Tay KS, Jesse E, et al. Microsurgical denervation of the spermatic cord: A historical perspective and recent developments. *Sex Med Rev* 2022;10:791-9. <https://doi.org/10.1016/j.sxmr.2021.11.005>
- Obara S, Nakata Y, Yamaoka K. Cost-effectiveness analysis of sedation and general anesthesia regimens for children undergoing magnetic resonance imaging in Japan. *J Anesth* 2022;36:359-66. <https://doi.org/10.1007/s00540-022-03051-w>
- Amornyotin S. Registered nurse-administered sedation for gastrointestinal endoscopic procedure. *World J Gastrointest Endosc* 2015;7:769-76. <https://doi.org/10.4253/wjge.v7.i8.769>
- Tekgöl ZT, Harsanali BÖ, OzanHarsanali M, et al. Anesthesia for urological surgery. *Current Topics in Anesthesiology*. IntechOpen; 2017. Available at: <https://doi.org/10.5772/66197>. Accessed March 20, 2024.
- Bakota B, Kopljar M, Šimić D, et al. Complications, pain control, and patient recovery after local versus general anesthesia for open inguinal hernia repair in adults — systematic review and meta-analysis. *Int Surg* 2016;101101:144-52. <https://doi.org/10.9738/INTSURG-D-15-00065.1>
- Lu S, Pandian A, Nayak JG, et al. Outcomes and patient tolerability of radical inguinal orchidectomy under deep intravenous sedation. *Can Urol Assoc J* 2024;18:E8-11. <https://doi.org/10.5489/cuaj.8395>
- Masterson TA, Greer AB, Ramasamy R. Time to improvement in semen parameters after microsurgical varicocelelectomy in men with severe oligospermia. *Can Urol Assoc J* 2019;13. <https://doi.org/10.5489/cuaj.5408>
- Tatam A, Kovac JR. Chronic scrotal pain and microsurgical spermatic cord denervation: tricks of the trade. *Transl Androl Urol* 2017;6:530-6. <https://doi.org/10.21037/tau.2017.05.17>
- Removing a testicle (orchidectomy) for testicular cancer. Available at: <https://www.cancerresearchuk.org/about-cancer/testicular-cancer/treatment/surgery/removing-testicle>. Accessed March 21, 2024.
- Söylemez H, Penbegül N, Atar M, et al. Comparison of laparoscopic and microscopic subinguinal varicocelelectomy in terms of postoperative scrotal pain. *JSLIS* 2012;16:212-7. <https://doi.org/10.4293/108680812X13427982376220>
- Chaudhari R, Sharma S, Khant S, et al. Microsurgical denervation of spermatic cord for chronic idiopathic orchialgia: Long-term results from an institutional experience. *World J Mens Health* 2019;37:78-84. <https://doi.org/10.5534/wjmh.180035>
- Kajiyama S, Kobayashi M, Okada Y. Criteria for postoperative discharge of the patients managed by anesthesiologists in an ambulatory surgery unit. *Masui* 2004;53:882-7.
- Imarengiaye CO, Song D, Prabhu AJ, et al. Spinal anesthesia: Functional balance is impaired after clinical recovery. *Anesthesiology* 2003;98:511-5. <https://doi.org/10.1097/0000542-200302000-00033>

CORRESPONDENCE: Dr. Premal Patel, Section of Urology, Health Sciences Centre, University of Manitoba, Winnipeg, MB, Canada; ppatel5@hsc.mb.ca