

Case – Inferior vena caval thrombus associated with a left-sided renal cell carcinoma during pregnancy

Kiley A. Hyland¹, Nicholas E. Power^{1,2,3}, Melissa J. Huynh^{1,2,3}

¹Schulich School of Medicine, Western University, London, ON, Canada; ²Division of Urology, Department of Surgery, Western University, London, ON, Canada; ³London Health Sciences Centre, London, ON, Canada

Cite as: Hyland KA, Power NE, Huynh MJ. Case –Inferior vena caval thrombus associated with a left-sided renal cell carcinoma during pregnancy. *Can Urol Assoc J* 2024;18(9):E295-7. <http://dx.doi.org/10.5489/cuaj.8730>

Published online May 21, 2024

CASE REPORT

A 36-year-old female primipara at 17+4 weeks gestational age was found to have a 10x10 cm left renal mass on abdominal ultrasound after presenting with gross hematuria and flank pain. Her past medical history was significant for giant cell tumor of the brainstem, which was surgically removed in 2016, and migraines. She did not drink alcohol, smoke cigarettes, or use other substances.

In collaboration with obstetrics & gynecology and the patient, an informed decision was made to complete a computed tomography (CT) of the thorax, abdomen, and pelvis, which demonstrated a left renal mass measuring 15.7x13.4x18.1 cm. It infiltrated into the left renal vein, crossing the midline, with enhancing tumor entering the inferior vena cava (IVC). This appeared to be a level II thrombus. No metastatic disease was identified (Figure 1).

In consultation with high-risk obstetrics, the recommended management was an open left nephrectomy and IVC thrombectomy at 17–20 weeks' gestational age. The patient was heavily counseled on the risk of intraoperative hypotension and potential fetal demise or fetal compromise leading to neurologic deficit. At the time of the proposed surgery, delivery of the fetus was not an option due to non-viability. This was a very desired pregnancy, and preoperative termination was not an acceptable option to the patient. The hope was to milk the tumor thrombus back into the renal vein to avoid the need for cross-clamping the IVC.

The patient underwent a left radical nephrectomy, left adrenalectomy, and IVC thrombectomy

at 18+4 weeks gestational age. Pre- and postoperative Dopplers were done to assess fetal well-being. The left renal artery was identified and then ligated, and subsequently, the left renal vein was ligated after successfully milking back the IVC thrombus into the renal vein before dividing it. The cavotomy was then closed in a running fashion, and the rest of the kidney was mobilized and removed for pathology. Estimated blood loss was 800 mL. There were no postoperative complications. The pathology report demonstrated clear cell renal carcinoma, pT3b, N0, Fuhrman grade 4 with negative margins. Tumor necrosis and lymphovascular invasion were present.

A magnetic resonance imaging (MRI) at three months postoperatively showed no recurrence or metastases. The patient gave birth at 39+4 weeks to a healthy live female infant via Caesarean section after recurrent fetal variable decelerations. Postpartum, the patient underwent a surveillance CT thorax, abdomen, pelvis, which showed a 1 cm hypodensity in the liver. MRI demonstrated enhancement of the liver lesion, which was suspicious for metastatic disease.

The patient's case was presented at both liver and genitourinary multidisciplinary tumor boards. The favored diagnoses included focal nodular hyperplasia or hepatocellular adenoma. Recommended management options included close surveillance or attempted biopsy. The patient underwent biopsy, which demonstrated histology consistent with hepatocellular adenoma and was not suggestive of metastatic clear cell renal carcinoma. Subsequent CT showed stability in the size of the lesion, and the patient continues to undergo surveillance with no recurrence of disease. Given the patient's young age, genetic testing has been performed, and no germline mutations were detected.

DISCUSSION

Although antenatal surgery increases the risk of obstetric complications, this case demonstrates that open radical nephrectomy can be successfully performed during pregnancy. While small renal cell carcinomas typically have a slow growth rate, prevention of progression is paramount for improving survival outcome.¹ Our patient was found to have stage pT3b,

KEY MESSAGES

- Urologic malignancy during pregnancy is rare. It is most often found incidentally, though patients can present with symptoms, such as hematuria.
- Both laparoscopic and open surgical approaches can be used during pregnancy; however, the selected approach depends on the clinical context.
- Given the rarity of urologic malignancies diagnosed in pregnancy and the lack of guidelines, management for these patients should be individualized and multidisciplinary in nature.

N0, clear-cell renal carcinoma at presentation. Disease-specific five-year survival rates for stage T3b renal cell carcinoma (RCC) range from 47–62%;^{2,3} however, this decreases to 29% with more advanced disease stage, and surgical management options become limited.³ Additionally, further tumor growth and ongoing hematuria may have led to other maternal and fetal complications due to blood loss, thrombosis and mass effect. Given the stage, size, and significant symptoms, surgical management was recommended in this case.

The proportion of patients requiring non-obstetrical surgery during pregnancy ranges from 0.75–4.8%.⁴ The vast majority of these procedures are for appendicitis, adnexal pathology, or cholecystitis.⁵ Both laparoscopic and open approaches can be used during pregnancy;

however, the selected approach depends on the clinical context.

With respect to renal tumors specifically, Guglielmetti et al found no significant differences in operative time or length of stay when they compared open vs. laparoscopic approaches for partial nephrectomy;⁶ however, this is not consistent across the literature, as others have demonstrated that open approaches may result in increased blood loss and length of stay.⁷ Regarding the timing of surgery during pregnancy, the American College of Obstetricians and Gynecologists recommends that medically necessary surgery should not be delayed regardless of trimester.⁸ This is also supported by the Society of American Gastrointestinal and Endoscopic Surgeons, who recommend laparoscopy during pregnancy when surgery is indicated.⁹ In taking into account the large size of this patient's tumor and the potential for maternal and fetal morbidity if management were delayed, an open nephrectomy completed urgently was the most appropriate approach for this patient and resulted in good outcomes for the patient and her child.

The risk of spontaneous abortion (SA) and pre-term birth (PTB) after non-obstetric abdominal surgeries is increased compared to those who did not undergo surgery. Risk reported in the literature varies from a 1.57–3.1-fold increase in SA and 1.2–2.1-fold increase in PTB.^{5,10,11} Although completion of non-elective surgery during pregnancy is important for maternal and fetal health, and is generally safe, patients should be counseled regarding the risk to their pregnancy. To minimize risk intraoperatively, fetal monitoring pre- and postoperatively after the 16th week of gestation is recommended.¹²

To our knowledge, there is one reported case in the literature of a clear-cell RCC managed with radical nephrectomy during the second trimester with resulting term pregnancy.¹³ This case differed in that there was no tumor thrombus extending into the IVC. In our case, the presence of IVC tumor thrombus complicated matters due to the possibility of requiring cross-clamping of the IVC, which could result in hypoperfusion of the placenta and fetus. Thankfully, that was not necessary, as we were able to milk the thrombus back into the renal vein to avoid cross-clamping. There are other cases of clear cell RCC diagnosed during pregnancy where tumor thrombus was present; however, surgical management was able to be delayed until after parturition via Caesarean section.^{14,15}

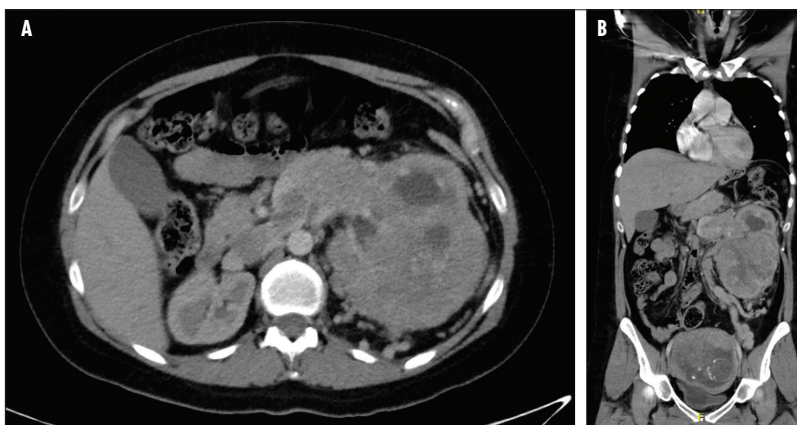


Figure 1. Representative computed tomography (CT) axial (A) and coronal (B) images of a large left renal mass with thrombus extending throughout the left renal vein into the inferior vena cava in a patient at 17+4 weeks gestation.

CONCLUSIONS

Locally advanced renal malignancies diagnosed antenatally may be safely surgically managed intrapartum, though preoperative counseling is necessary to weigh the risks and benefits in each individual case. To our knowledge, this is the only case report in the literature of a patient undergoing a radical nephrectomy and caval thrombectomy during pregnancy for RCC, with subsequent successful delivery of the fetus. Given the rarity of RCC in pregnancy, this case supports the need for individualized and multidisciplinary care.

COMPETING INTERESTS: Dr. Huynh has received honoraria for advisory board participation from Astellas and Knight Therapeutics and for giving a presentation on PSMA PET imaging from Knight Therapeutics. All remaining authors do not report any competing personal or financial interests related to this work.

This paper has been peer reviewed.

REFERENCES

- Nerli R, Devaraju S, Hiremath MB, et al. Tumor doubling time or renal cell carcinoma measured by CT. *Indian J Urol* 2014;30:153-7. <https://doi.org/10.4103/0970-1591.126894>
- Coons BJ, Stec AA, Stratton KL, et al. Prognostic factors in T3b renal cell carcinoma. *World J Urol* 2009;27:75-9. <https://doi.org/10.1007/s00345-008-0358-9>
- Fibarra V, Righetti R, Pilloni S, et al. Prognostic factors in patients with renal cell carcinoma: retrospective analysis of 675 cases. *Eur Urol* 2002;41:190-98. [https://doi.org/10.1016/S0302-2838\(01\)00027-6](https://doi.org/10.1016/S0302-2838(01)00027-6)
- Vujic J, Marsoner K, Lipp-Pump AH, et al. Non-obstetric surgery during pregnancy – An eleven-year retrospective analysis. *BMC Pregnancy Childbirth* 2019;382. <https://doi.org/10.1186/s12884-019-2554-6>
- Balinskaite V, Bettle A, Sodhi V, et al. The risk of adverse pregnancy outcomes following nonobstetric surgery during pregnancy. *Ann Surg* 2017;266:260-6. <https://doi.org/10.1097/SLA.0000000000001976>
- Guglielmetti GB, dos Anjos GC, Sawczyn G, et al. A prospective, randomized trial comparing the outcomes of open vs laparoscopic partial nephrectomy. *J Urol* 2022;208:259-67. <https://doi.org/10.1097/JU.0000000000002695>
- You C, Du Y, Wang H, et al. Laparoscopic versus open partial nephrectomy: A systemic review and meta-analysis of surgical, oncological and functional outcomes. *Front Oncol* 2020;10:583979. <https://doi.org/10.3389/fonc.2020.583979>
- American College of Obstetricians and Gynecologists' Committee on Obstetric Practice and the American Society of Anesthesiologists. Nonobstetric surgery during pregnancy. *Obstet Gynecol* 2019;133:e285-6. <https://doi.org/10.1097/AOG.0000000000003174>
- Pearl JP, Raymond PR, Tonkin AE, et al. SAGES guidelines for the use of laparoscopy during pregnancy. *Surg Endosc*. 2017;31:3767-82. <https://doi.org/10.1007/s00464-017-5637-3>
- Rasmussen AS, Christiansen CF, Ulrichsen SP, et al. Non-obstetric abdominal surgery during pregnancy and birth outcomes: A Danish registry-based cohort study. *Acta Obstet Gynecol Scand* 2020;99:469-76. <https://doi.org/10.1111/aogs.13775>
- Yu CH, Weng SF, Ho CH, et al. Pregnancy outcomes following nonobstetric surgery during gestation: a nationwide population-based case-control study in Taiwan. *BMC Pregnancy Childbirth* 2018;18:460. <https://doi.org/10.1186/s12884-018-2079-4>
- Juhász-Böcs I, Salomayer E, Strik M, et al. Abdominal surgery in pregnancy – An interdisciplinary challenge. *Dtsch Arztebl Int* 2014;111:27-8. <https://doi.org/10.3238/arztebl.2014.0465>
- Buda A, Pizzocaro G, Ceruti P, et al. Case report: renal cell carcinoma presenting as hypertension in pregnancy. *Arch Gynecol Obstet* 2008;277:263-5. <https://doi.org/10.1007/s00404-007-0455-9>
- Ghanney EC, Cavallo JA, Levin MA, et al. Renal cell carcinoma with inferior vena cava thrombus extending to the right atrium diagnosed during pregnancy. *Ther Adv Urol* 2017;9:155-9. <https://doi.org/10.1177/1756287217701378>
- Pertia A, Gagua D, Managadze L, et al. Treatment of renal cell carcinoma in pregnancy: simultaneous nephron-sparing surgery and Caesarian section (case report). *Georgian Med News* 2011;201:7-10.

CORRESPONDENCE: Dr. Melissa J. Huynh, Schulich School of Medicine, Western University, London, ON, Canada; mjhuynh9@gmail.com