

Standardizing male pelvic anatomy teaching using a clinical enrichment videoLandan MacDonald¹, Jesse Ory¹, Thejodhar Pulakunta², Dawn L. MacLellan¹¹Department of Urology, Dalhousie University, Halifax, NS, Canada; ²Department of Medical Neuroscience, Faculty of Medicine, Dalhousie University, Halifax, NS, Canada

Cite as: MacDonald L, Ory J, Pulakunta T, et al. Standardizing male pelvic anatomy teaching using a clinical enrichment video. *Can Urol Assoc J* 2024 May21; Epub ahead of print. <http://dx.doi.org/10.5489/cuaj.8712>

Published online May 21, 2024

Corresponding author: Dr. Landan MacDonald, Department of Urology, Dalhousie University, Halifax, NS, Canada; landan@dal.ca

ABSTRACT

Introduction: Evolving trends in medical education and modern curricular changes have reduced the amount of time and resources allocated for anatomy education. As the amount of dedicated anatomy education time decreases, more self-directed learning is required. Cadaveric dissection and didactic teaching have been supplemented with multimedia, clinical anatomy, and imaging for over 20 years with mixed results. Specifically, the use of video-based anatomy teaching increases medical learning, if done methodically.

Methods: A 20-minute video was produced highlighting surgical anatomy using the following operative cases: perineal anatomy (artificial urinary sphincter case), inguinal and testicular anatomy (scrotal orchidopexy for acute testicular torsion), prostate anatomy (robotic radical prostatectomy), and bladder anatomy (endoscopy). The annotated video was shown to first-year medical students. Pre- and post-multiple-choice question quizzes were given to the students. Once submitted, the students completed a survey.

Results: Overall, 191 first-year medical students participated in our study. Average scores were similar between each quiz (50±16% vs. 49±17%); there was no statistically significant change. Seventy-seven percent of participants felt the video improved their knowledge of urologic anatomy and 83% agreed the video should be shown to future classes. Sixty percent of

KEY MESSAGES

- Cadaveric dissection and didactic anatomy teaching has been reduced in medical schools.
- Annotated surgical procedures may improve anatomy knowledge and interest in urology as a specialty.
- Further study is required to determine if this teaching modality improves long-term anatomy knowledge retention.

participants felt the video solidified their anatomy knowledge. Although 78% felt the video was stimulating and entertaining, 43% of the students felt the video increased their interest in pursuing urology as a career choice.

Conclusions: Anatomy teaching can be supplemented using surgical videos, especially in a time when in-person anatomy teaching is limited. Further study is required to determine if this teaching modality improves long-term anatomy knowledge retention.

INTRODUCTION

Evolving trends in medical education and modern curricular changes has de-emphasized basic sciences including anatomy education.¹⁻³ The field of medicine continues to subspecialize, and detailed knowledge of anatomy is essential for training competent physicians. As the amount of dedicated anatomy education time decreases, it therefore falls on self-directed learning to fill the gaps. Cadaveric dissection and didactic teaching has been supplemented with multimedia, clinical anatomy, and imaging for over 20 years⁴ with mixed results.^{3,5} Specifically the use of video-based anatomy teaching has been shown to increase medical learning,⁶ if done methodically.⁷⁻⁹ Videos of only cadaveric dissection have not been shown to significantly improve medical students learning.^{2,10,11} However, adjuncts to anatomy education may help to give medical students clinical relevance to what they are learning and increase knowledge retention.

Our institution is spread over two campuses in separate provinces. Each campus has their own anatomy teaching space and instructor with significant efforts made to standardize teaching between sites. To standardize anatomy education across sites and provide clinical context to the anatomy curriculum, we created a short video highlighting male pelvic anatomy using actual surgical videos. Urology rotations are not mandatory at our institution and many students finish medical school with minimal exposure to the field. This video was also created to expose students to urology and encourage them to pursue urology as an elective which they otherwise would not have considered. We anticipated that our video would improve post-video quiz scores and stimulate interest in urology as a career choice.

METHODS

After receiving approval from our research ethics board (NSHA REB 1025364), a 20-minute surgical anatomy video (SAV) highlighting pelvic anatomy using four operative cases: perineal anatomy (insertion of an artificial urinary sphincter), inguinal and testicular anatomy (scrotal orchidopexy for acute testicular torsion), prostate anatomy (robotic radical prostatectomy), and bladder anatomy (cystoscopy) was produced. The types of surgical cases were chosen collaboratively by the co-authors to best represent that material covered in the anatomy manual. Identified patients were approached on the day of surgery and consent was obtained for operative filming. All videos were de-identified. The video was edited to include only relevant information

that would enhance the understanding of the male pelvic anatomy lab manual and facilitate the student's understanding of the clinical relevance of the anatomy. For example, only key operative steps were shown to shorten the overall length and adequately demonstrate the pertinent anatomy. The video was professionally narrated and included visual annotations to highlight the relevant anatomy. The SAV was critically evaluated by the anatomist responsible for the male pelvic anatomy lab (TP). Figure 1 shows frames from our video with annotation for each operative case. The video was shown to first-year medical students in conjunction with a hands-on cadaveric anatomy session.

To objectively measure the impact of the anatomy video, we prepared two multiple-choice quizzes. Each quiz contained a set of ten unique multiple-choice questions (MCQs), and no questions were repeated. The quizzes were designed to be of equivalent difficulty. The anatomy lab manual was utilized as a content source for creation of the MCQs. The quiz questions were created based on unit objectives provided by undergraduate medical education office (UGME) (Supplementary Material S1) by a urology resident (LM) and vetted by the co-authors (JO and TP) and the Urology Curriculum Coordinator (DLM) to ensure the level of difficulty of the questions was consistent with the Med I end-of-unit examination. We conducted a descriptive study by using a survey to record the satisfaction of the SAV along its effect on their interest in urology as a specialty. Participation in the quizzes and the survey was entirely voluntary for the medical students.

One of the quizzes (the pre-video quiz) was administered before screening the video and the other (the post-video quiz) was administered after. The entire exercise was conducted in a one-hour clinical enrichment session which immediately followed the gross anatomy male pelvis lab session. Students studied the anatomy of the male pelvis in a lab setting using a lab manual and cadaveric prosections. We repeated the exercise with the video and quizzes in a lecture theatre for three consecutive classes of first-year medical students, in the years 2021, 2022, and 2023. In the first year (2021), the video was shown virtually using Microsoft Teams (Microsoft, Redmond, USA) due to COVID-19 restrictions. The following years (2022 and 2023) it was presented in-person in a lecture theatre, distributed simultaneously to both campuses. After a brief introduction, 15 minutes was allotted to the pre-video quiz, then the students watched the 20-minute video, and then 15 minutes was allotted to the post-video quiz. The SAV was made available to students on-line as an educational resource following the session.

Basic statistical analysis was used to determine the mean, median, and standard deviations of satisfaction scores for each section of the feedback form. A paired t-test was used to assess the changes in pre- and post-video quiz scores.

RESULTS

We screened our surgical anatomy video simultaneously to the two campuses for three consecutive first-year medical school classes. Interactions with each class took place during the scheduled urology anatomy lab day for each year. Importantly, we did introduce our project prior to the screening and allowed for any questions. A total of 191 first-year medical students

participated in our study over the 3-year period: 37 students participated in 2021, 76 in 2022, and 78 participated in 2023. Overall, this reflected a 58% participation rate for the entire cohort. Analysis of the student scores on the pre-video quiz and the post-video quiz using the paired t-test, did not show any statistically significant difference ($p < 0.05$).

Results of the survey given to participants are summarized in Figure 2. Eighty-seven percent of the students agreed or strongly agreed that the video objectives were outlined clearly, and 83% felt the video met the objectives (Table 1). Seventy-seven percent of participants felt the video improved their knowledge of male pelvic anatomy. Seventy-nine percent agreed or strongly agreed that the video was stimulating, and 83% felt that it should be shown to future classes. A minority of students (44%) agreed or strongly agreed that the video increased their interest in urology as a career.

Open-ended feedback was also sought from students: video pacing was variably received with some students commenting that the video was too slow, and others that it was too quick. One student remarked on this and suggested that the video may have a more natural flow if an expert in the field was the narrator, rather than someone reading a script. Three students commented that more orientation and labeling during the robot-assisted laparoscopic prostatectomy would improve their understanding of the anatomy. Several students commented on how the annotated anatomic diagrams were helpful prior to being shown the surgical videos. Two students found the video to be more helpful than the cadaver lab: “That 20-minute video was better than the 4.5 hours in an anatomy lab” and “I learned more in this video than 3 sessions in the lab, the diagrams and explanations were excellent [...] and did make me like urology more.” Average scores between MCQ quizzes did not differ statistically when compared using a paired students’ t-test (Table 2).

DISCUSSION

Modern anatomy education has gone through significant evolution in the past 10 years. Prior to the COVID-19 pandemic, anatomy education was undergoing major changes including reductions in total course time.¹² Other changes such as blended learning, interprofessional learning, near-peer teaching, and use of digital innovations were being used by some medical schools.¹³ The pandemic has accelerated these changes by forcing medical schools to adopt virtual methods of anatomy education.^{13,14} Some examples of virtual modalities of anatomy education include virtual dissection, 3D printing, gamification, and virtual reality.¹³

Whether these changes have negatively impacted the education of students remains to be seen. One study reported that when anatomy course directors from 117 American medical schools were asked about students’ performance before and after the pandemic, most responded that it was unchanged. However, 80% of the same group responded that COVID-19 had a negative impact on the quality of anatomy.¹²

The use of videos to supplement anatomy education has been studied previously. Most of these studies evaluate videos of cadaveric dissection. One study found that most of the 196 students supported the addition of dissection educational videos to the curriculum, however they

felt cancellation of in-person anatomy labs negatively affected their education.¹⁵ Another study published that students enjoyed watching dissection videos, but only 23% said they should completely replace conventional in-person labs.¹⁶ When evaluated quantitatively, however, dissection videos do not improve overall knowledge retention.¹⁷⁻¹⁹ It may be the case that aside from knowledge retention, enjoyment and satisfaction of the learning process is important to medical student education.²⁰

There is a paucity of data regarding the use of annotated, narrated surgical videos to enhance medical student anatomy education. One study showed a video of diagnostic laparoscopy and appendectomy to two hundred first year medical students. Knowledge of abdominal wall and peritoneal cavity improved from 62 to 91%, however some questions were identical between both quizzes leading to a potential false elevation in post-quiz marks.²¹ A proof-of-concept was published whereby medical students were shown short clips of gynecological surgeries at the beginning of the rotation. Nearly all students agreed that the videos helped learning about gynecological surgery and that it should be shown to all students at the start of their rotation.²² It has been shown that students were interested in using surgical videos as resources for studying surgical anatomy. The group given access to surgical videos had self-reported improvement in surgical knowledge as well as objectively improved knowledge scores.²³

It is clear from our results that more than 75% students enjoyed the video and felt it improved their knowledge of male pelvic anatomy. The majority agreed that the video should be shown to future classes. We examined open-ended feedback from students. Regarding the pace of the video, especially since we received comments that it could have been slower and faster, the best way to go forward is to use a video player which gives the option to changing the video speed. The surgical anatomy video was screened in a lecture theater and some students felt the effectiveness could be maximized by allowing consumption at home. They do have the option of watching it at their own pace since it is now available to them online. We hired a professional narrator for the video, however, in the future an enthusiastic urologist who has familiarity with the concepts may allow for a more coherent narration. The laparoscopic approach of radical prostatectomy can be disorienting. More time should be dedicated to orienting students to this unfamiliar region, especially when opening the peritoneum to gain access to extraperitoneal structures. Overall, the open-ended feedback provided by students was positive.

Our objective measurements found no difference in quiz results pre- and post-video. There are several explanations for this. Our video may have covered too much material and may be better suited to be consumed at home with options to change the playback speed and replay certain sections. Our quizzes were designed using objectives from UGME and the anatomy lab manual. In the future, the quizzes may benefit from being vetted by a separate group of students to ensure that all the questions were fair and reasonable. We used different questions for our pre- and post-video quizzes, this could also explain our lack of significant difference in scores. Finally, our results may reflect the importance of anatomy labs with cadaveric dissection. Digital

innovations to improve anatomy knowledge may only supplement in-person learning but may not be able to replace it entirely.

Limitations

The results of quizzes are not reflective of learning exclusively from watching the surgical anatomy video but are rather reflective of a cumulative learning from the gross anatomy lab and further reinforcement from the video. Alternately, we should have had a case control method with a cohort of students learning from the video and another cohort learning from the lab and taking the quizzes. But our main intention with the surgical anatomy video was to supplement the gross anatomy lab, not replace it. In addition, it may have been beneficial to validate the MCQs with a group of medical students.

It is possible that our study may have been subject to selection bias, students with an interest in surgical specialties may have been more likely to respond and may have rated the video favorably because of this interest. Our students only exposure to urology is in the first year of medical school, exposure in later years is with surgical selectives. If we had conducted the study with more senior students, we may have noted different results. Another limitation is the limited demographic information about the participants, including their interest and previous exposure to urology and surgery. The surgical cases highlighted in the video were chosen collaboratively by the co-authors to best demonstrate the material covered in the lab manual, it may have been beneficial to use a more systematic process to, such as a Delphi process.

The limitations noted above, in conjunction with a small sample size may be responsible for the lack of improvement in quiz scores despite 77% of students subjectively reporting the video improved their knowledge of male pelvic anatomy.

CONCLUSIONS

Anatomy education has undergone drastic changes amplified by the COVID-19 pandemic. We present results of a narrated, annotated surgical video shown to first-year medical students which achieved our goal of standardizing the clinical enrichment component of the male pelvic anatomy lab in our two distributed learning centers. This ensures that the material delivered to each site is consistent and thus examinable for the students. An additional benefit of the surgical anatomy video is that students can reference it at any time for self-paced learning and review. The clinical enrichment video was well received by the students and felt to be a valuable learning resource. It also increased the student's exposure to urology as a career choice. Impressions of the video were overwhelmingly positive with plans to implement this video into standard UGME curriculum. Currently, it appears that videos such as ours can help enhance anatomy learning but should not replace in-person cadaver teaching.

REFERENCES

1. Davis CR, Bates AS, Ellis H, et al. Human anatomy: Let the students tell us how to teach. *Anat Sci Educ* 2014;7:262-72. <https://doi.org/10.1002/ase.1424>
2. Carmichael SW. Does clinical anatomy deserve another 25 years? Reflections on how clinical anatomy has changed in the past quarter century. *Clin Anat* 2012;25:143-5. <https://doi.org/10.1002/ca.22023>
3. Drake RL, McBride JM and Pawlina W. An update on the status of anatomical sciences education in United States medical schools. *Anat Sci Educ* 2014;7:321-5. <https://doi.org/10.1002/ase.1468>
4. Sugand K, Abrahams P and Khurana A. The anatomy of anatomy: A review for its modernization. *Anat Sci Educ* 2010;3:83-93. <https://doi.org/10.1002/ase.139>
5. Drake RL. Anatomy education in a changing medical curriculum. *Anat Rec* 1998;253:28-31. [https://doi.org/10.1002/\(SICI\)1097-0185\(199802\)253:1<28::AID-AR11>3.0.CO;2-E](https://doi.org/10.1002/(SICI)1097-0185(199802)253:1<28::AID-AR11>3.0.CO;2-E)
6. Ramachandran K and Vijayaraghavan VP. Video-based clinical anatomy lectures for first year medical students: A novel approach. *Int J Sci STUDY* 2017;5:287-90.
7. Mayer RE. Applying the science of learning to medical education. *Med Educ* 2010;44:543-9. <https://doi.org/10.1111/j.1365-2923.2010.03624.x>
8. Iorio-Morin C, Brisebois S, Becotte A, et al. Improving the pedagogical effectiveness of medical videos. *J Vis Commun Med* 2017;40:96-100. <https://doi.org/10.1080/17453054.2017.1366826>
9. Strkalj G, Hulme A, El-Haddad J, et al. Students' perceptions and usage of short anatomy videos: A preliminary study. *Int J Morphol* 2018;36:493-9. <https://doi.org/10.4067/S0717-95022018000200493>
10. Saxena V, Natarajan P, O'Sullivan PS, et al. Effect of the use of instructional anatomy videos on student performance. *Anat Sci Educ* 2008;1:159-65. <https://doi.org/10.1002/ase.38>
11. Choi-Lundberg DL, Low TF, Patman P, et al. Medical student preferences for self-directed study resources in gross anatomy. *Anat Sci Educ* 2016;9:150-60. <https://doi.org/10.1002/ase.1549>
12. Shin M, Prasad A, Sabo G, et al. Anatomy education in US medical schools: Before, during, and beyond COVID-19. *BMC Med Educ* 2022;22:103. <https://doi.org/10.1186/s12909-022-03177-1>
13. Evans DJR and Pawlina W. The future of anatomy education: Learning from Covid-19 disruption. *Anat Sci Educ* 2022;15:643-9. <https://doi.org/10.1002/ase.2203>
14. Patra A, Asghar A, Chaudhary P, et al. Integration of innovative educational technologies in anatomy teaching: New normal in anatomy education. *Surg Radiol Anat* 2022;44:25-32. <https://doi.org/10.1007/s00276-021-02868-6>
15. Natsis K, Lazaridis N, Kostares M, et al. "Dissection educational videos" (DEVs) and their contribution in anatomy education: A students' perspective. *Surg Radiol Anat* 2022;44:33-40. <https://doi.org/10.1007/s00276-021-02829-z>
16. Mustafa AG, Taha NR, Zaqout S, et al. Teaching musculoskeletal module using dissection videos: Feedback from medical students. *BMC Med Educ* 2021;21:604. <https://doi.org/10.1186/s12909-021-03036-5>
17. Mahmud W, Hyder O, Butt J, et al. Dissection videos do not improve anatomy examination scores. *Anat Sci Educ* 2011;4:16-21. <https://doi.org/10.1002/ase.194>

18. Koop CFA, Marschollek M, Schmiedel A, et al. Does an audiovisual dissection manual improve medical students' learning in the gross anatomy dissection course? *Anat Sci Educ* 2021;14:615-28. <https://doi.org/10.1002/ase.2012>
19. Choi-Lundberg DL, Cuellar WA and Williams A-MM. online dissection audio-visual resources for human anatomy: Undergraduate medical students' usage and learning outcomes. *Anat Sci Educ* 2016;9:545-54. <https://doi.org/10.1002/ase.1607>
20. Stone D, Hennessy CM and Smith CF. Teaching with cadavers outside of the dissection room using cadaveric videos. *Adv. Exp Med Biol* 2022;1356:281-97. https://doi.org/10.1007/978-3-030-87779-8_12
21. Pattanshetti S V and Pattanshetti VM. Early exposure of laparoscopic anatomy to first year medical undergraduate students: Is it necessary? *Ital J Anat Embryol* 2018;123:288-296.
22. Stairs J, Amir B and Vair B. The "Virtual OR:" Creation of a surgical video-based gynaecologic surgery teaching session to improve medical student orientation and supplement surgical learning during COVID-19. *Can Med Educ J* 2021;12:149-151. <https://doi.org/10.36834/cmej.72081>
23. Selten JW, Nazari T, Andriessen EH, et al. Standardized videos in addition to the surgical curriculum in medical education for surgical clerkships: A cohort study. *BMC Med Educ* 2022;22:384. <https://doi.org/10.1186/s12909-022-03314-w>

DRAFT

FIGURES AND TABLES

Figure 1. Still frame of anatomy video demonstrating annotations. (a) Perineal anatomy (insertion of an artificial urinary sphincter placement). (b) Testicular anatomy (scrotal orchidopexy for acute testicular torsion). (c) Prostate anatomy (robot-assisted laparoscopic prostatectomy). (d) Bladder anatomy (cystoscopy).

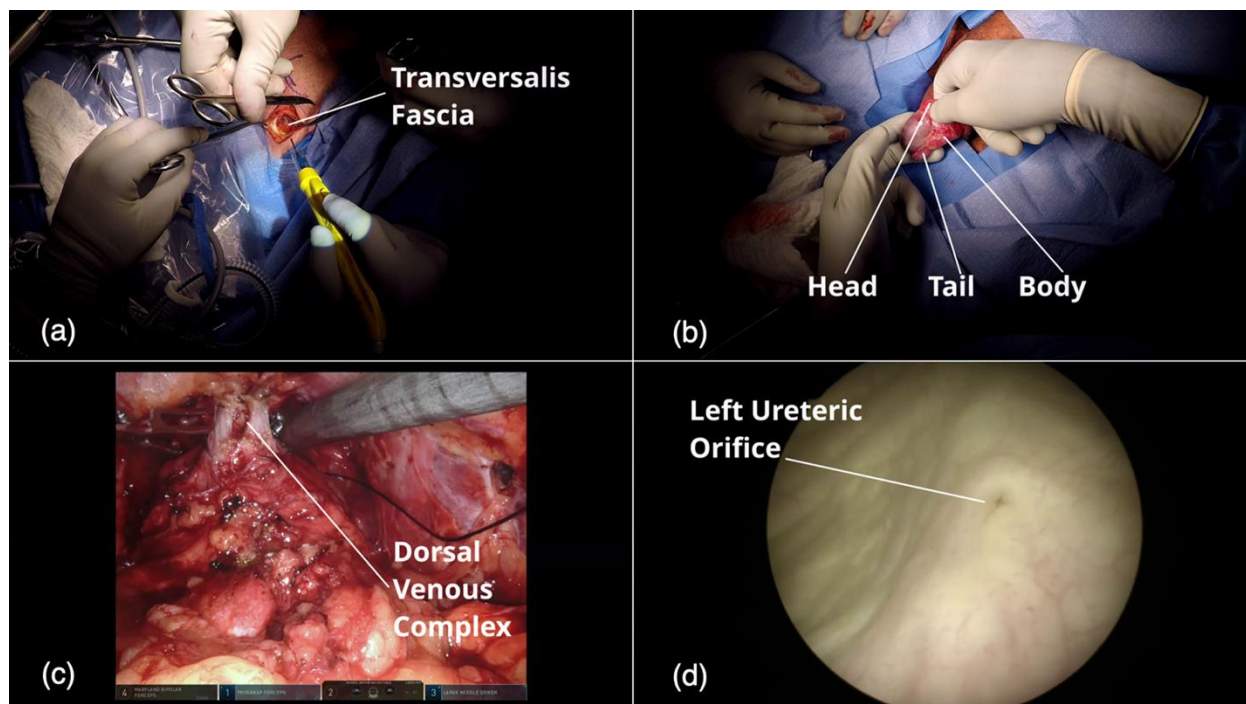


Figure 2. Results of survey given to participants following video and quizzes.

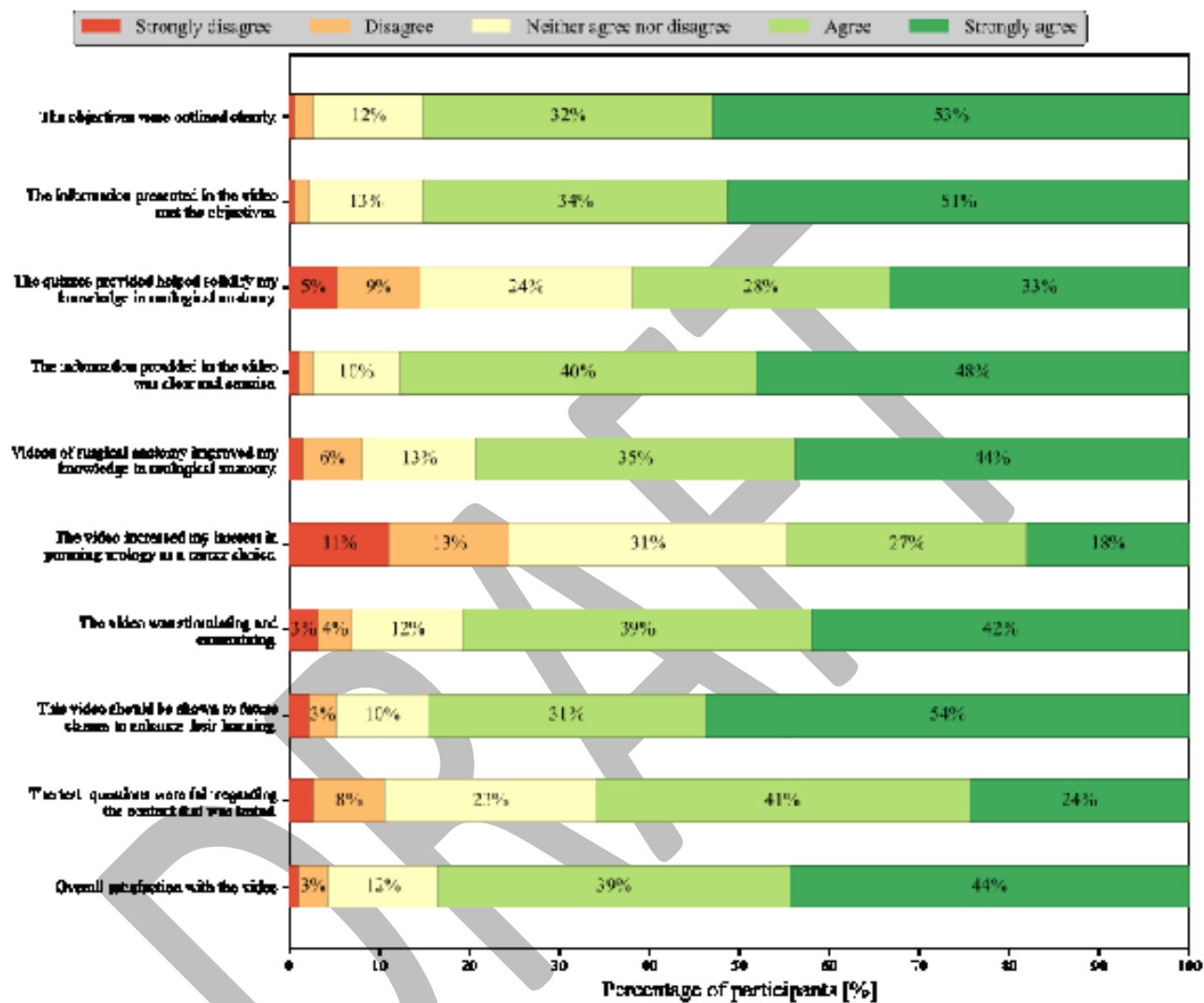


Table 1. Objectives provided to participants prior to screening of surgical anatomy video	
Objectives	
1.	Increase your knowledge of the following:
a.	Perineal anatomy
b.	Inguinal and testicular anatomy
c.	Prostate anatomy
d.	Bladder anatomy
2.	Increase your interest in urology as a career.

Table 2. Results of knowledge retention quizzes. Separated by year of administration and analyzed combined			
Cohort	Pre-quiz score (%)	Post-quiz score (%)	p
2021 (n=37)	46±18	49±17	0.30
2022 (n=76)	51±14	51±15	0.85
2023 (n=78)	51±17	48±18	0.11
Combined (N=191)	50±16	49±17	0.51