

Point-of-care ultrasound

Usage and accuracy within a Canadian urology division

Aaron P. van der Leek¹, Peter Metcalfe²

¹Faculty of Medicine, University of Alberta, Edmonton, AB, Canada; ²Division of Pediatric Surgery, Department of Surgery, University of Alberta, Stollery Children's Hospital, Edmonton, AB, Canada

Cite as: van der Leek AP, Metcalfe P. POCUS: Usage and accuracy within a Canadian urology division. *Can Urol Assoc J* 2024;18(2):48-54. <http://dx.doi.org/10.5489/cuaj.8513>

Published online October 23, 2023

Appendix available at cuaj.ca

ABSTRACT

INTRODUCTION: This research evaluates the utility and precision of point-of-care ultrasound (POCUS) in urology, inspired by recent affirmations of its feasibility and value.^{1,2} Our study provides valuable insights for urologists about POCUS's practical usage.

METHODS: A prospective study assessed POCUS usage and accuracy in the University of Alberta's Division of Urology using data from April 4, 2022, to April 4, 2023. Data include POCUS indications, findings, and correlation with the final diagnosis/gold standard. Additionally, a qualitative survey was conducted among urologists and residents about POCUS's pros, cons, and barriers to integration.

RESULTS: Thirty-three patients underwent POCUS examinations, mainly for suspected hydronephrosis (27%, n=9). Other indications included urinary retention, testicular mass, torsion, cryptorchidism, renal mass, extended focused assessment with sonography in trauma (eFAST) exams, nephrostomy tube placement confirmation, and scrotal hematomas. POCUS findings matched the final diagnosis in most cases, showing 86% sensitivity, with an average exam time of 1–5 minutes. POCUS showed potential for suprapubic tube insertions. Residents (60%, n=20) were the most frequent users, followed by staff (33%, n=10), and students (6%, n=2). The surveyed urologists and residents expressed comfort with POCUS but cited time, cost, and practicality as barriers.

CONCLUSIONS: POCUS proves accurate and beneficial in urology, particularly for hydronephrosis. Most findings align with the gold standard, and the average exam time is brief. Barriers include time and cost. Further research is necessary to evaluate cost-effectiveness and POCUS's impact on patient outcomes in routine urologic practice.

INTRODUCTION

Point-of-care ultrasound (POCUS) is gaining popularity in medicine due to its real-time, non-invasive, cost-effective, and rapid bedside imaging and diagnosis capabilities. POCUS has proven effective in diagnosing and managing various urologic conditions, including bladder and renal stones, hydronephrosis, prostate cancer, and testicular torsion.¹⁻⁴ Moreover, POCUS can also be employed for procedural purposes, such as the placement of suprapubic tubes and percutaneous nephrostomy tubes, as well as confirmation of Foley catheter placement.⁵⁻⁸ Several studies have underscored the benefits of POCUS in urology, including its high sensitivity and specificity for diagnosing ureteral stones, hydronephrosis, and testicular torsion. Recent research has also shown that POCUS exhibits high sensitivity and specificity for diagnosing renal tract obstruction, comparable to diagnostic ultrasound or computed tomography (CT) scans.^{9,10}

Despite the potential benefits, the integration of POCUS into urology practice and residency training programs still needs to be completed, with usage rates in Canada significantly lower than those in the U.S. A study by Alexandra et al noted that 43% of U.S. urologists perform non-prostate ultrasound examinations for their patients.¹¹ Given its potential advantages, appropriate exposure and training in POCUS during residency are vital to ensuring safe and effective usage in diagnosing and managing urologic conditions. A deeper understanding of POCUS

KEY MESSAGES

- POCUS shows great potential for diagnosis and management in urology but is underused in residency training.
- Our study reveals low POCUS uptake, with kidney indications being the most common indications.
- Major barriers to POCUS adoption include lack of time, knowledge, and formal training, as well as high cost.
- Despite its limitations, POCUS has the potential to improve patient outcomes and reduce healthcare costs if integrated into training programs and adopted more widely.

indications and uses in urology could benefit patients and healthcare providers alike; however, the absence of formal Canadian guidelines for POCUS usage in urology and the potential adverse outcomes associated with POCUS usage in untrained hands is a cause for concern, as the Canadian Radiology and Emergency associations have cautioned. Fortunately, colleagues at McMaster have developed and demonstrated the effectiveness of POCUS training in their urology residency program.¹²

Our paper aimed to evaluate the efficacy, usage rates, and indications of POCUS in urology residents. We conducted a prospective cohort study involving urology residents and staff who have previously received POCUS training and evaluated their usage of POCUS over 12 months.

METHODS

Study design and data collection methodology

We conducted a one-year, prospective, observational study to investigate the use of POCUS among urology residents, medical students, and staff at the University of Alberta. We used four POCUS machines from Clarius (two curvilinear, two linear) and ensured that residents and staff were familiarized with the hardware and software (Figure 1). A self-reported POCUS usage survey was accessible via a QR code on all POCUS machines. All urology residents and staff at the University of

Alberta Hospital were included in the study. The study location boasts many participants, including 14 residents and 22 staff.

Data collection and survey variables

We collected data through the self-reported POCUS usage survey (Appendix; available at cuaj.ca) over 12 months (Table 1). This included demographic information, such as the date, location of the exam (ward, intensive care unit [ICU], operating room [OR], emergency department [ED]), body part examined (testicle, bladder, kidney, abdomen), indication for the exam, the confirmatory study completed, length of the exam (<1 min, 1–5 min, >10 min), who performed the exam (residents, faculty, medical students), as well as perceived benefits and limitations of POCUS in urology.

To ensure data accuracy, we conducted regular quality checks and reconciliations to eliminate errors and inconsistencies. When indications or outcomes for POCUS usage were unclear, we reached out to the survey respondents individually for clarification. We used descriptive statistics to summarize the data. These were completed using Excel v16.70. The sensitivity for POCUS was also calculated separately and as an overall measure for all urologic indications recorded in the study and their agreement with the gold-standard exam.

Qualitative feedback component and thematic analysis

The qualitative feedback component of the study involved data collection via an open-ended email sur-



Figure 1. Example curvilinear point-of-care ultrasound adapted from clarius.com.

Table 1. POCUS usage, indications, location of use, and followup examinations by training level

| | Total (N) | Urology staff (n) | % of total (n=33) | Urology resident (n) | % of total (n=33) | Medical student (n) | % of total (n=33) |
|--------------------------------------|-----------|-------------------|-------------------|----------------------|-------------------|---------------------|-------------------|
| Indication for POCUS | | | | | | | |
| Testicular torsion | 4 | 2 | 6 | 2 | 6 | 0 | 0 |
| Testicular mass | 4 | 0 | 0 | 4 | 12 | 0 | 0 |
| Cryptorchidism | 3 | 3 | 9 | 0 | 0 | 0 | 0 |
| Scrotal hematoma | 1 | 0 | 0 | 1 | 3 | 0 | 0 |
| Urinary retention | 5 | 2 | 6 | 3 | 9 | 0 | 0 |
| Hydronephrosis | 9 | 3 | 9 | 4 | 12 | 2 | 6 |
| Kidney stones | 3 | 0 | 0 | 3 | 9 | 0 | 0 |
| Renal mass | 3 | 1 | 3 | 2 | 6 | 0 | 0 |
| eFAST | 1 | 0 | 0 | 1 | 3 | 0 | 0 |
| Time to perform exam | | | | | | | |
| <1 minute | 10 | 4 | 12 | 6 | 18 | 0 | 0 |
| 1-5 minutes | 16 | 6 | 18 | 9 | 27 | 1 | 3 |
| 5-10 minutes | 7 | 1 | 3 | 5 | 15 | 1 | 3 |
| Followup exam | | | | | | | |
| Bladder scan | 4 | 2 | 6 | 2 | 6 | 0 | 0 |
| CT | 5 | 0 | 0 | 5 | 15 | 0 | 0 |
| Surgical exploration | 10 | 5 | 15 | 5 | 15 | 0 | 0 |
| Consultative diagnostic ultrasound | 9 | 3 | 9 | 4 | 12 | 2 | 6 |
| None | 3 | 1 | 3 | 2 | 6 | 0 | 0 |
| Pending at time of survey completion | 2 | 0 | 0 | 2 | 6 | 0 | 0 |
| Location of POCUS use | | | | | | | |
| Clinic | 7 | 3 | 9 | 4 | 12 | 0 | 0 |
| ED | 4 | 1 | 3 | 3 | 9 | 0 | 0 |
| Ward | 14 | 3 | 9 | 9 | 27 | 2 | 6 |
| OR | 8 | 4 | 12 | 4 | 12 | 0 | 0 |

CT: computer tomography; ED: emergency department; eFAST: extended focused assessment with sonography in trauma; OR: operating room; POCUS: point-of-care ultrasound.

vey and informal conversations with participants during routine interactions in the workplace on experiences with POCUS technology. The survey sought to identify barriers to the technology uptake, suggestions for improving its usability and effectiveness, and any thoughts, concerns, and suggestions regarding the technology. Questions to illicit feedback included: What are the primary challenges or obstacles you've faced when

trying to adopt or use POCUS? How can we enhance the usability and effectiveness of POCUS in urology based on your personal experience? Can you share your overall impressions, concerns, and any recommendations you might have about POCUS?

We recruited a total of 25 participants. Data collected from the email survey and informal conversations were transcribed and analyzed using thematic analysis.

Open coding was used to break down the data into smaller, more manageable chunks. These chunks were labelled with codes, organized into categories to identify common themes across the data, and presented in a flow diagram.

The current investigation employed a comprehensive data collection methodology to gather quantitative and qualitative data using urology's POCUS technology. This approach was intended to provide a comprehensive understanding of the various factors that may influence the usage of POCUS in urology and provide insights into strategies that can be employed to improve adoption and effective treatment.

Ethical considerations and confidentiality

The local ethics committee approved the study, and all participants provided informed consent before participating. The confidentiality and anonymity of the participants were maintained throughout the data collection and analysis process. Ethical approval was obtained from the Health Ethics Research Board (Pro00120521).

RESULTS

Participant demographics and POCUS training and cost

Of the 33 records retrieved, POCUS was used, on average, 2.75 times per month, with kidney indications having the highest frequency of use (mean 2.2 times per month). The curvilinear probe (n=25) was the most used, followed by the linear probe (n=8). All participants received some form of POCUS training (both formal and informal) before use, with urology residents receiving the most extensive training overall from a formally trained staff during academic half-days.

POCUS usage and indications and agreement with gold-standard followup

The present study investigated the use of POCUS in urologic indications over 12 months, retrieving 33 records. The most frequent indications for POCUS use were kidney (45%), scrotal (36%), and bladder (15%) concerns, with only a minority of cases (3%) being related to other indications, such as the extended focused assessment with sonography in trauma (eFAST) (Figure 2, Table 1). Within bladder indications, urinary retention was the sole indication observed. Scrotal concerns were most related to testicular torsion and mass, and POCUS was used for preoperative planning in 100% of cases related to cryptorchidism. Kidney indi-

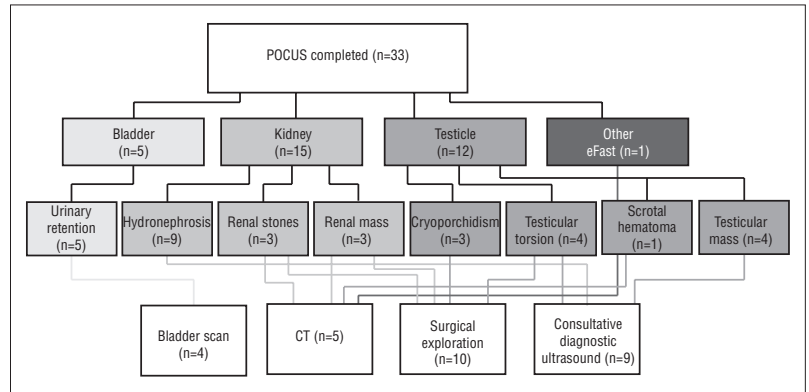


Figure 2. Flow diagram of point-of-care ultrasound (POCUS) study results (n=33), indications and followup are shown by colored symbols representing bladder, kidney, testicle, and other concerns. Followup exams are represented in gold. POCUS was solely used for preoperative planning in cryptorchidism. CT: computed tomography.

| | Sent for confirmatory exam (n) | Agreement with confirmatory exam (n) | Sensitivity (%) |
|-----------------------------|--------------------------------|--------------------------------------|-----------------|
| Indication for POCUS | | | |
| Testicular torsion | 4 | 3 | 75 |
| Testicular mass | 4 | 4 | 100 |
| Cryptorchidism | 3 | 3 | 100 |
| Scrotal hematoma | 1 | 1 | 100 |
| Urinary retention | 4 | 4 | 100 |
| Hydronephrosis | 5 | 3 | 60 |
| Kidney stones | 3 | 2 | 67 |
| Renal mass | 3 | 3 | 100 |
| eFAST | 1 | 1 | 100 |
| Total | 28 | 24 | 86 |

POCUS: point-of-care ultrasound.

cations included hydronephrosis (n=9), kidney stones (n=3), and renal mass (n=3). Gold-standard followup was completed in 28 cases, with surgical exploration (n=10) and consultative diagnostic ultrasound (n=9) being the most common confirmatory exams (Figure 2, Table 1).

The results demonstrated that POCUS agreed with the gold-standard followup in the majority of cases, indicating a sensitivity of 85.7% for general urological indications (Table 2). Individual specificities for each urologic indication are also provided in Table 2; however, followup data beyond the gold standard, such as

patient outcomes or satisfaction with using POCUS, were not available for this study. POCUS use in urologic indications was observed in various locations, with the majority of cases occurring in the urology ward (n=14), OR (n=8), pediatric/adult clinic (n=7), or ED (n=4).

POCUS users and time to perform the exam

Our analysis of the data revealed that usage of POCUS was primarily residents (Figure 3, Table 1), with bladder and kidney concerns being predominantly addressed by residents. Urology residents had the highest usage rate at 61% (n=20), while staff and medical students constituted 33% and 6% of the users, respectively. Figure 4 displays the frequency of POCUS performance duration, with the most common time being 1–5 minutes (48%).

Informal qualitative feedback: Barriers to adoption of POCUS technology

The thematic analysis of the informal qualitative feedback revealed several key themes related to the barriers to POCUS technology uptake (Figure 5). These significant barriers to adoption included more time, cost, knowledge/training, and usability. One participant stated, “It’s difficult to use POCUS during busy call shifts,” and “I often forgot to fill out the survey.” Utility was also sometimes called into question when “there’s a need for a consultation anyway,” and as another participant noted, “The usability for common urologic procedures and bladder scanning is worse than the readily available carts.” Lack of knowledge and formal training were also identified as essential barriers: “There is still a lack of formal training for urologists, and I don’t feel comfortable using it and diagnosing acute issues.” Additionally, the cost was mentioned as a concern, with some users worried about losing the expensive machines during their busy call shifts.

Many participants cited hopes of using the POCUS machines for procedural indications, such as suprapubic tube insertion, ward-based placement of percutaneous nephrostomy tubes, and confirmation of hydrophilic guidewire placement before catheter insertion; however, as one participant noted, “Although using these [ultrasound probes] for procedures sounds great in theory, the carts feel more practical because the screen is larger, you don’t have to hold it up while doing the procedure, and the carts are a workstation and contain some of the supplies I need.” While the sample size for this feedback was relatively small (n=15), these themes provide valuable insights into the barriers to adopting

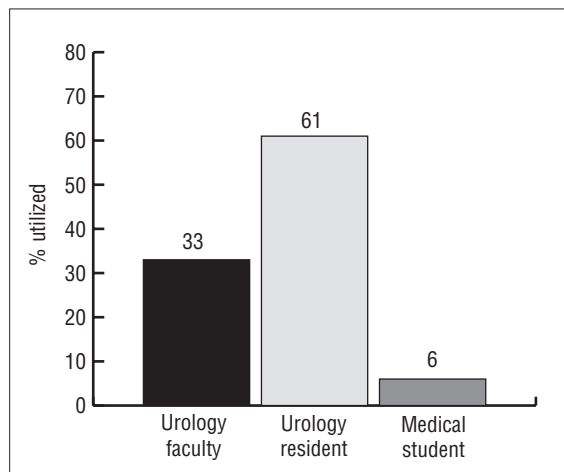


Figure 3. Usage of point-of-care ultrasound by training level.

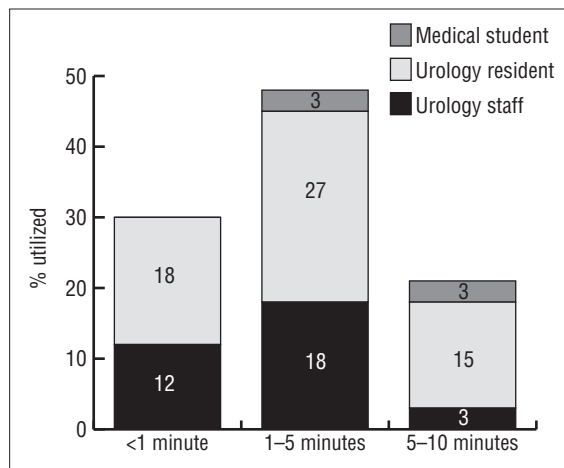


Figure 4. Duration of point-of-care ultrasound examination by training level.

POCUS technology and highlight areas for improvement in training, usability, and cost-effectiveness.

DISCUSSION

POCUS has gained immense popularity in medicine due to its real-time imaging capabilities, non-invasiveness, cost-effectiveness, and speed. Despite its potential benefits, Urology residents’ training has yet to integrate this valuable diagnostic tool fully. Consequently, we conducted a one-year, prospective, observational study at the University of Alberta Hospital to assess the efficacy, usage rates, and indications of POCUS in urology residents and staff.

Our study employed a self-reported POCUS usage survey, readily accessible via a QR code, placed on all POCUS machines. The survey results indicated that POCUS had low overall uptake rates and was used, on average, 2.75 times monthly. The curvilinear probe

was the most commonly used, followed by the linear probe. Furthermore, kidney indications had the highest frequency of use, followed by scrotal concerns.

Our results also demonstrated that POCUS agreed with the gold-standard followup in 86% of cases —findings consistent with previous reports.^{9,10} We concede that there are inherent limitations in amalgamating sensitivity data for POCUS and predicting specificity across multiple urologic indications. Given our constrained sample size, conducting a comprehensive subanalysis for each indication was not feasible, and the population needs to be more balanced towards positive results, making it inappropriate to calculate specificity. We advocate for further investigations with augmented sample sizes to elucidate the diagnostic efficacy for each specific indication.

Our qualitative analysis revealed that lack of time, cost, and usability were significant barriers to POCUS adoption in urology. Participants expressed concerns regarding time pressure and utility, which impacted their survey use. Lack of knowledge and formal training were also identified as essential barriers.

Overall, our study highlights the need for improvement in training, usability, and cost-effectiveness to ensure the effective and safe usage of POCUS in the diagnosis and management of urologic conditions. Urology residents' training should integrate POCUS technology more extensively, and efforts should be made to address barriers to adoption to realize its full potential in clinical practice.

The potential of POCUS in Canadian urology: Why should we do it?

In urology, POCUS has demonstrated remarkable effectiveness in diagnosing and managing various urologic conditions, such as renal and bladder stones, hydronephrosis, prostate cancer, and testicular torsion.^{1-3,5-10,13} POCUS has also been highly useful for procedural applications, including placing percutaneous nephrostomy and suprapubic tubes and confirming the location of hydrophilic guidewires before catheter placement.^{6,8} Moreover, studies have shown that using POCUS by internal medicine colleagues has led to a reduction of five hours in treatment time for patients admitted to wards.¹⁴

Recent research further confirms the high sensitivity and specificity of POCUS for diagnosing renal tract obstruction, comparable to computed tomography or diagnostic ultrasound, resulting in cost savings and reduced treatment time compared to traditional ultrasound methods.¹⁵ In addition, POCUS has demonstrated

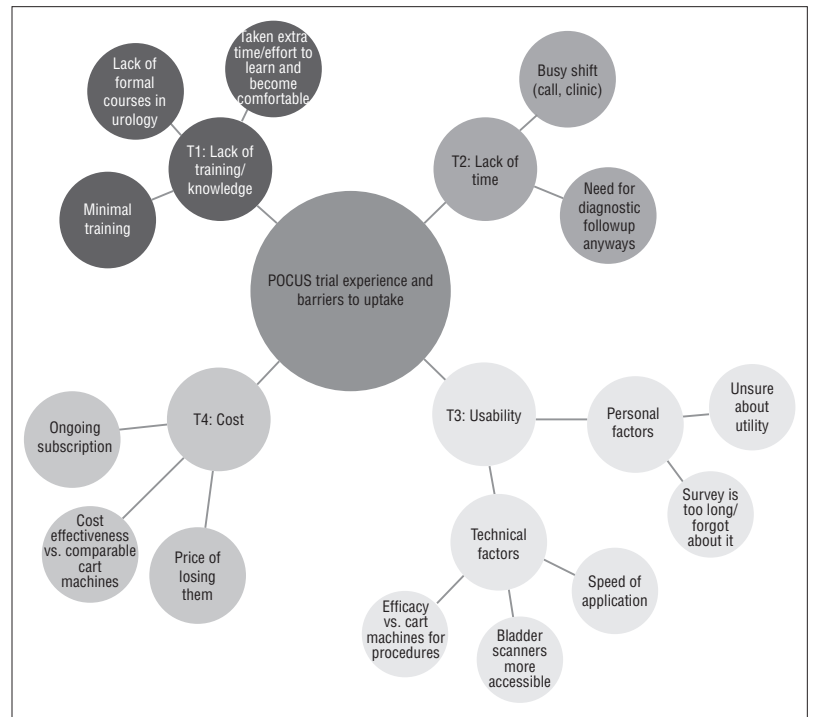


Figure 5. Thematic map illustrating point-of-care ultrasound trial experience and barriers to uptake through reflexive thematic analysis (n=15). Key themes, represented by various colors, branch outward from the central research question (T1 to T4) along with qualitative subthemes.

high accuracy in diagnosing ureteral stones and hydronephrosis in patients with acute renal colic, with sensitivity and specificity rates ranging from 94.6–100%.^{1,9,16,17} POCUS has also been found to be a valuable tool in diagnosing and managing testicular torsion and prostate cancer.¹² Studies have shown that POCUS training can significantly improve diagnostic accuracy and confidence among healthcare professionals in other specialties, such as emergency medicine and critical care.¹⁸⁻²⁰

Despite its benefits, the integration of POCUS into urology resident training programs still needs to be completed, and its usage rates in Canada are lower than those in the U.S.;^{11,12} however, studies have demonstrated the effective implementation of a guideline-based introductory POCUS program for Canadian urology residents, highlighting the need for appropriate training programs to ensure its effective and safe use in diagnosing and managing urologic conditions.¹²

Furthermore, patients have reported higher satisfaction levels when assessed by POCUS and believe it should be performed routinely.²¹ Addressing the barriers to the adoption of POCUS technology in urology, including lack of knowledge, formal training, time, cost, and usability concerns, can further advance the field of urology and provide better patient care. It is important

to also note that these barriers are not unique to our specialty.²²⁻²⁴

Limitations

Despite the valuable insights gained from this study, some limitations should be considered.

First, our study was conducted at a single center, and the findings may not be generalizable to other institutions or settings. Our study also relied on self-reported data, which may be subject to recall bias, social desirability bias, and non-response bias, as indicated by some participants — primarily residents. We also did not assess the quality of POCUS images or the level of expertise of those performing the exams. Whether the frequency of POCUS use reflects practical use or merely the volume of exams being performed remains to be seen. Lastly, our study's sample size was relatively small; therefore, longer-term studies with larger sample sizes are needed to evaluate the long-term use of POCUS on urology residents and staff and its impact on patient outcomes.

CONCLUSIONS

POCUS can improve patient outcomes and reduce healthcare costs significantly but is an underused tool in urology. Appropriate training programs and guidelines must be integrated to ensure the practical, safe use of POCUS in diagnosing and managing urologic conditions. Future efforts should also address the barriers to adopting this technology and improving patient care.

COMPETING INTERESTS: The authors do not report any competing personal or financial interests related to this work.

ACKNOWLEDGMENTS: The authors would like to acknowledge the Alberta Health Services Surgery Strategic Network for facilitation funding.

This paper has been peer-reviewed.

REFERENCES

- Friedman N, Pancer Z, Savic R, et al. Accuracy of point-of-care ultrasound by pediatric emergency physicians for testicular torsion. *J Pediatr Urol* 2019;15:608.e1-6. <https://doi.org/10.1016/j.jpuro.2019.07.003>
- Moussaoui G, Zakaria AS, Negrean C, et al. Accuracy of clarius, handheld wireless point-of-care ultrasound, in evaluating prostate morphology and volume compared to radical prostatectomy specimen weight: Is there a difference between transabdominal vs. transrectal approach? *J Endourol* 2021;35:1300-6. <https://doi.org/10.1089/end.2020.0874>
- Pathan SA, Mitra B, Mirza S, et al. Emergency physician interpretation of point-of-care ultrasound for identifying and grading of hydronephrosis in renal colic compared with consensus interpretation by emergency radiologists. *Acad Emerg Med* 2018;25:1129-37. <https://doi.org/10.1111/acem.13432>
- Lisciandro SC, Young S. POCUS: Urinary Bladder. In: Lisciandro GR (ed) *Point-of-Care Ultrasound Techniques for the Small Animal Practitioner*, Second Edition. John Wiley & Sons, Inc. <https://doi.org/10.1002/9781119461005.ch11>
- Wu WJ, Andreas D, Gilbert BR. (2021). Point-of-Care Ultrasound in Urology. In: Fulgham PF, Gilbert BR (eds) *Practical Urological Ultrasound*. Springer, Cham. https://doi.org/10.1007/978-3-030-52309-1_17
- Garagiano J, Madhok J. POCUS for visualization and facilitation of urinary catheter placement. *Pocus J* 2020;5:35-6. <https://doi.org/10.24908/pocus.v5i2.14431>
- McCafferty G, Shorette A, Singh S, et al. Emphysematous pyelonephritis: Bedside ultrasound diagnosis in the emergency department. *Clin Pract Cases Emerg Medicine* 2017;1:92-4. <https://doi.org/10.5811/cpcem.2016.12.32714>
- Salman LA, Reisinger N. POCUS allows for rapid elucidation of acute kidney injury in a patient with progressive multiple myeloma. *Pocus J* 2022;7:24-6. <https://doi.org/10.24908/pocus.v7i1Kidney.15342>
- Sibley S, Roth N, Scott C, et al. Point-of-care ultrasound for the detection of hydronephrosis in emergency department patients with suspected renal colic. *Ultrasound J* 2020;12:31. <https://doi.org/10.1186/s13089-020-00178-3>
- Nepal S, Dachsel M, Smallwood N. Point-of-care ultrasound rapidly and reliably diagnoses renal tract obstruction in patients admitted with acute kidney injury. *Clin Med* 2020;20:541-4. <https://doi.org/10.7861/clinmed.2019-0417>
- Rehfuß A, Nakada S, Pearle MS, et al. Use of non-prostate ultrasound in urology practice. *Urology Pract* 2017;4:430-5. <https://doi.org/10.1016/j.urpr.2016.09.009>
- Uy M, Lovatt CA, Hoogenes J, et al. Point-of-care ultrasound in urology: Design and evaluation of a feasible introductory training program for Canadian residents. *Can Urol Assoc J* 2020;15:E210-4. <https://doi.org/10.5489/cuaj.6637>
- Lien W-C, Chang C-H, Chang K-M, et al. Clinical utilization of point-of-care ultrasound by junior emergency medicine residents. *Med Ultrason* 2022;24:270-6. <https://doi.org/10.11152/mu-3425>
- Golan YB-B, Sadeh R, Mizrakli Y, et al. Early point-of-care ultrasound assessment for medical patients reduces time to appropriate treatment: A pilot randomized controlled trial. *Ultrasound Med Biol* 2020;46:1908-15. <https://doi.org/10.1016/j.ultrasmedbio.2020.03.023>
- Villanueva J, Pifer B, Colaco M, et al. Point-of-care ultrasound is an accurate, time-saving, and cost-effective modality for postoperative imaging after pyeloplasty. *J Pediatr Urol* 2020;16:472.e1-472.e6. <https://doi.org/10.1016/j.jpuro.2020.05.156>
- Kim SG, Jo IJ, Kim T, et al. Usefulness of protocolized point-of-care ultrasonography for patients with acute renal colic who visited emergency department: A randomized controlled study. *Medicina* 2019;55:717. <https://doi.org/10.3390/medicina55110717>
- Wong C, Teitge B, Ross M, et al. The accuracy and prognostic value of point-of-care ultrasound for nephrolithiasis in the emergency department: A systematic review and meta-analysis. *Acad Emerg Med* 2018;25:684-98. <https://doi.org/10.1111/acem.13388>
- Kotagal M, Quiroga E, Ruffatto BJ, et al. Impact of point-of-care ultrasound training on surgical residents' confidence. *J Surg Educ* 2015;72:e82-7. <https://doi.org/10.1016/j.jsurg.2015.01.021>
- Hannula O, Hällberg V, Meuronen A, et al. Self-reported skills and self-confidence in point-of-care ultrasound: A cross-sectional nationwide survey amongst Finnish emergency physicians. *BMC Emerg Med* 2023;23:23. <https://doi.org/10.1186/s12873-023-00795-w>
- Kern J, Scarpulla M, Finch C, et al. The assessment of point-of-care-ultrasound (POCUS) in acute care settings is benefitted by early medical school integration and fellowship training. *J Osteopath Med* 2022;123:65-72. <https://doi.org/10.1515/jom-2021-0273>
- Andersen CA, Brodersen J, Rudbæk TR, et al. Patients' experiences of the use of point-of-care ultrasound in general practice - a cross-sectional study. *Bmc Fam Pract* 2021;22:116. <https://doi.org/10.1186/s12875-021-01459-z>
- Wong J, Montague S, Wallace P, et al. Barriers to learning and using point-of-care ultrasound: a survey of practicing internists in six North American institutions. *Ultrasound J* 2020;12:19. <https://doi.org/10.1186/s13089-020-00167-6>
- Micks T, Sue K, Rogers P. Barriers to point-of-care ultrasound use in rural emergency departments. *CJEM* 2016;18:475-9. <https://doi.org/10.1017/cem.2016.337>
- Woo MY, Frank JR, Lee AC. Point-of-care ultrasonography adoption in Canada: Using diffusion theory and the Evaluation Tool for Ultrasound skills Development and Education (ETUDE). *CJEM* 2014;16:345-51. <https://doi.org/10.2310/8000.2013.131243>

CORRESPONDENCE: Dr. Peter Metcalfe, Division of Pediatric Surgery, Department of Surgery, University of Alberta, Stollery Children's Hospital, Edmonton, AB, Canada; pmetcal@ualberta.ca