

**Robotic-assisted laparoscopic pyeloplasty for ureteropelvic junction obstruction:
A retrospective review of a high-volume Canadian center**

Michael Ordon^{1,2}, Aren Mnatzakanian³, Melody Djuimo¹, R. John D'A Honey,^{1,2} Jason Y. Lee^{2,4}
¹Division of Urology, Department of Surgery, St. Michael's Hospital, Toronto, ON, Canada; ²Division of Urology, Department of Surgery, Temerty Faculty of Medicine, University of Toronto, Toronto, ON, Canada; ³UCD School of Medicine, University College Dublin, Belfield, Dublin, Ireland; ⁴Division of Urology, Department of Surgery, University Health Network, Toronto, ON, Canada

Cite as: Ordon M, Mnatzakanian A, Djuimo M, et al. Robotic-assisted laparoscopic pyeloplasty for ureteropelvic junction obstruction: A retrospective review of a high-volume Canadian center. *Can Urol Assoc J* 2023 November 20; Epub ahead of print. <http://dx.doi.org/10.5489/cuaj.8507>

Published online November 20, 2023

Corresponding author: Dr. Michael Ordon, Division of Urology, St. Michael's Hospital, University of Toronto, Toronto, ON, Canada; Michael.ordon@utoronto.ca

ABSTRACT

Introduction: At present, there is no literature on the outcomes of robotic-assisted laparoscopic pyeloplasty (RALPyelo) in a Canadian context. Our objective was to perform a retrospective review of RALPyelo cases at a high-volume Canadian center.

Methods: We performed a retrospective review of patients that underwent RALPyelo at St. Michael's Hospital, between January 2012 and May 2019.

Demographics, operative details, and pre- and postoperative imaging results (ultrasounds, computed tomography [CT] scans, and diuretic renal scan [DRS]) were recorded. Patients were excluded if at least one year' followup data was unavailable. Our primary outcome was clinical and radiologic improvement defined as 1) symptom improvement; 2) stable/improved split renal function on DRS; and 3) either improvement in the degree of hydronephrosis on ultrasound or CT, or improved drainage time on DRS. Secondary outcomes included postoperative complications, need for diagnostic intervention, and reintervention for recurrent UPJO.

Results: A total of 156 patients underwent RALPyelo after exclusions. The median age was 42 and 66% were female. Mean followup was 2.5 years. For our primary outcome, 87% had clinical and radiologic improvement. Diagnostic investigation for possible recurrent/persistent

KEY MESSAGES

- This is the first reported Canadian series of robotic-assisted laparoscopic pyeloplasty for UPJO from a high-volume center.
- The review demonstrates the safety and high success rate of robotic pyeloplasty for UPJO.

obstruction, based on symptoms and/or imaging results, was required in 17% of cases, but only 3% required reintervention for recurrent UPJO. Accordingly, the overall treatment success was 97%. The most common postoperative complication was UTI (18%), and urine leak was seen in only 2% of patients.

Conclusions: The results of our study compare favorably with currently reported outcomes in the literature and demonstrate the safety and high level of success of RALPyelo at a high-volume Canadian center.

INTRODUCTION

Ureteropelvic junction obstruction (UPJO) is a relatively common urologic condition where either an extrinsic or intrinsic compression at the junction between the renal pelvis and proximal ureter impedes urine flow. UPJO is predominantly a congenital condition observed in the pediatric population and affects 1 in every 1000-2000 live births with an equal male to female ratio¹. Within the adult age group, UPJO has an overall incidence of 1 in 1500¹.

The indications for treatment of UPJO include recurrent episodes of pain, the formation of renal calculi, recurrent urinary tract infections (UTIs), and complete or partial loss of ipsilateral renal function. Treatment options include conservative measures such as chronic nephrostomy tube or ureteric stenting, that require routine exchanges, versus surgical intervention with either retrograde or antegrade endopyelotomy and pyeloplasty. Pyeloplasty offer the highest chance for success as compared to endopyelotomy^{2,3}.

Different approaches can be utilized to perform a pyeloplasty, including open, laparoscopic and robotic assisted laparoscopic³. Each approach comes with its benefits and drawbacks depending on various patient factors and surgeons' preferences and skill. Robotic assisted laparoscopic pyeloplasty (RALPyelo) offers advantages of minimally invasive surgery to the patient (less post-operative pain, faster recovery and minimal scarring), as well as distinct technical advantages to the surgeon (better ergonomics, enhanced dexterity, greater precision). RALPyelo, using the da Vinci[®] system (Intuitive Surgical, USA) was first introduced by Sung and colleagues in an experimental setting in 1999⁴ and the clinical feasibility of the procedure was confirmed by Palese et al.⁵ in 2005 and Mufarrij et al.⁶ in 2007.

At present, there is no literature on the outcomes of RALPyelo in a Canadian context. Accordingly, the objective of our study is to report the first Canadian experience with RALPyelo based on data from a single high volume Canadian centre and highlight our unique modification for suturing the anastomosis that minimizes handling of the ureter at its most critical location near the apex.

METHODS

Study design

We performed a single institution retrospective cohort study of all patients undergoing a RALPyelo at St. Michael's Hospital. St. Michael's Hospital is a tertiary care hospital in Toronto, Ontario, Canada, servicing the greater Toronto area and surrounding communities with a population of over 7 million. St. Michael's Hospital was the only centre in the region performing RALPyelo during the study time frame. We conducted this study according to a pre-specified protocol that was approved by the Institutional Review Board at St. Michael's Hospital. Reporting of this study follows the STROBE guidelines set for observational studies⁷.

Study population

We identified all patients who had undergone an upper tract robotic assisted laparoscopic reconstructive procedure at St. Michael's Hospital using a master log of all robotic cases. We included all patients who underwent a RALPyelo between January 2012 and May 2019. Patients were excluded if they underwent an upper ureteric reconstruction (i.e., ureteroureterostomy), if they did not have at least 1 year of follow-up post pyeloplasty, or if their records were otherwise incomplete from the electronic medical record at the hospital.

Using our Electronic Medical Record (EMR) a detailed chart review was performed to extract all demographic, pre-operative and post-operative clinic details and operative findings. Demographics included age, gender, height, weight, body mass index and past medical and surgical history. Pre-operative clinic details included symptom status and results from imaging studies (i.e., ultrasound, CT scans, and diuretic renal scans (DRS)). Operative findings included side of surgery, presence of crossing vessel, concomitant removal of stones, duration of surgery, estimated blood loss along with other details. Post-operative details included symptom status, length of stay, results from imaging studies (i.e., ultrasound, CT scans, and DRS). and complications.

Importantly, presence of symptoms pre- and post-operatively was determined based careful review of the clinical notes EMR and not using a validated pain questionnaire.

Surgical technique

All patients without a pre-existing stent in place either had a stent placed retrograde in advance of, or at the start of the procedure under fluoroscopic guidance, or had a stent placed antegrade during the RALPyelo.

Once all ports were in place the colon and its mesentery were adequately mobilized and medialized. The proximal ureter was then identified lateral to the gonadal vein. The ureter was encircled and traced up towards the UPJ. Care was taken to maintain a good amount of peri-ureteral tissue to ensure vascularity. The UPJ was completely dissected out and the renal pelvis was cleared and mobilized to allow adequate exposure for a dismembered pyeloplasty. In cases with a crossing vessel the vessels were preserved, encircled, and completely dissected free from

the ureter/UPJ below. Small (5mm) polymer locking clips were often placed to temporarily tack the peri-nephric tissues laterally to help improve exposure. These clips were removed at the end of the case.

Next, the renal pelvis was incised sharply on its medial surface superior to the UPJ. This provides a handle of renal pelvis on the transected ureter that can help to manipulate the ureter in a no-touch technique. The incision is carried laterally to the level of the UPJ. In cases with crossing vessels the ureter is passed anterior to the vessels at this point. The ureter is then spatulated along its lateral surface for approximately 2 cm or until the area of narrowing has been completely incised.

The spatulated proximal ureter was then anastomosed to the cut edge of the renal pelvis in a running continuous fashion using two 4-0 PDS sutures. Our unique *offset-from-the-apex technique* was employed placing the posterior wall suture first about 1-2 cm from the apex (Figure 1). This suture was tied down and run continuously away from the apex of the spatulation. Once the posterior wall was complete, the anterior wall suture was placed next to the posterior wall suture and situated closer to the apex (Figure 1). The suture was tied down and then the apical sutures, which are the most critical of the anastomosis could be placed with the upmost precision and using a no-touch technique, as the ureter is held clearly in place by the completed offset posterior and anterior wall sutures. Minimizing handling near the apex and having precisely placed sutures at this location is critical to preventing recurrent stenosis.

In some cases, the ureteral handle of excess renal pelvis was excised prior to completing the anastomosis, but a standard reduction pyeloplasty technique was not employed for most cases. The anterior and posterior wall sutures were secured to one another, and the anastomosis was checked to be watertight.

Followup

The ureteric stent was typically left in place for 4-6 weeks post-operatively and removed via cystoscopy under local anesthetic. All patients were followed post-operatively with renal ultrasound and diuretic renography (diuretic renal scan (DRS)) and occasionally computed tomography (CT) scans, as clinically indicated. The results of all post-operative DRS and ultrasounds completed at St. Michael's Hospital were recorded, including results at 6 weeks, 6 months, 1-year post pyeloplasty, as well as 2-year and 3-year post pyeloplasty, if available.

Cystoscopy and retrograde pyelogram +/- diagnostic ureteroscopy were utilized to evaluate patients with either abnormal post-operative imaging (i.e., reduced split function compared to pre-op DRS, no improvement or worsened T½ drainage time, worsened hydronephrosis), persistent symptoms or both.

Outcomes

Our primary outcome was clinical and radiologic improvement defined as: (1) symptom improvement, (2) stable/improved ipsilateral split renal function on DRS and (3) either improvement in the degree of hydronephrosis on ultrasound or CT, or improved T½ drainage

time on DRS. The primary outcome was defined on the most recently completely imaging and clinical assessment of symptoms. The mean time and standard deviation (SD) to the last ultrasound and/or DRS scan along with follow-up visit was reported.

For patients who were asymptomatic, or their symptom status was undefined pre-operatively they were recorded as having symptom improvement if they remained asymptomatic post-operatively and had no signs of persistent/recurrent obstruction on post-operative ultrasound and DRS.

Secondary outcomes included: (1) post-operative complications (e.g., urine leak, bleeding requiring blood transfusion, wound infection, bowel injury, conversion to open and urinary tract infection (UTI)), (2) need for diagnostic intervention (retrograde pyelogram or diagnostic ureteroscopy) to evaluate patients with either abnormal post-operative imaging, persistent symptoms, or both; and (3) reintervention for recurrent UPJO with either endopyelotomy, repeat pyeloplasty or nephrectomy.

Analysis

Categorical data is presented as frequencies and percentages. Continuous data is presented as median with interquartile range or as mean \pm standard deviation depending on the distribution of data.

RESULTS

A total of 188 patients underwent RALPyelo over the study time frame and after excluding patients with incomplete or missing 1 year follow-up data, our study cohort consisted of 156 patients. The median age was 42 and 66% were female (Table 1). Mean follow-up was 2.5 years (SD 1.7). Most patients were in good health with 71% being an ASA 1 or 2.

As might be expected there was almost an even split between right (54%) and left (46%) sided surgery. A crossing vessel was encountered as the cause for obstruction in 30% of cases and concurrent stone removal was performed in 9% of cases. Nine patients (6%) had a prior endopyelotomy and 4 patients (3%) had a prior pyeloplasty at another centre, 3 laparoscopic and one open.

Pre- and post-operative symptom status was defined in all cases reviewed except one that didn't document pre-operative symptom status.

In terms of our primary outcome, 87% had clinical and radiologic improvement. The vast majority (76%) had symptom improvement, stable or improved ipsilateral split renal function on DRS, improved hydronephrosis on ultrasound or CT and improved T $\frac{1}{2}$ drainage time on DRS. The breakdown of the number of patients satisfying each iteration of the composite primary outcome are listed in Table 2.

Of note, there was 21 patients who were asymptomatic pre-operatively. All 21 of these patients, as well as the 1 patient with undefined pre-operative symptom status, were asymptomatic post-operatively. Furthermore, none of these of 22 patients had worsened hydronephrosis or deterioration in their split function to indicate recurrent obstruction

Diagnostic investigation for possible recurrent/persistent obstruction, based on symptoms and/or abnormal imaging results, was required in 26 (17%) of cases. However, only 5 of these patients (3%) required reintervention for recurrent UPJO. Accordingly, the overall treatment success was 97%, considering that diagnostic intervention showed no evidence of recurrent UPJ stricture in the remaining patients who required diagnostic investigation for abnormal imaging or symptoms. Of those requiring re-intervention, 4 patients underwent endopyelotomy, with one of these failing endopyelotomy and requiring a redo-RALPyelo. The remaining patient requiring re-intervention required a redo-RALPyelo, as the reconstructed UPJ was obliterated. Both patients who underwent a redo-RALPyelo had successful outcomes.

The most common post-operative complication was UTI (18%), and importantly urine leak was seen in only 2% of patients. One patient had a small bowel injury repaired intra-operatively with no subsequent sequelae. No patients had bleeding requiring blood transfusion and no patients required conversion to open.

DISCUSSION

Our single centre retrospective cohort study demonstrates a high success rate of RALPyelo with low risk for significant complications. Eighty-seven percent of patients had clinical and radiologic improvement and only 3% of patients required repeat intervention for recurrent stenosis and obstruction resulting in an overall success rate of 97%. This represents the first study reporting on a Canadian centre's outcomes for RALPyelo. It also highlights the excellent outcomes associated with our modified suturing technique that involves placement of the anastomotic sutures off-set from the apex of the spatulated ureter to facilitate precise placement of the critical apical sutures in a no-touch technique.

Results from our study compare favourably with those in the published literature. The most recently published series is from 2022 and reports the single institution experience with RALPyelo by Whiting et al⁸. This was a 10-year retrospective review of prospectively collected data on 160 patients (mean age 45.3±17.4) that underwent retroperitoneal (95%) or transperitoneal (5%) RALPyelo in a tertiary care hospital in the UK. They reported a success rate (i.e., symptom improvement and/or unobstructed renogram) of 94.5%. Mean operating time was 139.4±45.6 minutes. Median hospital stay was 1 night (range 1-27). Six major complications were reported (>grade 2 on Clavien-Dindo classification), including urine leak, pain after stent removal, migrating stent requiring ureteroscopy, perirenal hematoma requiring open evacuation, and stent re-insertion.

Similarly, a systematic review and meta-analysis by Autorino et al⁹ from 2014 showed a success rate of RALPyelo ranging from 81%-100% across 10 case series included in their review, with each series having at least 50 patients. The complication rate ranged from 1.8% to 17.9% and the mean length of hospital stay ranged from 1.1 to 4.6 days across the same 10 studies.

Results from our study also compare favourably to the only existing series in the literature from Canada that reports on minimally invasive pyeloplasty from McMaster University. They

reported on their initial experience in 2004¹⁰ and updated this in 2008¹¹. The updated series reported on their experience in 77 patients undergoing laparoscopic pyeloplasty with a mean follow-up of only 13 months¹¹. Our series demonstrated a shorter mean length of stay (2 vs. 3 days) and shorter mean operative time (178 vs. 218 minutes). Success rates were similar at 90.4% in the McMaster series versus 87% in the present study, however the longer follow up in the present study introduces the possibility that more cases of recurrent obstruction could have been identified over time.

Our study has several strengths including that it represents the first reported data in a Canadian context, while also being one of the largest reported series on RALPyelo with one of the longer mean follow-up data. We had complete and comprehensive pre- and intra-operative data available for all of the patients that underwent RALPyelo at St. Michael's Hospital during the study period, accessible through their electronic medical record. The vast majority (83%) of these patients had adequate post-operative follow-up data, including ultrasounds and DRS, allowing us to include them in our final cohort for assessing our primary and secondary outcomes. Our primary and secondary research outcomes were clearly articulated and clinically well-defined.

The results of our study must be viewed within the context of our study limitations. This is a single centre study and so the results may not be generalizable to other centres. This was a retrospective study and so it is theoretically at risk for selection bias, as those patients who were excluded because of lack of follow-up data could have had significantly different outcomes than the remainder of our cohort. However, as the only centre performing RALPyelo in the Greater Toronto Area and a tertiary referral centre seeing patients from Northern Ontario, the patients included in our study cohort did span the full range from the simplest to the most complex cases. In addition, symptom status pre-operatively and post-operatively was determined based on review of existing clinical notes and not using a formal validated pain questionnaire and as such this could limit the validity of this metric of our primary outcome.

Moving forward ongoing prospective collection of data on patients undergoing RALPyelo will provide more robust data on outcomes allowing for potential further refinement in technique and patient selection.

CONCLUSIONS

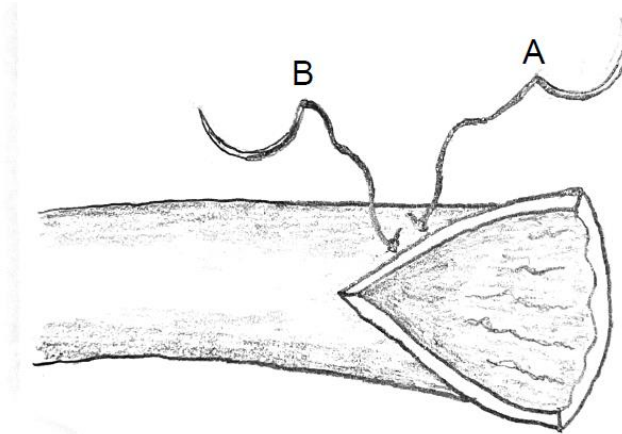
The results of our retrospective review compare favorably with currently reported outcomes in the literature and demonstrate the safety and high level of success of RALPyelo at a high-volume Canadian centre.

REFERENCES

1. Khan, F., Ahmed, K., Lee, N. et al. Management of ureteropelvic junction obstruction in adults. *Nat Rev Urol* 2014;11:629. <https://doi.org/10.1038/nrurol.2014.240>
2. Rassweiler, J. J., Subotic, S., Feist-Schwenk, M. et al. Minimally invasive treatment of ureteropelvic junction obstruction: Long-term experience with an algorithm for laser endopyelotomy and laparoscopic retroperitoneal pyeloplasty. *J Urol* 2007;177:1000. <https://doi.org/10.1016/j.juro.2006.10.049>
3. Uhlig, A., Uhlig, J., Trojan, L. et al. Surgical approaches for treatment of ureteropelvic junction obstruction - A systematic review and network meta-analysis. *BMC Urol* 2019;19:112. <https://doi.org/10.1186/s12894-019-0544-7>
4. Sung, G. T., Gill, I. S., Hsu, T. H. Robotic-assisted laparoscopic pyeloplasty: A pilot study. *Urology* 1999;53:1099. [https://doi.org/10.1016/S0090-4295\(99\)00030-8](https://doi.org/10.1016/S0090-4295(99)00030-8)
5. Palese, M. A., Munver, R., Phillips, C. K. et al. Robot-assisted laparoscopic dismembered pyeloplasty. *JSLs* 2005;9:252.
6. Mufarrij, P. W., Shah, O. D., Berger, A. D. et al. Robotic reconstruction of the upper urinary tract. *J Urol* 2007;178:2002. <https://doi.org/10.1016/j.juro.2007.07.018>
7. von Elm, E., Altman, D. G., Egger, M. et al. The Strengthening the reporting of observational studies in epidemiology (STROBE) statement: Guidelines for reporting observational studies. *J Clin Epidemiol* 2008;61:344. <https://doi.org/10.1016/j.jclinepi.2007.11.008>
8. Whiting, D., Whitehurst, L., Tsang, D. et al. Retroperitoneal robotic-assisted laparoscopic pyeloplasty: A 10 year experience in a single institution. *J Endourol* 2022;36:615 <https://doi.org/10.1089/end.2021.0551>
9. Autorino, R., Eden, C., El-Ghoneimi, A. et al. Robot-assisted and laparoscopic repair of ureteropelvic junction obstruction: A systematic review and meta-analysis. *Eur Urol* 2014;65:430. <https://doi.org/10.1016/j.eururo.2013.06.053>
10. Hussain, A., Whelan, P., Piercey, K. et al. McMaster experience with laparoscopic pyeloplasty. *Can J Urol* 2004;11:2299.
11. Dong, J., Wong, J., Al-Enezi, A. et al. Laparoscopic pyeloplasty: The updated McMaster University experience. *Can Urol Assoc J* 2008;2:388. <https://doi.org/10.5489/cuaj.806>

FIGURES AND TABLES

Figure 1. Spatulated proximal ureter with off-set apex sutures. (A) Posterior wall structure; (B) anterior wall suture.



Study sample	N=156
Median age at OR (IQR)	42 (28–58)
Gender (%)	
Male	53 (34)
Female	103 (66)
Mean BMI (SD)	25 (6)
ASA status (%)	
I	27 (17)
II	84 (54)
III	40 (27)
IV	3 (2)
Hypertension (%)	25 (16)
Type 2 diabetes (%)	8 (5)
Prior history of nephrolithiasis (%)	14 (9)
Prior endoscopic surgery (i.e., ureteroscopy or percutaneous nephrolithotomy) (%)	20 (13)
Prior endopyelotomy (%)	9 (6)
Prior pyeloplasty (%)	4 (3)
Preoperative stent or nephrostomy tube	

Stent	41(26)
Nephrostomy tube	5 (3)
Side of surgery (%)	
Left	71 (46)
Right	85 (54)
Mean OR duration, min (SD)	178 (47)
Concurrent stone removal stones (%)	14 (9)
Crossing (%)	46 (30)
Mean stent duration, days (SD)	35 (7)
Mean LOS, nights (SD)	2 (1)
Mean followup, years (SD)	2.5 (1.7)

ASA: American Society of Anesthesiologists; BMI: body mass index; IQR: interquartile range; LOS: length of stay; OR: operating room; SD: standard deviation.

Table 2. Primary and secondary outcomes	
Study sample	N=156
Primary outcome n, (%)	n=135 (87%)
Symptom improvement + stable/improved split renal function + improved hydronephrosis + improved drainage on DRS	119 (76)
Symptom improvement + stable/improved split renal function + improved hydronephrosis	12 (8)
Symptom improvement + stable/improved split renal function + improved drainage on DRS	4 (3)
Secondary outcomes, n (%)	
Diagnostic investigation for possible recurrent/persistent obstruction	26 (17)
Repeat intervention for recurrent UPJO	5 (3)

DRS: diuretic renal scan; UPJO: ureteropelvic junction obstruction.