

Case – Laparoscopic radical prostatectomy in a transgender woman after gender-affirming vaginoplasty

Sahil Kumar^{1,2}, Scott Tyldesley³, Christina I. Poon², James T.W. Saunders⁴, Christopher C. Hoag²

¹Faculty of Medicine, University of British Columbia, Vancouver, BC, Canada; ²Department of Urologic Sciences, University of British Columbia, Vancouver, BC, Canada; ³Division of Radiation Oncology, Department of Surgery, University of British Columbia, Vancouver, BC, Canada; ⁴Division of Plastic Surgery, University of British Columbia, Vancouver, BC, Canada

Cite as: Kumar S, Tyldesley S, Poon CI, et al. Case – Laparoscopic radical prostatectomy in a transgender woman after gender-affirming vaginoplasty. *Can Urol Assoc J* 2023 November 20; Epub ahead of print. <http://dx.doi.org/10.5489/cuaj.8387>

Published online November 20, 2023

Corresponding author: Dr. Christopher C. Hoag, Department of Urologic Sciences, University of British Columbia, Vancouver, BC, Canada; cchoag@gmail.com

INTRODUCTION

Transgender (trans) and gender-diverse (TGD) patients with prostates may seek the care of urologists for the management and treatment of prostate cancer. TGD individuals may choose to affirm their identity through social transition, gender-affirming hormone therapy (GAHT), or gender-affirming surgery.¹ Lower gender-affirming surgeries for transfeminine individuals can include bilateral orchiectomy, vulvoplasty or vaginoplasty. Patients do retain their prostate gland with vaginoplasty to minimize complications, and therefore, are still at risk of developing prostate cancer later in life.¹⁻⁴

Transfeminine patients are currently not uniquely addressed in the guidelines for prostate-specific antigen (PSA) screening by urological societies.⁴ The European Association of Urology, Canadian Urological Association, American Urological Association, and the US Preventative Services Task Force do not include recommendations for PSA screening in TGD patients with prostates.⁴⁻⁹ Furthermore, there is no clear consensus on how to best screen for prostate cancer in

KEY MESSAGES

- This is the first report of a laparoscopic radical prostatectomy in a transgender woman who presented with castration-resistant prostate adenocarcinoma after gender-affirming orchiectomy and vaginoplasty.
- Surgical management may necessitate neovaginal reconstruction considering the contiguous location of the neovagina to the posterior prostate within the rectoprostatic space.
- The likelihood of incontinence would need to be addressed with patients undergoing prostatectomy following vaginoplasty and its impact on quality-of-life.
- There are unique considerations for the use of adjuvant and salvage radiation in this setting.

TGD individuals on GAHT.^{4,10} This may contribute to negative experiences with screening and accessing of health services.¹¹

To date in the literature, the 12 publications that summarize the care of transfeminine patients with prostate cancer do not include a case where prostatectomy was performed after penile-inversion vaginoplasty (PIV; Table 1). Herein, we present a case of a transgender woman who underwent laparoscopic radical prostatectomy after PIV, with the goal to preserve neovaginal length and function. We described the work-up and management of this patient with an interdisciplinary team of experts in Urology, Radiation Oncology, Plastic Surgery, and Endocrinology.

CASE REPORT

A 66-year-old transgender woman was referred to urology by her primary care provider for an elevated, first PSA at 26.8 µg/L and bothersome lower urinary tract symptoms including nocturia, incomplete emptying, hesitancy, dysuria, and recurrent urinary tract infections. She had been on feminizing gender-affirming hormone therapy since the age of 54 and underwent bilateral orchiectomy and PIV at 57-years-old. Her medications included oral estradiol therapy 4 mg daily with serum estradiol levels in the normal premenopausal female range, oral medroxyprogesterone acetate 10 mg daily, and oral finasteride 1.25 mg daily.

Her family history was notable for her father who was diagnosed with prostate cancer in his 80s. Her other past medical history included hepatitis C, which was treated 11 years prior with interferon/ribavirin and cleared. She was a past smoker 30 years ago.

Her total testosterone level on presentation was 0.4 nmol/L, free testosterone 5 pmol/L, bioavailable testosterone 0.1 nmol/L, progesterone 0.8 nmol/L, and sex-hormone binding globulin 57.4 nmol/L. Repeat PSA levels were 26.3 µg/L, 27.9 µg/L, and 23.9 µg/L. In the clinic, a transvaginal prostate exam was normal, with no palpable nodularity, asymmetry, or tenderness. Cystoscopy demonstrated a non-obstructing prostate, recessed urethral meatus, and a normal bladder. Despite her small prostate, uroflowmetry revealed a peak flow of 9 mL/s with a PVR of 163 mL.

Workup

An ultrasound-guided transvaginal prostate biopsy was performed and reported a 16 mL gland with Gleason 9 (4+5) prostate adenocarcinoma. Nine of 12 cores were involved, with malignant core lengths ranging from 3 to 14 mm. There was no evidence of extracapsular or perineural invasion (cT1N0M0). The staging CT abdomen/pelvis and nuclear medicine bone scan were both negative. Pelvic MRI demonstrated the anterior neovaginal wall laid directly on the posterior surface of the prostate with no intervening fat plane, and no adenopathy or signs of extra-prostatic involvement.

The case was discussed at a Joint Genitourinary Oncology conference with Urology, Pathology, Radiology, Medical and Radiation Oncology, where the consensus was that only suitable options for definitive therapy were either surgery or external beam radiotherapy (XRT).

It was felt that brachytherapy was not suitable given her ongoing urinary symptoms and the risks of stricture, vesicovaginal fistula, or vaginorectal fistula. She was seen in consultation by both a urologist and radiation oncologist before local therapy, and these options were discussed with the patient who then consented for surgical management.

Based on the MRI findings, it was likely that the posterior prostate would be adherent to the neovaginal wall and would require excision of the anterior neovaginal wall. As such, the possibility of a gracilis myocutaneous flap closure was discussed with Plastic Surgery and intraoperative assistance was planned. The patient was agreeable to the potential loss of neovaginal depth or stenosis with a primary closure. Risks of the procedure were discussed, including significant post-operative incontinence.

Management

After induction of local anesthesia, the patient was positioned in the dorsal low-lithotomy position to allow for intraoperative access to the vagina. Both arms were tucked using custom “sleds” and foam padding. Sequential calf compression devices were used. Foley catheter was placed in the sterile field. Hassan style access lateral to the umbilicus was utilized for intra-peritoneal entry into the abdomen. Pelvic lymph node dissection was performed and sent for frozen section, which demonstrated no evidence of metastases.

The prostate was very small, and the margins were less distinct for her prostate than expected in a typical prostatectomy (Figure 1A). The tip of a van Buren sound placed in the urethra was used to define the anterior prostate margin at the bladder neck, along with neovaginal palpation to identify the lateral and posterior margins of the prostate during the posterior bladder neck dissection and subsequent release of the pedicles (Figure 1B–C).

It was pre-operatively determined that a transvaginal approach would be used to resect the anterior neovaginal wall. However, the neovagina proved too stenotic to allow adequate exposure for a transvaginal approach, and thus excision of the anterior neovaginal wall was performed laparoscopically (Figure 1D–E). The labia majora were sutured closed with a heavy Prolene whipstitch to maintain the pneumoperitoneum during the resection (Figure 2A). Plastic Surgery provided intraoperative consultation regarding closure of the anterior neovaginal wall including consideration of a gracilis myocutaneous flap. The mobility in the neovaginal wall, however, allowed for primary closure with a running V-lock stitch in an “H” configuration to create a foreshortened vagina while maintaining adequate width with minimal tension (Figure 1F–G). Pre-peritoneal fat and peritoneum was tacked over the closure to create intervening layers between the neovagina and the urethral anastomosis (Figure 1H). The urethral anastomosis was completed in the usual manner at the time with interrupted, 2-0 Vicryl stitches (Figure 1G).

The prostate specimen and adherent neovaginal wall were sent for pathology (Figure 2B), including immunohistochemistry (IHC) for estrogen receptor, progesterone receptor, and whole-genome sequencing (WGS) to assess for unique driver mutations. The post-operative pathology and tumour genetics are summarized in Table 2. A Foley catheter was *in situ* for three weeks

post-operatively, given the inherent risk of urethrovaginal fistula. This was later removed in clinic following a neovaginal examination. Urethral meatal erosion was noted to be present.

The patient’s PSA at the one-month follow-up was $<0.008 \mu\text{g/L}$ and the total testosterone level remained undetectable. She was seen by her endocrinologist and her post-operative GAHT was changed to oral estradiol 2 mg daily, while the progesterone and finasteride were stopped.

Given the focal positive margins (1 mm extra-prostatic) and multifocal extracapsular extension (pT3aN0R1), this case was discussed again at an interdisciplinary conference. The panel suggested that the patient should be presented with options of ongoing observation versus post-operative adjuvant radiotherapy. The complexity of interpreting an undetectable PSA in setting of androgen deprivation, despite an elevated PSA at presentation, was considered in the recommendation. The patient opted for surveillance with serum PSA measurements to assess for biochemical recurrence.

Follow-up intravaginal examinations have been normal with no concerning findings. At 5.5 years follow-up, the patient remains biochemically disease free. Unfortunately, continence was never regained and urodynamics supported severe sphincteric incontinence. Due to the previous PIV and urethral truncation, the patient was not felt to be a good candidate for a sling procedure, but transurethral bulking agents were attempted with minimal improvement. With neovaginal dilation the patient was able to engage in penetrative intercourse on occasion.

DISCUSSION

Our case study demonstrates a technique for laparoscopic prostatectomy for localized disease in a transgender woman with previous gender-affirming vaginoplasty. Previous studies did not report the management or approach for a patient who underwent minimally invasive prostatectomy after PIV.

Prostate cancer screening in the TGD population remains an important part of their routine healthcare. The Endocrine Society and the World Professional Association for Transgender Health recommend that transfeminine patients should follow the same prostate cancer screening recommendations as cisgender men.^{12,13} However, patients on GAHT and who have undergone a bilateral orchiectomy will be androgen deprived. Therefore, PSA levels will decrease significantly to undetectable levels, and reported values need to be interpreted in this context.^{1,4} In such cases, where prostate cancer is diagnosed after GAHT, tumour aggressiveness and possible unique driver mutations should be considered with further IHC and WGS testing. Furthermore, prostate examinations can be performed intravaginally for screening after PIV but may be impeded if the neovaginal depth is less than 13 cm or if there is increased tissue rigidity of the neovagina.¹⁴ Ultrasonography and prostate biopsy, if needed, can also be performed through a transvaginal approach.

There is little data available to inform the treatment of urinary complications following prostatectomy in transfeminine individuals after vaginoplasty.³ Patients who have undergone radical prostatectomy and PIV have impaired pelvic floor activity and can weaken or damage the urethral sphincters,¹⁵ and may benefit from pre-operative urodynamic studies. A truncated

urethra at the level of the mid-to-proximal bulbar segment make sling procedures for stress urinary incontinence surgically difficult and are not currently characterized in the literature for this population.³ There is a risk of urethrovaginal fistula following prostatectomy due to the neovaginal flap dissection.^{3,16} The shortest duration for post-operative catheterization should be considered to minimize the possibility of urethral erosion. Mild incontinence may be treated with bulking agents, lifestyle modifications, pessary, or pelvic floor physiotherapy. Other considerations after radical prostatectomy after PIV include ongoing dilation needs and would depend on a patient’s desire for neovaginal intercourse. Tools use for patient education or evaluating patient reported outcomes (PRO) need to be modified and customised to transgender patients’ circumstances (e.g., educational documents that include information on penile rehabilitation or PROs that include Sexual Health Inventory Men (SHIM) score tools are not appropriate in these cases).

The tolerance of the neovagina constructed from inverted penile flap to radiation is currently unknown. XRT has a risk of urinary retention, neovaginal stenosis and fistualization, with potential differences in flap or split-thickness graft placement overlying the prostate.³ Furthermore, the use of brachytherapy would be challenging in atrophic prostate glands less than 20 mL secondary to GAHT.¹⁷ The benefits and risks of surgical versus XRT is best approached with an interdisciplinary team.

CONCLUSIONS

This is the first report of a laparoscopic radical prostatectomy in a transgender woman who presented with castration-resistant prostate adenocarcinoma after gender-affirming orchiectomy and vaginoplasty. Surgical management may necessitate neovaginal reconstruction considering the contiguous location of the neovagina to the posterior prostate within the rectoprostatic space. We recognize that prostatectomy following vaginoplasty in this population is likely to expand and more work will be necessary to find the best surgical approach for minimizing the risk of incontinence and its impact on quality-of-life.

REFERENCES

1. Anderson K, Krakowsky Y, Potter E, et al. Adult transgender care: A review for urologists. *Can Urol Assoc J* 2021;15:345. <https://doi.org/10.5489/cuaj.6949>
2. Bertoncelli Tanaka M, Sahota K, Burn J, et al. Prostate cancer in transgender women: What does a urologist need to know? *BJU Int* 2022;129:113-22. <https://doi.org/10.1111/bju.15521>
3. Crowley F, Mihalopoulos M, Gaglani S, et al. Prostate cancer in transgender women: Considerations for screening, diagnosis and management. *Br J Cancer* 2023;128:177-89. <https://doi.org/10.1038/s41416-022-01989-y>
4. Nik-Ahd F, Jarjour A, Figueiredo J, et al. Prostate-specific antigen screening in transgender patients. *Eur Urol* 2022;83:48-54. <https://doi.org/10.1016/j.eururo.2022.09.007>
5. Gandaglia G, Albers P, Abrahamsson PA, et al. Structured population-based prostate-specific antigen screening for prostate cancer: The European Association of Urology position in 2019. *Eur Urol* 2019;76:142-50. <https://doi.org/10.1016/j.eururo.2019.04.033>
6. Mottet N, van den Bergh RC, Briers E, et al. EAU-EANM-ESTRO-ESUR-SIOG guidelines on prostate cancer-2020 update. Part 1: Screening, diagnosis, and local treatment with curative intent. *Eur Urol* 2021;79:243-62. <https://doi.org/10.1016/j.eururo.2020.09.042>
7. Rendon RA, Mason RJ, Marzouk K, et al. Canadian Urological Association recommendations on prostate cancer screening and early diagnosis. *Can Urol Assoc J* 2017;11:298-309. <https://doi.org/10.5489/cuaj.4888>
8. Carter HB, Albertsen PC, Barry MJ, et al. Early detection of prostate cancer: AUA guideline. *J Urol* 2013;190:419-26. <https://doi.org/10.1016/j.juro.2013.04.119>
9. US Preventive Services Task Force, Grossman DC, Curry SJ, et al. Screening for prostate cancer: US Preventive Services Task Force recommendation statement. *JAMA* 2018;319:1901-13. <https://doi.org/10.1001/jama.2018.3710>
10. Muermann MM, Wassersug RJ. Prostate Cancer from a sex and gender perspective: A review. *Sex Med Rev* 2022;10:142-54. <https://doi.org/10.1016/j.sxmr.2021.03.001>
11. Lombardo J, Ko K, Shimada A, et al. Perceptions of and barriers to cancer screening by the sexual and gender minority community: A glimpse into the health care disparity. *Cancer Causes & Control* 2022; 33:559-82. <https://doi.org/10.1007/s10552-021-01549-4>
12. Hembree WC, Cohen-Kettenis PT, Gooren L, et al. Endocrine treatment of gender-dysphoric/gender-incongruent persons: An endocrine society clinical practice guideline. *J Clin Endocrinol Metab* 2017;102:3869-903. <https://doi.org/10.1210/jc.2017-01658>
13. Coleman E, Radix AE, Bouman WP, et al. Standards of care for the health of transgender and gender diverse people, version 8. *IJTH* 2022;23:S1-259.
14. Weyers S, De Sutter P, Hoebeke S, et al. Gynaecological aspects of the treatment and follow-up of transsexual men and women. *Facts Views Vis Obgyn* 2010;2:35-54.
15. Jiang D, Witten J, Berli J, et al. Does depth matter? Factors affecting choice of vulvoplasty over vaginoplasty as gender-affirming genital surgery for transgender women. *JSM* 2018;15:902-6. <https://doi.org/10.1016/j.jsxm.2018.03.085>

16. Chen ML, Reyblat P, Poh MM, et al. Overview of surgical techniques in gender-affirming genital surgery. *Transl Androl Urol* 2019;8:191-208. <https://doi.org/10.21037/tau.2019.06.19>
17. Mayadev J, Merrick GS, Reed JR, et al. Permanent prostate brachytherapy in prostate glands <20 cm³. *Int J Radiat Oncol Biol Phys* 2010;76:1450-55. <https://doi.org/10.1016/j.ijrobp.2009.04.014>
18. Markland C. Transsexual surgery. *Obstet Gynecol Ann* 1975;4:309-30.
19. Thurston AV. Carcinoma of the prostate in a transsexual. *Br J Urol* 1994;73:217. <https://doi.org/10.1111/j.1464-410X.1994.tb07503.x>
20. van Haarst EP, Newling DW, Gooren LJ, et al. Metastatic prostatic carcinoma in a male-to-female transsexual. *British J Urol* 1998;81:776. <https://doi.org/10.1046/j.1464-410x.1998.00582.x>
21. Miksad RA, Bublely G, Church P, et al. Prostate cancer in a transgender woman 41 years after initiation of feminization. *JAMA* 2006;296:2316-17. <https://doi.org/10.1001/jama.296.19.2316>
22. Dorff TB, Shazer RL, Nepomuceno EM, et al. Successful treatment of metastatic androgen-independent prostate carcinoma in a transsexual patient. *Clin Genitourin Cancer* 2007;5:344-6. <https://doi.org/10.3816/CGC.2007.n.016>
23. Turo R, Jallad S, Prescott S, et al. Metastatic prostate cancer in transsexual diagnosed after three decades of estrogen therapy. *Can Urol Assoc J* 2013;7:E544. <https://doi.org/10.5489/cuaj.175>
24. Ellent E, Matrana MR. Metastatic prostate cancer 35 years after sex reassignment surgery. *Clin Genitourin Cancer* 2016;14:E207-9. <https://doi.org/10.1016/j.clgc.2015.11.007>
25. Deebel NA, Morin JP, Autorino R, et al. Prostate cancer in transgender women: Incidence, etiopathogenesis, and management challenges. *Urol* 2017;110:166-71. <https://doi.org/10.1016/j.urology.2017.08.032>
26. Sharif A, Malhotra NR, Acosta AM, et al. The development of prostate adenocarcinoma in a transgender male to female patient: Could estrogen therapy have played a role? *Prostate* 2017;77:824-28. <https://doi.org/10.1002/pros.23322>
27. Ingham MD, Lee RJ, MacDermed D, Olumi AF. Prostate cancer in transgender women. *Urol Oncol* 2018;36:518-25. <https://doi.org/10.1016/j.urolonc.2018.09.011>
28. Chandran K, Grochot R, de la Maza MDF, et al. A transgender patient with prostate cancer: Lessons learnt. *Eur Urol* 2023:S0302-2838.

FIGURES AND TABLES

Figure 1. Intraoperative images. (A) Prostate defatted and pelvic anatomy visualized. (B) van Buren sound used to identify the margins of the prostate and bladder neck. (C) Exposure of the margin of the prostate and bladder neck. (D) Right anterior neovaginal wall mobilisation from the prostate. Prostate outlined in dotted line. (E) Excision of left anterior neovaginal wall from the prostate. Prostate outlined in dotted line. (F) Midline vaginal closure of neovaginal opening. (G) Running V-lock “H” configuration of the neovaginal canal, as outlined by white dotted line. (H) Interposition of the pre-peritoneal fat and peritoneal layer above neovaginal closure, as outlined by white dotted line. (I) Performing the urethral anastomosis to the bladder neck with Foley catheter in situ. Note: cranial-caudal image orientation.

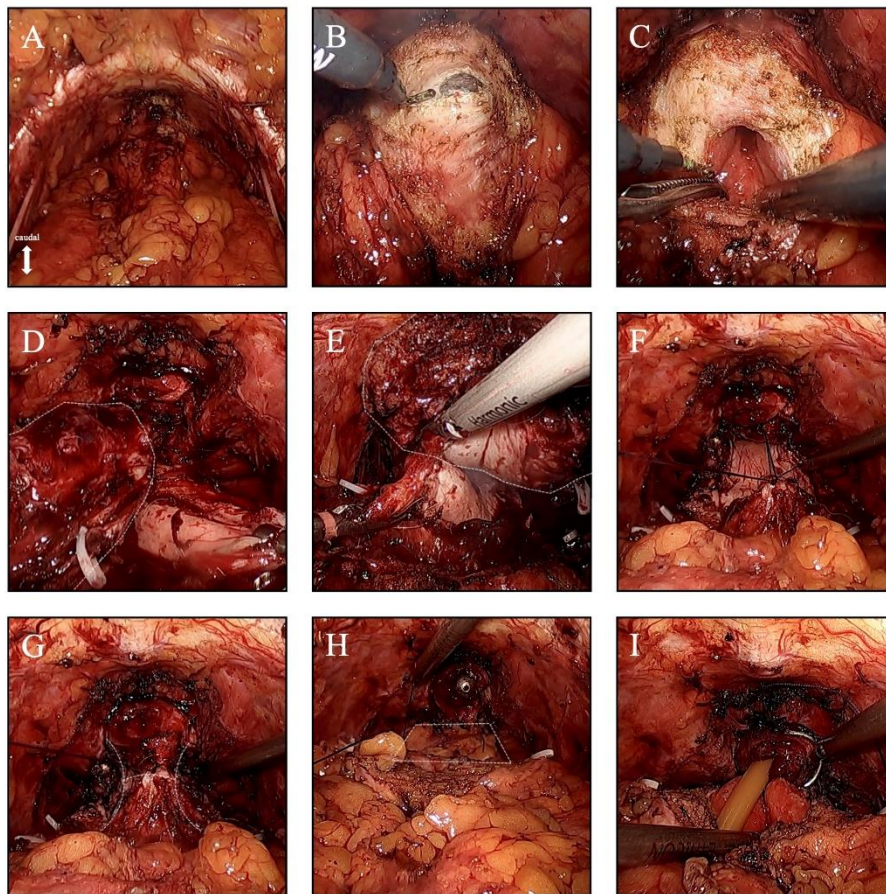
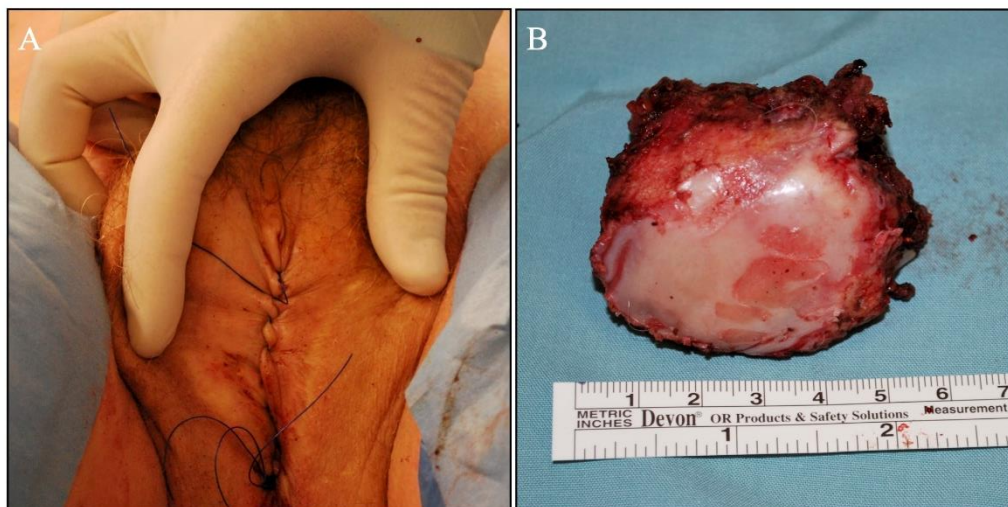


Figure 2. (A) Labia majora closure with a heavy Prolene whipstitch. (B) Prostate specimen and adherent anterior neovaginal wall.



Reference	Age	Presenting PSA level (µg/L)	Metastatic disease at diagnosis	Previous lower GAS	Management
Markland, 1975 ¹⁸	54	Unknown	Unknown	Orchiectomy	Unknown
Thurston, 1994 ⁹	64	27.3	No	No orchiectomy, no vaginoplasty	Radiation therapy
van Haarst et al, 1998 ²⁰	63	1.7	Yes	Orchiectomy, no vaginoplasty	Chemotherapy
Miksad et al, 2006 ²¹	60	240	No	Orchiectomy, vaginoplasty	Radiation therapy and ADT, on surveillance
Dorff et al, 2007 ²²	78	20.6	No	Orchiectomy, GAS noted	Radiation therapy and chemotherapy
Turo et al, 2013 ²³	75	13.5	No	Orchiectomy, GAS noted	Radiation therapy, ADT, chemotherapy
Ellent & Matrana, 2016 ²⁴	65	18	Yes	No orchiectomy, no vaginoplasty	Surgical castration, chemotherapy, open cystoprostatectomy

Deebel et al, 2017 ²⁵	65	7.5	No	No orchiectomy, no vaginoplasty	Robot-assisted radical prostatectomy, on surveillance
Sharif et al, 2017 ²⁶	56	5	No	No orchiectomy, no vaginoplasty	Robot-assisted radical prostatectomy, on surveillance
Ingham et al, 2018 ²⁷	60	3.3	No	No orchiectomy, no vaginoplasty	Robot-assisted radical prostatectomy, on surveillance
Crowley et al, 2023 ³	50	1.4	No	Unknown	Active surveillance
Chandran et al, 2023 ²⁸	69	5.71	No	No orchiectomy, no vaginoplasty	Surgical castration, ADT, brachytherapy, radiotherapy

ADT: androgen deprivation therapy; GAS: gender-affirming surgery.

Table 2. Prostate pathology and tumor genetic assessment	
Tissue pathology	Findings
Gleason score	9 (4+5) adenocarcinoma
Extracapsular extension	Multifocal extensions at the prostate base bilaterally and into the neovaginal submucosa
Lymphovascular invasion	Present
Perineural invasion	Present
Lymph nodes	Negative
Margins	Unifocal 1 mm Positive margin at left base site of extracapsular extension
Tumor size	25 mm; 50% of gland

Tumor genetics	Estrogen receptor negative (ER–) Progesterone receptor negative (PR–) Androgen receptor had no mutations or amplifications Chr8p loss (NKX3-1) Chr8q gain (MYC, NCOA2) PTEN heterozygous loss TP53 heterozygous loss No germline variants
----------------	--

DRAFT