

Benign prostatic hyperplasia surgical re-treatment after prostatic urethral lift: A narrative review

Nicholas S. Dean, Mark A. Assmus, Matthew S. Lee, Jenny N. Guo, Amy E. Krambeck
Northwestern University, Department of Urology, Chicago, IL, United States

Cite as: Dean NS, Assmus MA, Lee MS, et al. Benign prostatic hyperplasia surgical re-treatment after prostatic urethral lift: A narrative review. *Can Urol Assoc J* 2023 July 21; Epub ahead of print. <http://dx.doi.org/10.5489/cuaj.8334>

Published online July 21, 2023

Corresponding author: Dr. Nicholas S. Dean, Northwestern University, Department of Urology, Chicago, IL, United States; nicholas.dean@northwestern.edu

ABSTRACT

Introduction: Prostatic urethral lift (PUL) accounts for approximately one-quarter of all surgical benign prostatic hyperplasia (BPH) procedures performed in the U.S.¹ Within five years of a patient's PUL procedure, approximately 1/7 patients will require surgical BPH re-treatment.² We aimed to highlight the evidence of surgical BPH re-treatment modalities after PUL, with a focus on safety, short-term efficacy, durability, and relative costs.

Methods: A literature review was performed using PubMed, and an exhaustive review of miscellaneous online resources was completed. The search was limited to English, human studies. Citations of relevant studies were reviewed.

Results: No study has examined the efficacy, safety, or durability of transurethral resection of the prostate (TURP) or repeat PUL in the post-PUL setting. Recently, groups have examined laser enucleation (n=81), water vapor thermal therapy (WVTT) (n=5), robotic simple prostatectomy (SP) (n=2), and prostatic artery embolization (PAE) (n=1) in the post-PUL setting. Holmium enucleation of the prostate (HoLEP) after PUL appears to be safe and has similar functional outcomes to HoLEP controls. Other treatment

KEY MESSAGES

- Despite an increasing number of patients expected to require surgical re-treatment after PUL, there is limited evidence and a lack of recommendations to guide the management of these patients.
- HoLEP is associated with the strongest evidence to support its use after PUL.
- PVP and RWT have no peer-reviewed evidence to support their use in the post-PUL setting.
- There is no peer-reviewed evidence examining the durability, the cost, or the sexual impact of PUL re-treatment modalities.

modalities examined appear safe but have limited efficacy evidence supporting their use. Photo-selective vaporization of the prostate (PVP) and robotic waterjet treatment (RWT) have no safety or efficacy studies to support their use in the post-PUL setting.

Conclusions: Despite increasing numbers of patients expected to require surgical re-treatment after PUL in North America, there is currently limited evidence and a lack of recommendations guiding the evaluation and management of these patients. HoLEP is associated with the strongest evidence to support its use in the post-PUL setting.

INTRODUCTION

Minimally-invasive surgical therapies (MISTs) are predominantly office-based treatments designed to lessen the morbidity of benign prostatic hyperplasia (BPH) surgical treatment, transition patients off medications, and preserve antegrade ejaculatory function.^{2,3} Prostatic Urethral Lift (PUL) received Food and Drug Administration (FDA) approval for the surgical treatment of BPH in 2013, and in January 2020 received updated approval to treat prostate glands up to 100cc in size.⁴ A recent abstract presented by Cruz et al. (2022) revealed that PUL accounted for 23.7% of all Medicare billed BPH procedures in 2019, an absolute increase of 22.2% from 2015.¹

The initial randomized-controlled L.I.F.T. trial examining PUL outcomes, demonstrated surgical BPH re-treatment at five years post-PUL to be 13.6%.² As highlighted in an editorial by Dr. Kaplan and Dr. McVary, this rate did not account for patients who required surgical removal of the implants that had encrusted in the bladder or were removed prophylactically (9.2%, 13/140).⁵ Of the patients with available follow-up data (n=113) at five years, the rate of surgical BPH re-treatment or surgical clip removal was 28.3% at five years.² Real-world retrospective data examining 2942 PUL patients demonstrated rates of surgical intervention (BPH re-treatment and clip removal) to be 5.2% at one-year and 11.9% at two years.⁶ As the proportion of PUL procedures continues to increase in the US, we can continue to expect an increasing number of patients to require surgical re-intervention after their PUL procedure.

Anecdotally, we have experienced an increasing number of patients presenting to our center for HoLEP post-PUL. In our own retrospective experience, post-PUL HoLEP is associated with longer operative time, an increased number of morcellator blades utilized per case resulting in higher operative costs, and similar functional outcomes compared to controls.⁷ When counseling patients seeking surgical re-treatment options after PUL, we recognized our own knowledge gap regarding the safety and efficacy of available options for surgical BPH re-treatments after PUL. With this review, we aim to highlight the evidence available for surgical BPH re-treatment modalities after PUL with a focus on safety, short-term efficacy, durability, and costs.

METHODS

A literature search using PubMed database was performed on December 12, 2022, for English full-text articles and abstracts. Studies published after November 2022 were not included in the search. The following keywords were used:” prostatic urethral lift” OR “urolift”. Secondary searches were performed querying each alternative treatment modality with prostatic urethral lift and urolift. Duplicate abstracts were excluded. All 247 abstract results were reviewed by a one author (ND) to determine appropriateness for inclusion in the narrative review. All relevant full-texts and their citations were reviewed, and overall, 29 were included and referenced. In the absence of any peer-reviewed published literature, surgical center and surgical treatment manufacturer websites were reviewed, and information was also extracted from social media sources.

RESULTS

Re-treatment/re-intervention

BPH re-treatment after MISTs consists of medical therapy re-initiation (alpha-blockers and 5ARI's), or surgical re-intervention if symptoms are more severe.^{2,6,8} The definition of surgical re-treatment after PUL has not been clearly defined.⁵ The initial L.I.F.T. study defined surgical re-treatment as the requirement for further surgical treatment of BPH with either the addition of PUL clips, a TURP, or a laser BPH treatment (unclear if laser enucleation or ablation).^{2,5} The authors of the L.I.F.T. study did not include surgical interventions for encrusted/migrated PUL clips within this definition.² Dr. McVary and Dr. Kaplan have previously recommended that a standard definition of surgical re-treatment is required when comparing MISTs to decrease the heterogeneity in outcome reporting between studies.⁵

For reasons mentioned previously, rates of surgical re-intervention (BPH re-treatment and clip removal) vary from 2-6%/year between controlled-studies, real-world retrospective data, and meta-analysis.^{2, 6, 9, 10, 11} Predictors of PUL failure requiring surgical intervention have not been clearly defined. Roehrborn et al (2021) performed a multi-regression analysis of L.I.F.T. study patients (n=140) and real-world data (n=3226) examining predictors of PUL failure requiring further BPH re-treatment and found pre-operative IPSS and QOL to be significantly predictive of re-treatment.¹² Gland size >100cc within this analysis was associated with an OR of 2.38, but a p-value that did not reach a level of significance (p=0.144).¹²

Evaluation

Indications for BPH re-intervention after PUL within randomized controlled trials is not clearly defined^{2,9}. Das et al. (2022) defined PUL failure as: “significant LUTS not responding to medical treatments/too severe for medical therapy/desire to avoid oral medications, or urinary retention” within their study examining the role of PUL re-treatment with HoLEP.⁴ Other reported indications for intervention after PUL includes clip removal after misplacement within the bladder, implant encrustation, and pain.^{2,13,14} Despite PUL insertion being recommended by

the AUA guidelines, EAU guidelines, CUA guidelines, and NICE guidelines, there are currently no recommendations for the management of men with recurrent LUTS or urinary retention after PUL or any of the other MIST.^{15,16,17,18}

Surgical BPH re-treatment options

Repeat PUL

A common BPH re-treatment strategy, utilized in the initial PUL RCT's and retrospective cohort studies after PUL failure, is to reconfigure the prostatic urethra by placing more PUL clips.^{2,9} Support for the utilization of repeat PUL in the re-treatment of patients with prior failed-PUL is based on limited evidence. Within the L.I.F.T. study, 6 patients (4.3%) underwent repeat PUL placement.² In retrospective real-world cohort studies, repeat PUL procedures occurred in 1.5% of patients at 1 year and 3% of patients at two years of follow-up.⁶ Despite PUL clips often being utilized for repeat treatments, there are no published indications for when PUL is or should be utilized instead of TURP or laser BPH treatments. No study to date has reported the patient characteristics, operative characteristics (OR time, number of implants), peri-operative complications, catheter duration, post-operative IPSS/PVR/ejaculatory function, durability of outcomes, costs, or freedom from next BPH treatments of patients undergoing repeat PUL placement. (Table 1)

TURP

TURP is a frequently performed BPH procedure after PUL failure.^{2,6,9} Support for the utilization of TURP in the re-treatment of patients with failed-PUL is based on limited evidence. Within the L.I.F.T. study, 13 patients (9.2%) underwent re-treatment with TURP or laser treatment.² Like repeat PUL, TURP has no published outcome data in the post-PUL setting.^{6,11} (Table 1) Interestingly, TURP has been reported to be more difficult after PUL, due to fracture of the TUR cauterly loop by the embedded clips. Despite anecdotal comments about this on social media, we were unable to identify reports of this in a peer-reviewed setting or increased operative times or costs associated loop fracture.

WVTT

Support for the use of WVTT in the management of failed-PUL BPH re-treatment is based on limited evidence. The most recent and only study examining the role of WVTT in a salvage post-PUL setting reported the results of 19 patients after failed BPH surgery (26.3%, 5/19 PUL)¹⁹. Treatment failure was defined as recurrent LUTS or requirement for medical therapy. Pre-operative work-up for these patients prior to WVTT included a urologic history, MRI or transrectal ultrasound, and peri-operative cystourethroscopy¹⁹. Although the WVTT post-operative outcomes were reported as one heterogenous cohort after several previous different procedures, the authors report that the post-PUL patients had a median re-intervention time of 20 months and prostate size of 64mL. (Table 1) Overall, the entire cohort had a low rate of post-

operative complications after WVTT. Complications included the requirement for a catheter in 2/19 patients after the 7-14 day standard removal, however it is not clear if urinary retention occurred in post-PUL patients. The authors report that the PUL clips were left in place after WVTT treatment, and recommend that the surgeon must be attentive at the time of WVTT to avoid injury to the sphincter given altered anatomy after PUL and to be aware of the theoretical loosening of clips due to tissue apoptosis after WVTT.¹⁹ At 3-months follow-up, no clip complications were noted by the authors. Preservation of ejaculatory function and durability of treatment were not examined.

Simple prostatectomy (SP)

Support for the utilization of robotic SP in the management of patients with prior-PUL is based on limited evidence. One abstract was identified reporting the outcomes of “salvage” robotic simple prostatectomy compared to a non-salvage cohort.²⁰ Within the salvage cohort, 9% (2/22) of patients had undergone prior PUL. Details about the pre-operative evaluation and timing from PUL to SP were not defined. (Table 1) Mean length of stay was 1.91 days in the salvage cohort. Functional outcomes within the salvage group did not differ from the SP control cohort, however specific post-PUL SP outcomes were not examined.

Robotic waterjet treatment (RWT)

We were unable to identify any evidence to support the use of RWT in the failed-PUL setting. On review of the Aquablation website and the websites of providers marketing RWT, we did not identify any recommendations for use of RWT in the post-PUL setting. (Table 1)

Transurethral laser enucleation

Holmium laser enucleation of the prostate (HoLEP)

Support for the utilization of HoLEP in the re-treatment of patients with failed-PUL is based on a moderate amount and quality of evidence. Seven studies have investigated HoLEP after PUL treatment.^{4,7,13,14,21,22,23} (Table 1) McAdams (2017) presented a multi-institutional case series (n=7) of patients who underwent HoLEP after failed-PUL.¹³ The majority of these patients (6/7) were treated for persistent LUTS/urinary retention and 1 patient underwent HoLEP for chronic pain after PUL. All patients underwent cystourethroscopy prior to HoLEP in this setting. The median time from PUL to HoLEP was 8.6 months. Mean prostate size was 80 cc. The group noted no Clavien-Dindo complications and disadvantaged morcellation due to PUL clips. Aberrant clip locations were noted in 6/22 clips.

Das et al. (2022) compared patients undergoing HoLEP after PUL (n=22) to a control cohort of patients undergoing HoLEP (771) and demonstrated that post-PUL HoLEP was associated with decreased overall operative efficiency and morcellation efficiency.⁴ The authors of this study did not find any difference in functional outcomes or complications between patients with and without prior PUL after HoLEP. Median time from PUL to HoLEP was 14.4

months and 3 (13.6%) of these patients had catheters pre-operatively. Interestingly, one of the patients within this post-PUL HoLEP series required a second transurethral procedure to remove a calcified adenoma that would not morcellate, thus requiring a transurethral resection.

Another retrospective study examined “salvage” HoLEP procedures in patients who had undergone prior BPH surgery, of which 24 (11.1%) had a prior PUL.²³ “Salvage” HoLEP was associated with longer operative times and hospital stays, but there was no difference in functional outcomes in this heterogeneous salvage cohort. The median time from PUL to HoLEP in this cohort was 15.9 months. Within these two large published post-PUL HoLEP series, 54.3% (25/46) prostates were >80 cc on pre-HoLEP imaging.^{4,23} Rates of ejaculatory function were not reported prior to HoLEP in any of the post-PUL HoLEP studies.

In our local experience comparing 22 men who underwent HoLEP after PUL to 455 men undergoing HoLEP as a control, patients who underwent HoLEP after PUL had longer operative times, worse morcellation efficiency, and required an increased number of morcellator blades (1.3 vs. 1.0 blades/case).⁷ We did not identify any difference in rate of same-day catheter removal, rate of same-day discharge, 90-day complication rates, or continence rates. Rates of ejaculatory function were not reported prior to HoLEP in any of the post-PUL HoLEP studies. Rates of ejaculatory function were not reported prior to HoLEP in any of the post-PUL HoLEP studies.

Thulium fiber laser enucleation (TFL)

The use of TFL as an energy source for prostate enucleation in the surgical BPH re-treatment after PUL is supported by limited evidence. We were able to identify a single case study examining an en-bloc technique utilized for TFL enucleation of a 198cc gland.²⁴ (Table 1) The authors of the study report that the PUL clips hampered morcellation efficiency and the surgeon required the use of three morcellator blades in total. The patient was discharged without a catheter on post operative day 1 without complication and with an improvement in functional outcomes (IPSS and uro-flow).

Photo vaporization of the prostate (PVP)

We were unable to identify any peer-reviewed evidence to support the use of PVP in the post-PUL setting. (Table 1) A review of the Boston Scientific website demonstrates anecdotal editorial statements from three urologists supporting the use of PVP in the failed-PUL setting.²⁵ The urologists suggest that Greenlight “can remove Urolift (PUL) implants”, “can...vaporize the majority of the obstructing tissue”, and “remove the median lobe and the Urolift (PUL) implants and create a nice open channel for the patient to void through and have significant relief of their symptoms”. The editorial provides step-by-step recommendations and trouble-shooting techniques for the urologist in the post-PUL setting.

Prostatic artery embolization (PAE)

Support for prostatic artery embolization (PAE) utilization after failed-PUL is based on limited evidence. We were able to identify a case report of 1 patient who underwent PAE after PUL.²⁶ (Table 1) The time from PUL failure to PAE was 1 month and the patient's prostate size was 99 cc. The patient's symptomatic LUTS (IPSS=14) prompted PAE. The PAE procedure was technically unaffected by the patient's prior PUL procedure. The patient did not undergo pre-operative cystourethroscopy. At 12 months post-operatively, prostate volume decreased to 53 cc and IPSS decreased by 10 points.

Surgical interventions for mis-fired/migrated clips or clip encrustation

Despite a 7.1% rate (10/140) of clip encrustation in the initial L.I.F.T. study, changes in technique and more distal clip placement have reportedly decreased the rates of implant encrustation to 1%.^{2,10,27} In a 2022 study, the rate of post-market implant encrustation based on voluntary surgeon reporting to be 43/779,844.²⁸ This reported rate of encrustation is much lower than the rates reported within post-PUL HoLEP retrospective studies (1.0-7.1%).^{4,13,21,23} There are no studies comparing the efficiency or relative costs associated with different removal techniques for PUL clip encrustation.

DISCUSSION

With the difficulty to treat patients with BPH in an operating room setting during the COVID-19 pandemic, it is likely that the proportion of MISTs, specifically PUL, will see continued growth from 2019 until present. Based on our models, assuming a linear growth rate of 3.7% evidenced from 2015 to 2019 in Medicare reimbursement data and a surgical re-treatment rate of 13.6% after 5 years, Medicare re-imbursed PUL cases performed between 2019 to 2024 will demand approximately 24,807 post-PUL re-treatment BPH procedures (Figure 1).

Currently there is a lack of guidance within national urologic guidelines for the evaluation of patients with persistent LUTS after failed-PUL.¹⁵⁻¹⁷ Consideration, based on expert opinion, should be made to add cystourethroscopy after PUL with persistent LUTS to the BPH surgical guidelines. Cystourethroscopy should be utilized to evaluate for misplaced or encrusted PUL clips and assess the prostatic urethra and bladder anatomy prior to repeat MISTs or surgical intervention. Cystourethroscopy may influence the surgeon's treatment selection and candidacy for repeat PUL clip insertions, removal of encrusted clips, or extirpative or ablative treatment options.

As emphasized within our review, the most efficient, efficacious, safe, and cost-effective BPH re-treatment modality after failed-PUL has yet to be determined. The most utilized surgical treatments within the initial PUL studies were TURP and repeat PUL placement. Chin et al. (2012) reports that "...each of these methods of re-treatment was routine and unaffected by the presence of the implants".²⁹ Despite the use of TURP and repeat PUL placement, no group has

reported peri-operative outcomes, short or long-term post-operative outcomes, or the examined the costs associated with post-PUL TURP or repeat PUL placement.

HoLEP has the most robust clinical evidence supporting its use of any post-PUL re-treatment modality. Within our review, we identified 11 retrospective studies (including our local data, n=22) examining 89 total patients who underwent post-PUL BPH re-treatment. Of these patients, 89.9% (80/89) examined HoLEP outcomes after PUL. HoLEP is the only post-PUL re-treatment modality shown to have similar functional outcomes to HoLEP patients with no prior BPH surgery.^{4,7,23} WVTT and robotic SP studies have examined functional outcomes compared to controls, however post-PUL WVTT and SP patients made up a minority of the patients within the post-surgery/salvage cohorts (5/19, 26.3% and 2/22, 9.1% respectively).^{19,20}

In our experience in evaluating patients after failed-PUL, these patients are seeking a treatment option with more robust and durable long-term outcomes, to avoid the annularity of BPH procedures and the costs and discomfort associated them. As HoLEP providers, we will continue to treat patients with HoLEP after PUL given evidence supporting its efficacy, safety, and hypothesized long-term durability.

CONCLUSIONS

Based on our review, the number of patients treated with PUL is increasing annually and thus, we find ourselves in a situation where many patients in North America will require re-treatment for persistent or recurrent lower urinary tract symptoms. HoLEP has the most robust clinical evidence supporting its use of any post-PUL re-treatment modality. Some BPH modalities currently utilized for the treatment of BPH in the post-PUL setting have little to no clinical evidence supporting their use. We encourage urologists to continue to examine the outcomes of all BPH modalities after PUL to better understand the utility of these treatments in the post-PUL setting and subsequently better counsel our patients to offer cost-effective treatments in-line with patient expectations.

Competing interests: Dr. Lee is a consultant for Boston Scientific. Dr. Krambeck is a consultant for Boston Scientific, Karl Storz, Wolf and Virtuoso Surgical. She is the data safety monitoring board chair for Sonomotion.

REFERENCES

1. Cruz AP, Yamany T. Medicare national and regional trends in BPH surgery, 2013-2019. *J Urol*. 2022 May. <https://www.auajournals.org/doi/10.1097/JU.0000000000002597.07>.
2. Roehrborn CG, Barkin J, Gange SN, et al. Five year results of the prospective randomized controlled prostatic urethral L.I.F.T. study. *Can J Urol*. 2017 Jun;24(3):8802-8813. PMID: 28646935.
3. Elterman D, Gao B, Lu S, et al. New Technologies for Treatment of Benign Prostatic Hyperplasia. *Urol Clin North Am*. 2022 Feb;49(1):11-22. doi: 10.1016/j.ucl.2021.07.007. Epub 2021 Oct 25. PMID: 34776045.
4. Das A, Han TM, Rudnick B, et al. Holmium Laser Enucleation of the Prostate Following Previous Prostatic Urethral Lift. *J Endourol*. 2022;36(1):111-116. doi:10.1089/end.2021.0351
5. McVary KT, Kaplan SA. A Tower of Babel in Today's Urology: Disagreement in Concepts and Definitions of Lower Urinary Tract Symptoms/Benign Prostatic Hyperplasia Re-Treatment. *J Urol*. 2020 Aug;204(2):213-214. doi: 10.1097/JU.0000000000001073. Epub 2020 Apr 7. PMID: 32469261.
6. Page T, Veeratterapillay R, Keltie K, et al. Prostatic urethral lift (UroLift): a real-world analysis of outcomes using hospital episodes statistics. *BMC Urol*. 2021 Apr 7;21(1):55. doi: 10.1186/s12894-021-00824-5. PMID: 33827525; PMCID: PMC8028737.
7. Assmus MA, Lee MS, Helon J, et al. MP6-05 HoLEP Outcomes after Water Vapor Thermal Therapy, Prostatic Urethral Lift, Robotic Waterjet Treatment or Prostatic Artery Embolization. Abstracts of the 39th World Congress of Endourology: WCE 2022. *Journal of Endourology* .Sep 2022.A1-A315.<http://doi.org/10.1089/end.2022.36001.abstracts>
8. Ory J, Nackeeran S, Rainer Q, et al. Persistent use of medical therapy after surgery for lower urinary tract symptoms: a retrospective database analysis. *World J Urol*. 2022 Jan;40(1):169-175. doi: 10.1007/s00345-021-03819-x. Epub 2021 Aug 26. PMID: 34435214.
9. Gratzke C, Barber N, Speakman MJ, et al. Prostatic urethral lift vs transurethral resection of the prostate: 2-year results of the BPH6 prospective, multicentre, randomized study. *BJU Int*. 2017;119(5):767-775. doi:10.1111/bju.13714
10. Eure G, Gange S, Walter P, et al. Real-World Evidence of Prostatic Urethral Lift Confirms Pivotal Clinical Study Results: 2-Year Outcomes of a Retrospective Multicenter Study. *J Endourol*. 2019 Jul;33(7):576-584. doi: 10.1089/end.2019.0167. Epub 2019 Jun 25. PMID: 31115257; PMCID: PMC6657298
11. Miller LE, Chughtai B, Dornbier RA, et al. Surgical Reintervention Rate after Prostatic Urethral Lift: Systematic Review and Meta-Analysis Involving over 2,000 Patients. *J Urol*. 2020 Nov;204(5):1019-1026. doi: 10.1097/JU.0000000000001132. Epub 2020 May 12. PMID: 32396049.
12. Chin P, Barber N, Eure G, et al. Predictors of durability after Prostatic Urethral Lift in the real world and the LIFT controlled study. Abstract ICS Melbourne. 2021. <https://www.ics.org/2021/abstract/267>
13. McAdams S, Funk JT, Navetta AF, et al. Holmium Laser Enucleation of the Prostate After Prostatic Urethral Lift Surgery: Feasibility and Technical Considerations from a

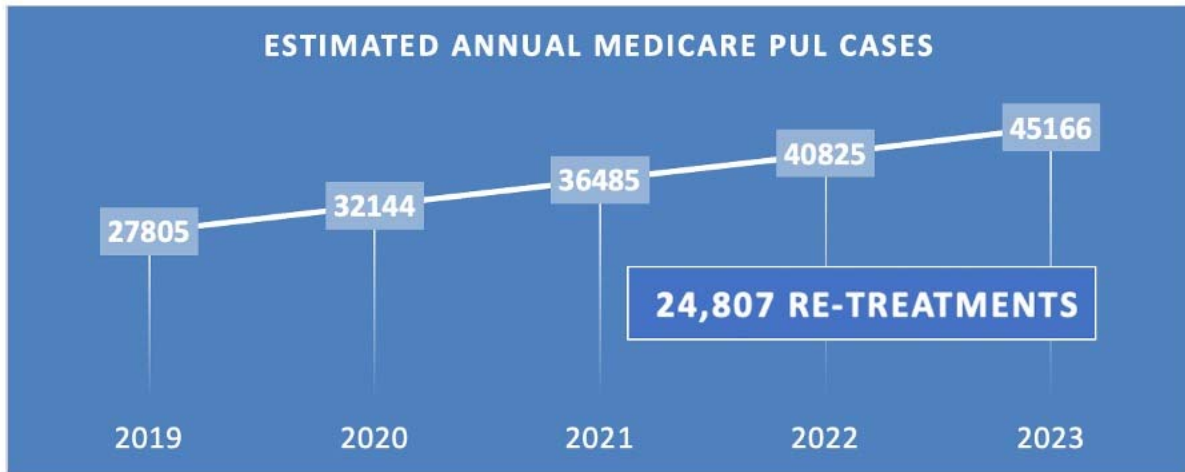
- Multi-Institutional Case Series. *J Endourol.* 2017 Aug;31(8):774-779. doi: 10.1089/end.2017.0224. Epub 2017 Jul 5. PMID: 28586247. (7 patients)
14. David J, Baird BA, Ericson CA, et al. Prostatic urethral lift (PUL) clip causing postoperative pain after holmium laser enucleation of the prostate (HoLEP). *Urol Case Rep.* 2022 Sep 16;45:102230. doi: 10.1016/j.eucr.2022.102230. PMID: 36176717; PMCID: PMC9513101.
 15. Lerner LB, McVary KT, Barry MJ, et al. Management of Lower Urinary Tract Symptoms Attributed to Benign Prostatic Hyperplasia: AUA GUIDELINE PART II- Surgical Evaluation and Treatment [published correction appears in *J Urol.* 2022 Mar;207(3):743] [published correction appears in *J Urol.* 2022 Oct;208(4):939]. *J Urol.* 2021;206(4):818-826. doi:10.1097/JU.0000000000002184
 16. Gravas S, Cornu JN, Gacci M, et al. EAU guidelines on management of non-neurogenic male lower urinary tract symptoms (LUTS) incl. benign prostatic obstruction. *European Association of Urology 2022.* Edn. presented at the EAU Annual Congress Amsterdam 2022. ISBN 978-94-92671-16-5.
 17. Nickel JC, Aaron L, Barkin J, et al. Canadian Urological Association guideline on male lower urinary tract symptoms/benign prostatic hyperplasia (MLUTS/BPH): 2018 update. *Can Urol Assoc J.* 2018 Oct;12(10):303-312. doi: 10.5489/cuaj.5616. PMID: 30332601; PMCID: PMC6192748.
 18. National Clinical Guideline Centre (UK). *The Management of Lower Urinary Tract Symptoms in Men.* London: Royal College of Physicians (UK); 2010.
 19. Gauhar V, Lim EJ, Khan TY, et al. Rezum to the rescue: Early outcomes of Rezum on patients with recurrent lower urinary tract symptoms after surgical interventions for benign prostatic enlargement. *Andrologia.* 2022 Sep;54(8):e14450. doi: 10.1111/and.14450. Epub 2022 Apr 26. PMID: 35474587.
 20. Pathak R, Krol B, Crain N, et al. Is Simple Prostatectomy After Prior Minimally Invasive Surgical Therapies for Benign Prostatic Hyperplasia as Efficacious as Primary Simple Prostatectomy. *J Urol.* 2022. MP29-03.
<https://www.auajournals.org/doi/10.1097/JU.0000000000002572.03>
 21. Parikh KA, Dora CD. Holmium Laser Enucleation of the Prostate After Failed UroLift: Surgical Considerations for the Management of Nonabsorbable Implants. *Urology.* 2019 Oct;132:212. doi: 10.1016/j.urology.2019.06.027. Epub 2019 Jul 2. PMID: 31271781.
 22. Iqbal M, Jones R, Hughes S, et al. Low power HOLEP after failed urolift: A case report using 50 Watt laser. *Urol Case Rep.* 2017 Dec 5;16:114-115. doi: 10.1016/j.eucr.2017.11.029. PMID: 29255680; PMCID: PMC5724983.
 23. Durant AM, Moore J, Voleti S, et al. Salvage versus primary holmium laser enucleation of the prostate: trends, outcomes and safety analysis. *World J Urol.* 2022 Sep;40(9):2305-2312. doi: 10.1007/s00345-022-04098-w. Epub 2022 Jul 22. PMID: 35867143.
 24. Smith NA, Katz JE, Shah HN. Salvage Enbloc Thulium Fiber Laser Enucleation of Prostate for Giant Prostatomegaly After Prostatic Urethral Lift. *Urology.* 2021 Aug;154:342-343. doi: 10.1016/j.urology.2021.04.028. Epub 2021 May 8. PMID: 33971190.

25. Website: Boston Science Editorial Commentary. <https://www.bostonscientific.com/en-US/medical-specialties/urology/procedures-and-treatments/benign-prostatic-hyperplasia/physicians-perspectives/greenlight-after-urolift.html>.
26. Tapping CR, Little MW, Boardman P. Successful Prostatic Artery Embolization following UroLift Device Failure. *J Vasc Interv Radiol*. 2017 Sep;28(9):1275-1276. doi: 10.1016/j.jvir.2017.02.028. PMID: 28841929.
27. Roehrborn CG, Chin PT, Woo HH. The UroLift implant: mechanism behind rapid and durable relief from prostatic obstruction [published correction appears in *Prostate Cancer Prostatic Dis*. 2022 Jan 12;:]. *Prostate Cancer Prostatic Dis*. 2022;25(1):79-85. doi:10.1038/s41391-021-00434-0
28. Kaplan-Marans E, Martinez M, Wood A, et al. Aquablation, Prostatic Urethral Lift, and Transurethral Water Vapor Therapy: A Comparison of Device-Related Adverse Events in a National Registry. *J Endourol*. 2022 Feb;36(2):231-235. doi: 10.1089/end.2021.0455. Epub 2021 Dec 13. PMID: 34314240.
29. Chin PT, Bolton DM, Jack G, et al. Prostatic urethral lift: two-year results after treatment for lower urinary tract symptoms secondary to benign prostatic hyperplasia. *Urology*. 2012 Jan;79(1):5-11. doi: 10.1016/j.urology.2011.10.021. PMID: 22202539.

DRAFT

FIGURES AND TABLES

Figure 1. Estimated total annual Medicare re-imbursed PUL cases and overall surgical BPH re-treatment cases 2019–2024 (assuming 3.7% growth in PUL Medicare cases annually).



DRAFT

Table 1. Post-PUL re-treatment modalities													
Author	Year	Country	Study type	n	Prostate size (cm³)	Time from PUL (months)	LOS (days)	Complications (%)	EBL (mL)	ER visit (%)	PVR Δ (mL)	AU ASS Δ	Peak flow Δ (mL/s)
Repeat PUL													
Roehrborn ²	2017	USA	RCT	6	NR	NR	NR	NR	NR	NR	NR	NR	NR
Page ⁶	2021	UK	Retrospective	57	NR	NR	NR	NR	NR	NR	NR	NR	NR
TURP													
Roehrborn ²	2017	USA	RCT	NR	NR	NR	NR	NR	NR	NR	NR	NR	NR
Gratzke ⁹	2016	Germany	RCT	NR	NR	NR	NR	NR	NR	NR	NR	NR	NR
WTT													
Gauhar ¹⁹	2022	Singapore	Retrospective	5	64	20	NR	0	NR	NR	NR	NR	NR
SP													
Pathak ²⁰	2022	USA	Retrospective	2	NR	NR	NR	NR	NR	NR	NR	NR	NR
RWT													
None													
HoLEP													
McAdams ¹³	2017	USA	Retrospective	7	80	8	NR	0	59	NR	NR	NR	NR
Das ⁴	2022	USA	Retrospective	22	90	14.4	NR	18.2	NR	9.1	-124	-5	8.3
Durant ²	2022	USA	Retrospective	24	NR	NR	NR	NR	NR	NR	NR	NR	NR
Assmus ⁷	2022	USA	Retrospective	22	104.8	NR	NR	7.7	NR	13.3	NR	-4.3	NR
David ¹⁴	2022	USA	Retrospective	1	84	NR	NR	0	NR	NR	NR	NR	NR
Parikh ²¹	2019	USA	Retrospective	3	NR	NR	NR	NR	NR	NR	NR	NR	NR
Iqbal ²²	2018	UK	Retrospective	1	NR	0.25	NR	0	NR	NR	NR	NR	NR

TFL													
Smith ²⁴	2021	USA	Retrospective	1	198	24	1	NR	NR	NR	NR	-10	43.9
PVP													
None													
PAE													
Tapping ²⁶	2017	UK	Retrospective	1	99	1	NR	NR	NR	NR	NR	-6	10

DRAFT