

Techniques – 14 Fr super-mini PCNL: How we do it

Thomas Fonseka, Alberto Melchionna, Nicolo De Luyk, Vimoshan Arumham, Simon Choong
Stone and Endourology Unit, Institute of Urology, University College London Hospitals NHS Foundation Trust, London, United Kingdom

Cite as: Fonseka T, Melchionna A, De Luyk N, et al. Techniques – 14 Fr super-mini PCNL: How we do it. *Can Urol Assoc J* 2023 July 11; Epub ahead of print. <http://dx.doi.org/10.5489/cuaj.8308>

Published online July 11, 2023

Corresponding author: Mr. Thomas Fonseka, Stone and Endourology Unit, Institute of Urology, University College London Hospitals NHS Foundation Trust, London, United Kingdom; T.Fonseka@NHS.net

INTRODUCTION

Fourteen French Super-mini PCNL (14Fr-SMP) is a key development in PCNL surgery and it has been adopted in many centres worldwide (1). With its unique suction feature, the technique has been refined and evolved since its original report in 2017 (2). We provide a step-by-step guide to 14Fr-SMP and report our surgical outcomes.

METHODS

The first 100 cases of 14Fr-SMP performed by a single surgeon at a tertiary referral stone centre in London, UK, were prospectively identified. Patient demographics and surgical outcomes were recorded. ‘Stone free’ was defined by the absence of renal calcifications > 2 mm at a one-month post-operative non-contrast CT KUB. IRB approval was not deemed to be required for this study.

Patient selection

Judicious patient selection is key to the success of PCNL (3). Indications for 14Fr-SMP are similar to standard PCNL, however, it may be more suitable for a stone burden generally <4 cm without multiple branches and in particular situations such as solitary stones within a diverticulum or patients with refractory stent symptoms who prefer to avoid a multi-staged ureterorenoscopy (4).

TECHNIQUE

Figure 1 demonstrates patient positioning and the layout of the operating room. At our institution we use the prone position, however, there is no high-level evidence to conclusively favour prone, supine or a modification of the two (5).

Renal access is obtained using ultrasound and fluoroscopic guidance and a Kellett drainage access catheter needle (Cook Medical). The Kellett needle is directed onto the stone and the sheath advanced over a guidewire. The sheath is replaced for a 4Fr biliary manipulation catheter over a super-stiff guidewire. The tract is dilated with fascial dilators from 6Fr to 14Fr (Figure 2). At 10Fr dilatation, a dual lumen catheter is inserted over the safety guidewire and allows for placement of a second Sensor safety wire down the ureter. The ClearPetra (Well Lead Medical Co., Ltd., China) 14Fr Super-mini access sheath (Figure

3), which is disposable after single use, is finally inserted with rubber bung and suction tubing attached.

The input and output of the irrigation fluid can be controlled separately. Usually, we programme the suction machine (Stryker Neptune™ (Stryker Corporation, Kalamazoo, Michigan)) to generate an irrigation pressure of approximately 142mmHg. Suction is used to control the intra-renal pressure and prevent over-heating, thus reducing the risks of renal injury and sepsis as well as achieving clear intra-operative vision.

The pressure vent on the suction port of the access sheath allows for continuous low-pressure passive suction and it is manually occluded to generate high-pressure active suction when desired. This feature enables continuous aspiration of stone fragments and overcomes gravitational force. With a faster flow of irrigation, higher powered lasers may be used with a lower risk of thermal injury.

A 7.5Fr ureteroscope or an 8Fr mini-nephroscope is inserted through the access sheath. Once the stones are visualised, the super-stiff guidewire can be removed, leaving the safety guidewire deployed down the ureter outside the sheath. This allows the sheath to move more freely and provides a bigger lumen to aspirate stone fragments. Stone fragmentation is performed using either a lithoclast or laser (Figure 4).

Larger stone fragments can be removed by high-pressure active suction and withdrawing the scope to just beyond a red line, marked on the inside of the sheath. This red line denotes where the oblique arm of the access sheath begins and allows the fragments to efflux out of the sheath and into the suction tubing (Figure 5). Fine dusting using the Thulium fibre laser allows more stone to be passively suctioned out, reducing the need to withdraw the scope and remove larger fragments.

Flexible nephroscopy and a retrograde pyelogram can be carried out to ensure there are no residual fragments. Finally, the scope and sheath are removed with 3 minutes of pressure applied to the wound and skin glue used to close.

The aim of 14Fr-SMP is always totally tubeless (6). However, a ureteric stent can be placed if there is any concern about post-operative ureteric obstruction due to factors such as; significant PUJ oedema caused by stone extending into the proximal ureter, any larger stone fragments or blood clots or if ipsilateral ureteroscopy was also performed. Indications to leave a nephrostomy in situ would include the presence of large pelvicalyceal blood clots or stone fragments (7).

Postoperative care

Intravenous fluids are administered overnight and patients can be discharged on day 1 if there are no clinical concerns. CT-KUB is performed at post-operative week 4 to confirm stone clearance.

RESULTS

Surgical outcomes are summarised in Table 1. Mean (SD) conglomerate stone diameter was 16.2 (9.55) mm (range = 4 to 60 mm). Mean (SD) operative time was 97.5 (33.1) mins and median length of stay was one 1 day (range = 1-11 days). Highest post-operative complication grade was Clavien-Dindo 3b. One patient developed post-operative hematuria which required general anesthetic cystoscopy and washout. In another patient the ureteric stent had perforated the renal parenchyma and this required a stent exchange. The majority of patients (85%) stayed in hospital for \leq 48h. Overall stone-free rate was 83% and 56% of cases were totally tubeless.

DISCUSSION

Our results demonstrate that 14Fr-SMP is both safe and efficacious. While standard PCNL often achieves stone-free rates > 95%, the lower rate in our series was still encouraging given the complexity of the patients referred to a tertiary stone centre (8). Of the patients who were not left totally tubeless, around half (n=20) had underlying anatomical or metabolic abnormalities that necessitated post-operative drainage. These included conditions such as; solitary functioning kidney, tight PUJ/ infundibulum, ureteric stricture, ileal conduit and bladder exstrophy.

The learning curve was found to be relatively short, as most of the surgical principles are similar to standard PCNL. Introducing any new surgical technique to a department can be challenging. However, with motivated theatre staff, specialist nurses and administrative support, our experience has been positive and we would encourage other units, not already performing 14Fr-SMP, to introduce it and establish it as another treatment option for select patients.

CONCLUSIONS

The development of super-miniaturised PCNL has bolstered the armamentarium of stone surgery. As technique is further refined, the benefits of less bleeding, less post-operative pain, reduced length of stay, and potentially less tubing will keep the procedure at the forefront of advances in PCNL (9).

DRAFT

REFERENCES

1. Zeng G, Wan S, Zhao Z et al. Super-mini percutaneous nephrolithotomy (SMP): a new concept in technique and instrumentation. *BJU Int.* 2016;117(4):655–61.
2. Zeng G, Zhu W, Liu Y et al. The new generation super-mini percutaneous nephrolithotomy (SMP) system: a step-by-step guide. *BJU Int.* 2017;120(5):735–8.
3. Michel MS, Trojan L, Rassweiler JJ. Complications in Percutaneous Nephrolithotomy. *Eur Urol.* 2007 Apr 1;51(4):899–906.
4. Zeid M, Sayedin H, Sridharan N et al. Super-Mini Percutaneous Nephrolithotomy for Nephrolithiasis: A Systematic Review and Meta-Analysis. *Cureus.* 2022;14(12).
5. Mak DKC, Smith Y, Buchholz N et al. What is better in percutaneous nephrolithotomy – Prone or supine? A systematic review. *Arab J Urol.* 2016 Jun 1;14(2):101–7
6. Liu Y, AlSmadi J, Zhu W et al. Comparison of super-mini PCNL (SMP) versus Miniperc for stones larger than 2 cm: a propensity score-matching study. *World J Urol.* 2018 Jun 1;36(6):955–61.
7. Zeng G, Zhang T, Agrawal M et al. Super-mini percutaneous nephrolithotomy (SMP) vs retrograde intrarenal surgery for the treatment of 1–2 cm lower-pole renal calculi: an international multicentre randomised controlled trial. *Bju Int.* 2018;122(6):1034–40.
8. Chung DY, Kang DH, Cho KS et al. Comparison of stone-free rates following shock wave lithotripsy, percutaneous nephrolithotomy, and retrograde intrarenal surgery for treatment of renal stones: A systematic review and network meta-analysis. *PLOS ONE.* 2019 Feb 21;14(2):e0211316.
9. Guddeti RS, Hegde P, Chawla A et al. Super-mini percutaneous nephrolithotomy (PCNL) vs standard PCNL for the management of renal calculi of < 2 cm: a randomised controlled study. *BJU Int.* 2020;126(2):273–9.

FIGURES AND TABLES

Figure 1. The layout of the operating room.

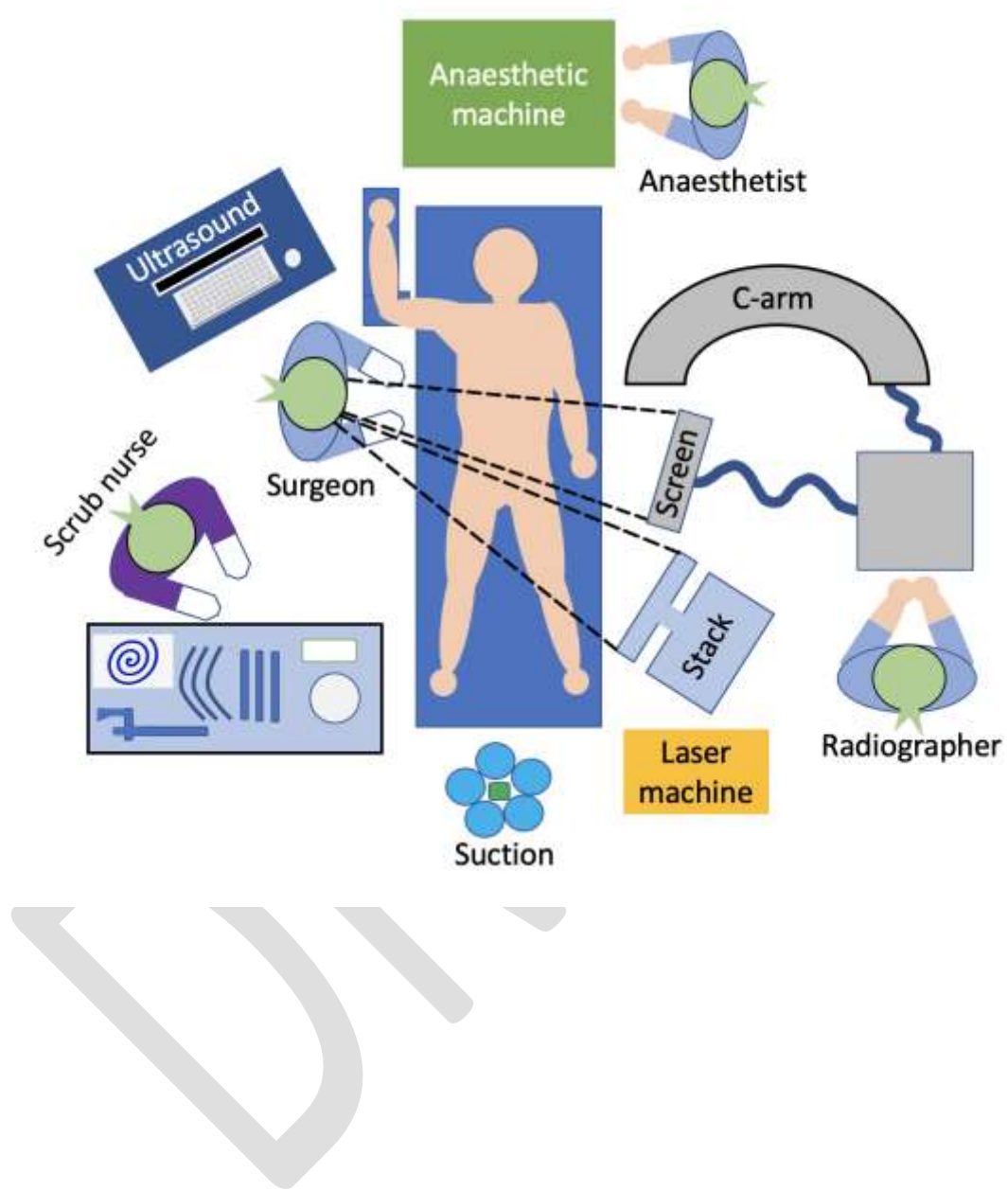


Figure 2. Serial fascial dilatation.

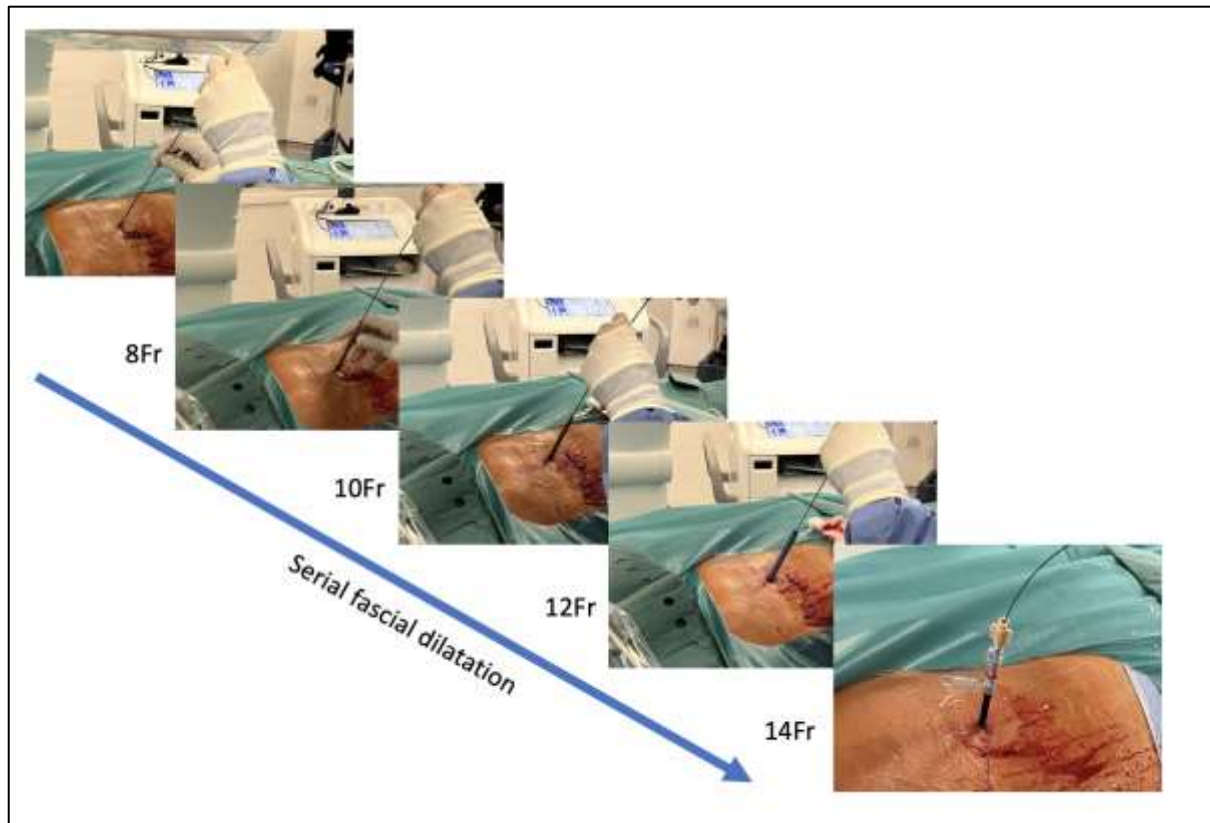


Figure 3. A schematic diagram of the 14 Fr super-mini access sheath.

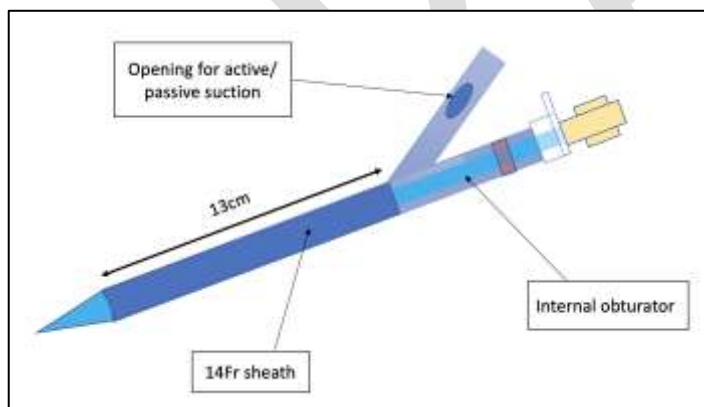


Figure 4. (a) Insertion of the nephroscope through the access sheath; (b) insertion of the lithoclast through the nephroscope.

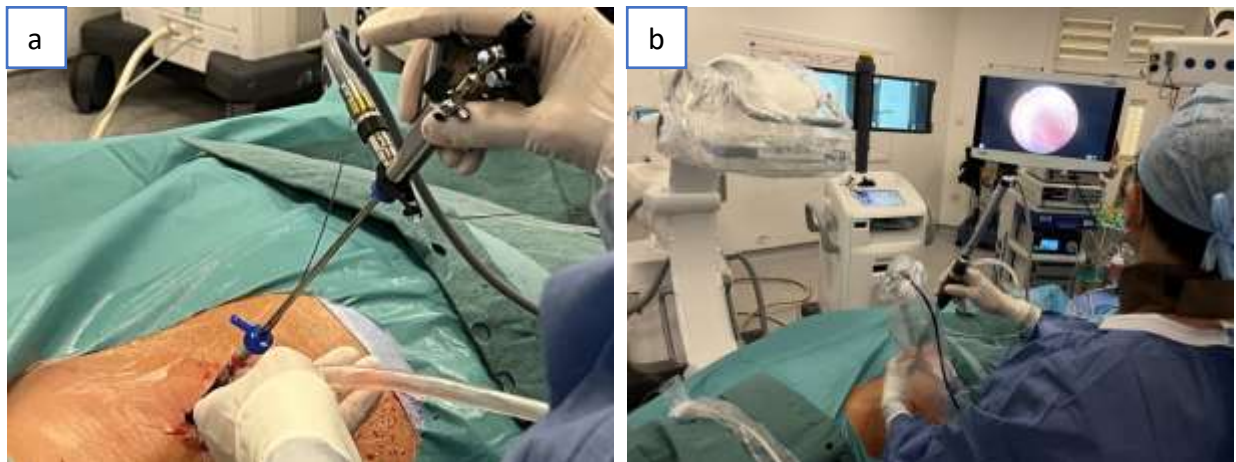


Figure 5. (a) Intra-operative view of the red line coming into view as the scope is withdrawn through the sheath; (b) a sideview photo to show the red line from the outside.

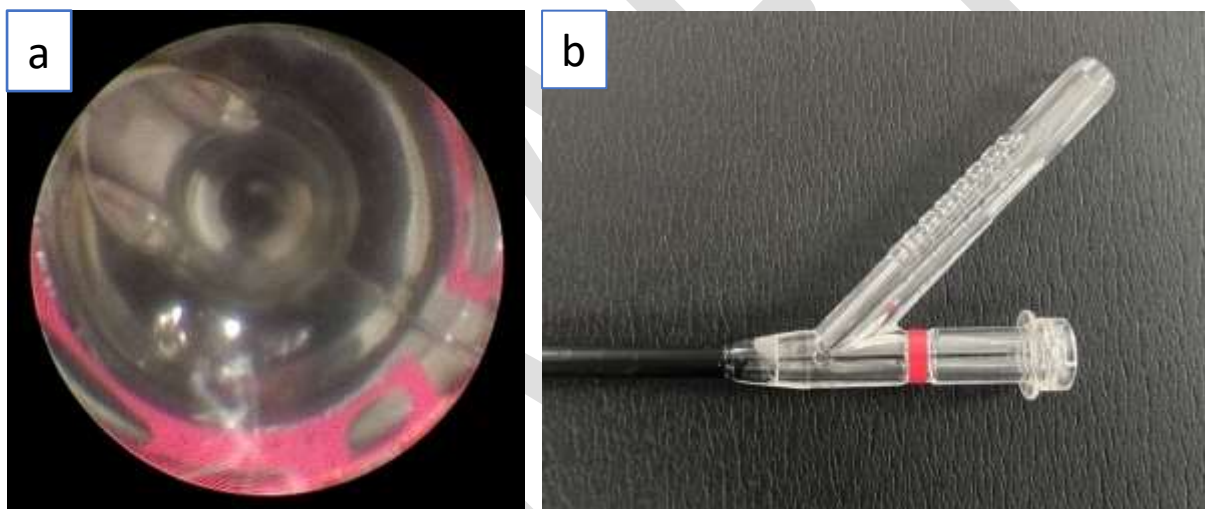


Table 1. Patient demographics, stone characteristics and surgical outcomes (N=100)			
Sex	Male		Female
	60 (60%)		40 (40%)
	Mean±SD	Range	
Age (years)	46.4±16.0		17–80
Body mass index (kg/m ²)	28.8±8.45		18.2–55
ASA grade	1.78±0.746		1–3
Conglomerate stone diameter (mm)	16.2±9.55		4–60
Operative time (minutes)	97.5±33.1		45–209
Length of stay (days)	1.77±1.76		1–11
Length of stay ≤ 48h (%)	85		
Postoperative complications (Clavien-Dindo) (No complications > grade 3b)	Grade 1	Grade 2	Grade 3b
	n=1 Pain (n=1)	n=6 Urosepsis (n=6)	n=2 Hematuria (cystoscopy + washout) Renal parenchyma perforated by stent (stent exchanged cystoscopically)
	Yes		No
Stone-free	83 (83%)		17 (17%)
Totally tubeless	56 (56%)		44 (44%) Nephrostomy (n=16) Stent (n=28)