

Case – Leuprolide acetate-induced necrotic skin ulceration

William C.I. Janes¹, Boluwaji Ogunyemi¹, Matthew Andrews²

¹Faculty of Medicine, Memorial University, St. John's, NL, Canada; ²Department of Urology, Memorial University, St. John's, NL, Canada

Cite as: Janes WCI, Ogunyemi B, Andrews M. Case – Leuprolide acetate-induced necrotic skin ulceration. *Can Urol Assoc J* 2022 October 25; Epub ahead of print.

<http://dx.doi.org/10.5489/cuaj.8112>

Published online October 25, 2022

Corresponding author: Dr. W.C. Ian Janes, 1Faculty of Medicine, Memorial University, St. John's, NL, Canada; wcij85@mun.ca

INTRODUCTION

Androgen deprivation therapy (ADT) has become a well-established modality in the management of locally advanced and metastatic prostate cancer.¹ Leuprolide acetate, a synthetically derived gonadotropin-releasing hormone receptor (GnRHR) agonist, is commonly used for ADT in men.² Despite proven effectiveness, the administration of GnRHR agonists is associated with common adverse reactions, such as impotence, hot flashes, and fatigue. Injection site reactions have also been documented, however, are infrequent, with the most common being localized pain.^{3,4} Here, we report a case of necrotic skin ulceration following multiple administrations of intramuscular leuprolide acetate.

CASE REPORT

A 63-year-old male of Nigerian ancestry with negligible past medical history presented to his primary care provider in June 2019 with urinary symptoms and rectal discomfort initially suspected as gastrointestinal in origin. Further testing revealed PSA 112 ng/ml warranting urgent urological consultation. Urgent 4-core transrectal ultrasound guided prostate biopsy revealed grade group 5, Gleason 9 (5+4) prostate cancer with 39% involvement of all core tissues. Staging computed topography (CT) identified several sub-centimeter indeterminate pulmonary nodules, while bone scan (Sept 2019) revealed absence of osseous metastases. Following multidisciplinary tumor board discussion, tri-monthly ADT was initiated via Leuprolide 22.5 mg subcutaneous (Eligard) injection and adjunctive external beam radiation therapy (7,600 cGy in 38 fractions of 200 cGy).

Following completion of radiotherapy in March 2020, PSA levels reached a nadir of 3 ng/mL before steadily rising despite ongoing hormonal castration. Repeat CT scan now revealed metastatic castrate-resistant prostate cancer with increasing number and size of pulmonary nodules. Enzalutamide 160 mg oral daily was subsequently added to the treatment regimen and PSA levels decreased to < 1 ng/mL. A follow-up CT scan in August 2020 showed decreased metastatic burden in the lungs.

Routine follow-up in October 2020 revealed increasing testosterone levels, at which time ADT was switched from subcutaneous to intramuscular leuprolide (Lupron 22.5 mg) in attempt to improve testosterone suppression. The first and second injections were delivered January and April 2021 in the right and left buttock, respectively, without complication. The patient received his third injection to the right buttock July 2021 and presented approximately one month later with an apparent injection site reaction. Physical exam identified a firm erythematous granuloma tender to palpation at the right buttock injection site which was draining a small amount of culture-negative purulent fluid (Figure 1). Conservative management ensued. The patient returned for his fourth Lupron injection, administered to the left buttock, in October 2021 at which time testosterone levels were non-castrate at 4.5 nmol/L. A subsequent left buttock skin reaction followed, similar in appearance to the contralateral right sided injection reaction, and accompanied by the development of a necrotic skin ulcer. The patient was referred to dermatology who agreed with diagnosis of necrotic skin ulceration at the Leuprolide injection site (Figure 1). The patient received wound care via community health services. A combination 0.25% menthol in betamethasone valerate 0.1% cream was prescribed for associated pruritus. As no active infection was noted, there was no necessity for oral antibiotics. At this point the patient continued with Enzalutamide monotherapy before later resuming ADT via subcutaneous leuprolide (Eligard 22.5mg) leaving wound healing by secondary intention. While other methods of ADT, such as alternative GnRHR agonists or GnRHR antagonists were considered, we elected resumption of Eligard due to patient preference and previous safe exposure with this agent. Subsequent PSA levels have remained steadily < 1 ng/mL. The patient has not experienced any further injection-related complications with Eligard and continues to be followed regularly.

DISCUSSION

Adverse events commonly associated with leuprolide acetate formulations typically correlate with hormonal imbalance and low-testosterone states.⁴ Injection site associated skin reactions are exceedingly rare.³ Indeed, we believe our case to be the first documenting necrotic skin ulceration following administration of intramuscular leuprolide acetate.

The development of foreign body granulomas is a comparable rare complication of leuprolide acetate injection with less than 100 reported cases globally.^{5,6} These granulomatous reactions have been infrequently documented in Western countries, with most published reports

within the Japanese literature.^{3,5,7} The noted discrepancy in incidence rates is believed secondary to greater use of subcutaneous injections in Japan compared to more frequent intramuscular routes in Western nations. Consequently, all reported cases of granuloma formation utilized a subcutaneous injection with suggestion that intramuscular administration may reduce such complications.^{6,8} Given an intramuscular administration was utilized in our case, these explanations cannot fully account for our observation.

Conversely, our case may be indicative of a type-IV delayed-type hypersensitivity reaction. It is important to consider the absence of reaction when treated with Eligard, another formulation of leuprolide acetate containing similar constituents, suggesting a reaction of this nature may not be due to the GnRHR agonist itself but possibly due to an excipient. Previous reports have described allergic reactions to the polylactic acid used as a vehicle in leuprolide that is not seen in other formulations and may provide some explanation for our observation.^{7,9} Further possibility exists that Lupron may have been a stronger immunogenic agent for this patient than was Eligard.

Occurrences of post-traumatic necrosis of the subcutaneous adipose tissue have been documented following blunt injury, surgery, and minor procedures such as injections.¹⁰ While there are no reports of the advent of necrosis following Lupron injections, there are reported cases of ulcerations following intramuscular injection of various other substances.^{11–13} Several of these reports have cited the occurrence of Nicolau syndrome, a rare complication of intramuscular injections causing local ischemic necrosis of skin and adipose tissue. It is possible our case may represent a minor occurrence of Nicolau syndrome as risk is closely correlated with injection site, muscle depth, and drug mechanism of action. Manifestations may range from purulent abscesses to tissue necrosis; both of which were observed in the present case.¹⁴

Potential for confounding variables are important considerations when postulating an explanation for any adverse drug reaction. In the present case, potential medication interactions were non-contributory as the patient maintained a stable medication regimen for greater than one year prior to these events. Furthermore, all injections were delivered by the patient's experienced urologist making the possibility of improper administration unlikely. The exact etiology of necrotic skin ulceration in this patient remains unclear.

CONCLUSIONS

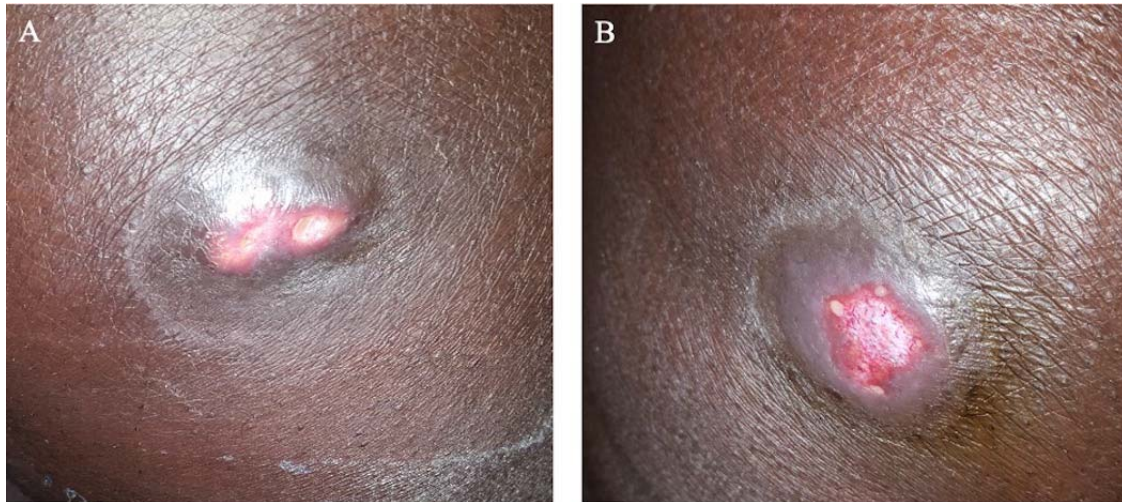
We describe what we believe to be the first case of injection site ulceration and skin necrosis following gluteal intramuscular administration of leuprolide acetate. Fellow clinicians should be aware of this rare adverse event.

References

1. Abouelfadel Z, Crawford ED. Leuprorelin depot injection: Patient considerations in the management of prostatic cancer. *Ther Clin Risk Manag* 2008;4:513-26. doi:10.2147/tcrm.s6863
2. Crawford ED, Heidenreich A, Lawrentschuk N, et al. Androgen-targeted therapy in men with prostate cancer: evolving practice and future considerations. *Prostate Cancer Prostatic Dis* 2019;22:24-38. doi:10.1038/s41391-018-0079-0
3. Oka D, Shiba M, Arai Y, et al. Skin reactions to 3-month depot type of luteinizing hormone-releasing hormone agonist therapy. *Japan Med Assoc J* 2006;49:48-54.
4. Kumar RJ, Barqawi A, Crawford ED. Adverse Events Associated With Hormonal Therapy for Prostate Cancer. *Rev Urol* 2005;7:S37-43. doi:10.1038/nrclinonc.2009.122
5. Suzuki T, Mukai H. Injection Site Granulomas Resulting from Administration of Leuprorelin Acetate. In: *Prostate Cancer - Original Scientific Reports and Case Studies* 2011:183-192. doi:10.5772/25392
6. Kawai M, Ikoma N, Yamada A, et al. A case of foreign body granuloma induced by subcutaneous injection of leuprorelin acetate - Clinical analysis for 335 cases in our hospital. *Tokai J Exp Clin Med* 2014;39:106-10.
7. Yasukawa K, Sawamura D, Sugawara H, et al. Leuprorelin acetate granulomas: Case reports and review of the literature. *Br J Dermatol* 2005;152:1045-7. doi:10.1111/j.1365-2133.2005.06341.x
8. Shiota M, Tokuda N, Kanou T, et al. Incidence rate of injection-site granulomas resulting from the administration of Luteinizing hormone-releasing hormone analogues for the treatment of prostatic cancer. *Yonsei Med J* 2007;48:421-4. doi:10.3349/ymj.2007.48.3.421
9. Jain A, Kunduru KR, Basu A, et al. Injectable formulations of poly(lactic acid) and its copolymers in clinical use. *Adv Drug Deliv Rev* 2016;107:213-27. doi:10.1016/j.addr.2016.07.002
10. Crawford EA, King JJ, Fox EJ, et al. Symptomatic fat necrosis and lipoatrophy of the posterior pelvis following trauma. *Orthopedics* 2009;32:444. doi:10.3928/01477447-20090511-25
11. Davies J, Lagattolla NRF, Scholey G. Fat necrosis associated with the subcutaneous injection of enoxaparin. *Postgrad Med J* 2001;77:43-4. doi:10.1136/pmj.77.903.43
12. Hanson P, Pandit M, Menon V, et al. Painful fat necrosis resulting from insulin injections. *Endocrinol Diabetes Metab Case Reports* 2014 Sep:7-10. doi:10.1530/edm-14-0073
13. McGee AM, Davison PM. Skin necrosis following injection of non-steroidal anti-inflammatory drug. *Br J Anaesth* 2002;88:139-40. doi:10.1093/bja/88.1.139
14. Dadaci M, Altuntas Z, Ince B, et al. Nicolau syndrome after intramuscular injection of non-steroidal anti-inflammatory drugs (NSAID) *Bosn J Basic Med Sci* 2015;14:57-60. doi:10.17305/bjbms.2015.1.190

Figures and Tables

Figure 1.



DRAFT