

Case — The folly of a misplaced Foley

Michael Uy¹, Michael Greenspan^{1,2}, Udi Blankstein^{1,2}

¹Division of Urology, Department of Surgery, McMaster University, Hamilton, ON, Canada; ²Hamilton General Hospital, Department of Urology, Hamilton, ON, Canada

Cite as: Uy M, Greenspan M, Blankstein U. Case — The folly of a misplaced Foley. *Can Urol Assoc J* 2022;16(11):E569-71. <http://dx.doi.org/10.5489/cuaj.7913>

Published online June 9, 2022

Introduction

Traumatic Foley catheterization and malplacement is a common urological consultation. Although most urethral injuries are self-resolving, there are reports of long-standing complications, including urethral strictures, false passage formation, fistulization, and penile necrosis.¹ We present a case of a malpositioned Foley catheter leading to the formation of a dorsal penile artery pseudoaneurysm resulting in transfusion-dependent anemia and severe urethrorrhagia.

Case report

A 33-year-old male patient with acute renal failure of unknown etiology was admitted to the nephrology service. He had no prior medical history or urological issues. Foley catheter was placed for 24-hour urinary profiles, although the patient subsequently developed gross hematuria. Catheter was left in situ for several days with continuous bladder irrigation until it was determined that the catheter was malpositioned in the urethra, and he had subsequent cystoscopic placement of a 16 French council tip Foley catheter. Cystoscopy was unremarkable but there was significant bleeding that obscured visualization. Unfortunately, even after proper Foley placement, he continued to have severe gross hematuria and significant urethral bleeding.

He underwent right renal biopsy for diagnostic purposes of his renal failure but afterwards, he was transferred to a tertiary hospital system for possible embolization of the right kidney post-biopsy due to ongoing hematuria and transfusion-dependent anemia. Computed tomography (CT) angiography yielded no evidence of active arterial extravasation from the right kidney. Believing the bleeding was prostatic, he was seen by the urology team at the secondary hospital, and eventually had his 16 French Foley upsized to a 24 French three-way

Foley catheter in order to optimize continuous bladder irrigation and tamponade query prostatic bleeding.

Profuse and pulsatile urethral bleeding was observed during Foley replacement. Given the concerning urethral bleeding, the original CT angiography was reviewed, which identified a pseudoaneurysm from his left dorsal penile artery with active contrast extravasation into his urethra (Figure 1). He was taken for urgent interventional radiology embolization using gelfoam slurry and a 4 mm VortX coil (Boston Scientific, Natick, MA, U.S.) (Figure 2). The procedure itself was uncomplicated and his gross hematuria and urethral bleeding subsided.

Discussion

Pseudoaneurysm development in urological care is uncommon but typically occurs in the kidney, bladder, or prostate from surgical manipulation.² This malformation occurs when there is disruption of an artery, with resultant patent flow in a defined space beyond the confines of the vessel.² Even more exceedingly rare, pseudoaneurysm development of the arterial supply of the urethra from a Foley injury has seldom been reported.³⁻⁵ It is thought that pressure necrosis of the urethral wall from the Foley balloon is the main culprit of these arterial malformations.³ There are only three other reported cases of urethrorrhagia from a bleeding pseudoaneurysm due to Foley malposition,³⁻⁵ and review of these cases are pertinent in order to accurately diagnose and manage this rare condition.

Clinical identification of a urethral pseudoaneurysm may be challenging. Typically, most small pseudoaneurysms self-resolve with thrombosis and are clinically silent, though the ones that progress may lead to rupture and subsequent urethrorrhagia. As such, the symptomatology of urethral pseudoaneurysms is variable. From reports, patients may present with intermittent urethrorrhagia and likely hematuria from retrograde reflux of urethral bleeding. In our case, during catheter exchange, profuse urethral bleeding with pulsation immediately raised suspicion for vascular injury. Moreover, bladder irrigation was noted to be only mildly hematuric, but copious amounts of snake-like peri-Foley catheter clots further alluded to this vascular malformation. Confirmatory

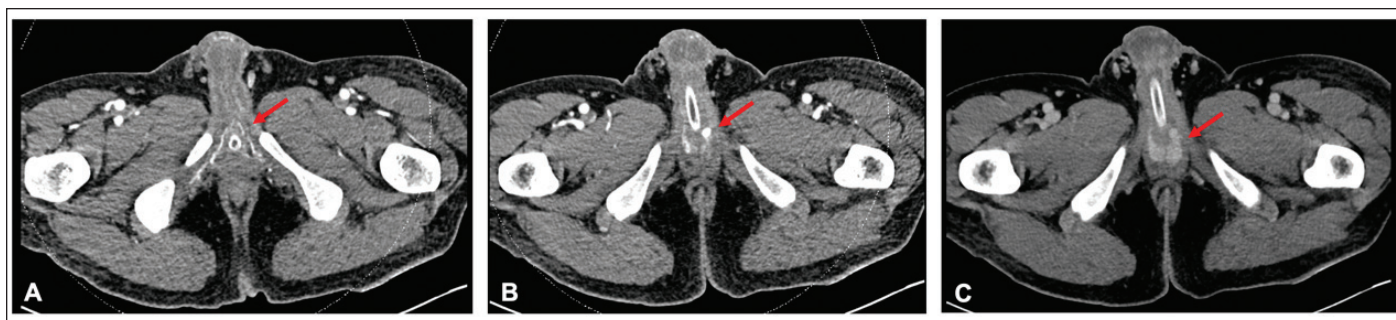

Figure 1. Computed tomography angiography, transverse section at the level of the pelvis. **(A)** Left dorsal artery on arterial phase (arrow); **(B)** pseudoaneurysm of left dorsal artery (arrow); **(C)** Contrast pooling in bulbar urethra on 10 second delayed contrast phase (arrow).

diagnosis is typically made by diagnostic imaging in the form of CT angiography and, at times, focused ultrasound or invasive angiography.⁶ In their case, Bettez et al highlighted a cystoscopic diagnosis of a pulsatile mass within the bulbar urethra.⁵ Regardless of diagnostic strategy, it is imperative to have prompt and timely recognition of this complication.

Management options for urethral pseudoaneurysms diverge from common strategies for treatment of these malformations in other areas of the body, as even small urethral aneurysms may lead to significant hemorrhage. As such, conservative recommendations for pseudoaneurysms <1 cm may not be applicable for urethral malformations.⁶ We hypothesize ultrasound-guided compression with or without thrombin injection may be conducted, but due to the rare nature of this finding, there are no reports of such treatment. Interestingly, Radhakrishnan et al temporized bleeding by using transperineal pressure.³ Endoscopic management

may be approached by fulgurating any visual bleeding on transurethral assessment,⁷ although this may lead to further urethral necrosis. Given the lack of experience in alternative management strategies, interventional radiology-guided embolization remains the gold standard. Identification and super-selective coiling can lead to effective treatment for even small aneurysms. Success with coiling was found in all three previous reports.³⁻⁵

We elected to keep our patient's Foley catheter for two weeks to allow for subsequent urethral healing, and removal of the catheter yielded no bleeding. Other authors have elected to use suprapubic catheterization for six weeks, with followup urethrogram to rule out stricture formation.³ Long-term outcomes of patients with urethral pseudoaneurysms are not well-reported. There is speculation that due to the loss of erectile vasculature, subsequent dysfunction may be noted, although a review of cavernosal pseudoaneurysms coiling for erectile dysfunction found that, in most cases, erectile function was normal at followup.⁸

Conclusions

Catheter placement is a common medical procedure but malposition may lead to severe complications. We present a case of a malpositioned Foley catheter leading to the formation of a dorsal penile artery pseudoaneurysm resulting in transfusion-dependent anemia needing arterial embolization. Prompt identification and diagnosis can lead to appropriate and timely management of this rare presentation.

Competing interests: The authors do not report any competing personal or financial interests related to this work.

This paper has been peer-reviewed.

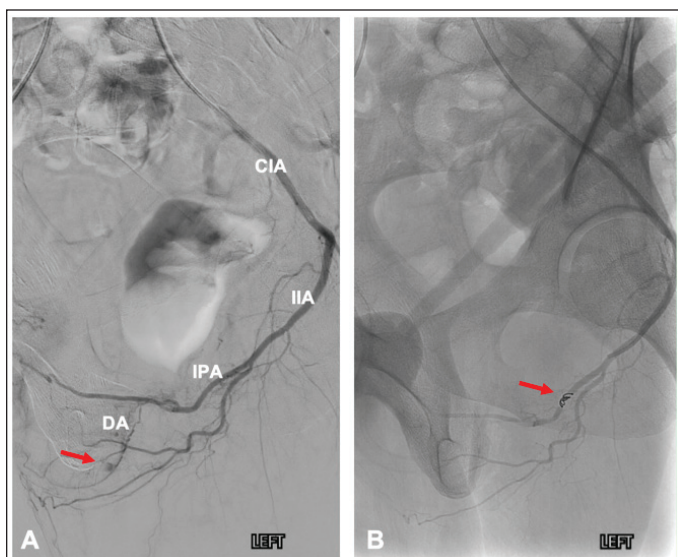


Figure 2. Angiographic images during interventional radiology-guided super-selective embolization. **(A)** Urethral pseudoaneurysm and contrast blush (arrow); **(B)** coiling of an afferent branch from the internal pudendal (arrow) with resolution of extravasation. CIA: common iliac artery; DA: dorsal artery; IIA: internal iliac artery; IPA: internal pudendal artery.

References

1. Serrano Durba A, Rodrigo Guanter V, Bon Beneto F, et al. The role of urethral catheterization in penile necrosis. *Actas Urol Esp* 1999;23:444-6.
2. Sutherland DE, Williams SB, Rice D, et al. Vascular pseudoaneurysms in urology: Clinical characteristics and management. *J Endourol* 2010;24:915-21. <https://doi.org/10.1089/end.2009.0662>
3. Radhakrishnan S, Marsh R, Sheikh N, et al. Urethral catheter induced pseudoaneurysm of the bulbar artery. *Int J Urol* 2005;12:922-4. <https://doi.org/10.1111/j.1442-2042.2005.01176.x>
4. Liang LM-S, Xue J, Erturk E. Perineal pseudoaneurysm from traumatic Foley removal leads to recurrent life-threatening hematuria. *J Endourol Case Rep* 2015;1:50-1. <https://doi.org/10.1089/cren.2015.0009>
5. Bettez M, Aubé M, Sherbiny M El, et al. A bulbar artery pseudoaneurysm following traumatic urethral catheterization. *Can Urol Assoc J* 2017;11:E47-9. <https://doi.org/10.5489/cuaj.4050>
6. Kapoor BS, Haddad HL, Saddekni S, et al. Diagnosis and management of pseudoaneurysms: An update. *Curr Probl Diagn Radiol* 2009;38:170-88. <https://doi.org/10.1067/j.cpradiol.2008.11.001>
7. Schober JP, Iqbal S, Marcantonio A, et al. Endoscopic management of a trauma-induced urethral pseudoaneurysm. *Endourology* 2019;5:96-8. <https://doi.org/10.1089/cren.2018.0116>
8. Masterson JM, Savio LF, Softness K, et al. Successful management of cavernosal artery pseudoaneurysm using microcoil embolization. *Transl Androl Urol* 2017;6:973. <https://doi.org/10.21037/tau.2017.08.16>

Correspondence: Dr. Udi Blankstein, Division of Urology, Hamilton General Hospital, Hamilton, Canada; udi.blankstein@medportal.ca