

**Case – Testicular thigh pouches for severe Fournier's gangrene: A how-to guide**

Justin Loloi<sup>1</sup>, Josh Gottlieb<sup>1</sup>, Susan M. MacDonald<sup>3</sup>, Ahmed Aboumohamed<sup>1</sup>, Joseph A. Ricci<sup>2</sup>, Melissa Laudano<sup>1</sup>, Kara Watts<sup>1</sup>

<sup>1</sup>Department of Urology, Montefiore Medical Center, Albert Einstein College of Medicine, Bronx, NY, United States; <sup>2</sup>Department of Plastic and Reconstructive Surgery, Montefiore Medical Center, Albert Einstein College of Medicine, Bronx, NY, United States; <sup>3</sup>Department of Urology, Penn State Health Milton S. Hershey Medical Center, Hershey, PA, United States

**Cite as:** Loloi J, Gottlieb J, MacDonald SM, et al. Case – Testicular thigh pouches for severe Fournier's gangrene: A how-to guide. *Can Urol Assoc J* 2022 May 20; Epub ahead of print. <http://dx.doi.org/10.5489/cuaj.7901>

Published online May 20, 2022

**Corresponding author:** Dr. Kara Watts, Department of Urology, Montefiore Medical Center, Albert Einstein College of Medicine, Bronx, NY, United States; [kwatts@montefiore.org](mailto:kwatts@montefiore.org)

\*\*\*

**Abstract**

Fournier's gangrene is a surgical emergency that requires prompt debridement of infected tissue. When the majority of scrotum has been resected, placing the testicles into thigh pouches can allow for improved wound granulation/contracture prior to definitive tissue reconstruction. We present a surgical guide on how to create testicular thigh pouches without the use of thigh counter-incisions, and its utility in delayed wound healing for large scrotal wounds. This technique may serve as a valuable adjunct in the urologist's and plastic surgeon's armamentarium to optimize testicular coverage and subsequent genital reconstruction.

**Case: Testicular thigh pouches for severe Fournier's gangrene****Introduction**

Fournier's gangrene is a rare but well documented surgical emergency that requires prompt debridement of infected tissue. Mortality rates approach 25-35% in recent series.<sup>1</sup> These cases often require multiple debridements making final reconstruction/wound coverage a challenge.<sup>2</sup>

In severe cases involving extensive loss of scrotal or perineal skin, reconstructive options typically include split-thickness grafts, local fasciocutaneous or musculocutaneous flaps, free flaps, use of tissue expanders, or any combination of these.<sup>3</sup> Placing the testicles in thigh pouches is a previously described approach that can be performed after the acute debridement to help with wound closure. Although split thickness skin grafting has become more popular in recent years, this approach is particularly useful when the majority or entirety of the scrotum has been resected. Thigh pouches may decrease morbidity in the skin graft site and decrease the time required for wound healing. Okwuldili et al. described 12 patients with >50% loss of scrotal skin after debridement underwent testicular thigh pouches in order to assist in scrotal wound granulation, thus preventing the need for complex reconstructive procedures.<sup>3</sup>

We herein report a surgical guide on how to create testicular thigh pouches without the use of thigh counter-incisions in a patient with a particularly extensive case of Fournier's gangrene requiring total penectomy and complete excision of scrotal tissue.

**Case report**

A 58 year-old male presented to the emergency room with severe penoscrotal Fournier's gangrene originating in the corpus spongiosum secondary to an obstructing calculus in the distal urethra (Figure 1). The patient had a history of active intravenous drug use and reported an inability to void for 5 days prior to presentation in our emergency room. Computerized tomography scan in the emergency department at presentation showed extensive gas around the penis extending into the corpora cavernosa and spongiosum. Gas was also seen tracking along the perineum with extension around the prostate gland. In addition, there was a 10 mm calcification at the tip of the penis/urethra, consistent with a urethral stone (Figure 1B, 1C, 1D). On hospital day (HD) #1, he was promptly taken to the operating room for surgical debridement. Intra-operatively, he was noted to have complete liquefactive necrosis of the anterior urethra, corpus spongiosum and corpora cavernosa distal to the verumontanum. He underwent extensive debridement including a total penectomy to the level of the pubic bone. Additionally, there was severe compromise of the entire scrotal skin. Bilateral testes were uninvolved. The urine was diverted via suprapubic catheter. The perineum was involved in both superficial and deep layers; however, the anus and rectum were uninvolved and thus fecal diversion was not performed. The inferior margin of the wound was approximately 3cm superior to the anal verge.

Following the initial debridement, on HD #3 and #9, the patient was subsequently taken to the operating room for two additional debridements. After the third debridement and examination under anesthesia for reconstructive planning, the wound surface area appeared too broad to close primarily. The testes overlying the perineal wound would prevent optimal

**Case: Testicular thigh pouches for severe Fournier's gangrene**

functioning and results of the wound vacuum device. We then decided to proceed with bilateral thigh pouches to allow for maximal wound granulation and contracture via wound vacuum placement prior to definitive reconstruction. We herein describe our technique for placement of bilateral testes into anteromedial thigh pouches without the use of a thigh counter-incision. Informed consent was obtained from the patient to allow for the presentation of the case.

**Surgical technique**

Figure 2 reveals the chronological steps taken to perform bilateral testicular pouches without the need for a thigh counter-incision. The patient was placed in a relaxed dorsal lithotomy position for visualization. Initial dissection involved freeing both testes and spermatic cords from the surrounding granulation and fibrinous tissue. The spermatic cords were mobilized to the level of the external inguinal rings (Figure 2A, 2B). Once at the level of the groin just distal to the external ring, the adductor longus tendon was palpated and blunt dissection with the surgeon's finger was performed superior to this anatomic landmark, developing a plane below the dermis and fat in the anteromedial thigh compartment, taking care to stay anterior to the fascia lata (Figure 2C). Once adequate space was developed, the space was carefully inspected for hemostasis. The testes were then placed directly lateral into the pouch ensuring no twisting or acute angulation of the spermatic cord (Figure 2D, 2E). The testes were directed anterior to the adductor longus muscle at the medial aspect of the femoral triangle. The thigh pouch location was carefully inspected to ensure there was no tension on the spermatic cords or testes. 3-0 Vicryl interrupted sutures were used to reapproximate the subcutaneous tissue around the cord as it entered the pouch in order to prevent proximal testicular migration. Thereafter, we maneuvered and flexed the legs while under anesthesia to confirm adequate mobility of, and lack of tension on, his testicles in order and to ensure there would be no impingement with thigh flexion.

The urethra was also inspected via flexible cystourethroscopy and confirmed no corpus spongiosum was present distal to the verumontanum. Despite suprapubic catheter drainage, urine leakage into the perineum may complicate wound healing and hinder the success of skin grafts or flaps during final reconstruction. To prevent these complications, the distal prostatic urethra was closed with 2-0 vicryl suture. The bladder was then instilled with normal saline via suprapubic catheter and confirmed no urine leakage distally into the wound.

Once complete (Figure 2F), the wound defect was more favorable and the plastic surgery team was able to optimally place a wound vacuum device flush with the entire wound base creating a good seal. After five days of vacuum seal, methylene blue was instilled into the bladder via suprapubic tube, and no blue coloration was seen within the wound vacuum collection cannister. Ultimately, the patient was managed with a wound vacuum system for approximately three weeks with resulting formulation of healthy-appearing granulation tissue prior to undergoing reconstruction with an anterolateral thigh split-thickness skin graft (Figure 3).

**Case: Testicular thigh pouches for severe Fournier's gangrene**

On follow up, the patient recovered well with satisfactory cosmetic effect and patient satisfaction. He had no reported difficulty with ambulation and denied testicular pain or discomfort. There is no current plan for scrotal reconstruction with a meshed graft.

**Discussion**

The aim of this report is to highlight a particularly destructive case of Fournier's gangrene and to introduce a viable and effective reconstructive option for testicular coverage. The technique described is particularly useful in extensive cases of Fournier's gangrene wherein the majority or entirety of the perineum and scrotum is debrided. With this technique in the urologist's armamentarium, we can offer patients with severe Fournier's gangrene additional measures for reconstruction in the setting of extensive tissue loss.

Although the scrotal tissue exhibits potent elasticity and compliance allowing for primary repair despite large tissue loss (> 75%),<sup>4</sup> Fournier's gangrene can result in extensive tissue loss either from the initial infection or the multiple debridements that may be required.<sup>5,6</sup> In addition to potentially large wounds, these patients often have comorbidities that further impair wound healing.

Testicular thigh pouches were first reported in the early 1980s as a practical means of attaining acceptable cosmetic appearance with preservation and maintenance of testicular function.<sup>7</sup> Specifically, testicular coverage serves as an important consideration given its potential impact on testicular physiologic function (spermatogenesis and hormone production) and mental/emotional well-being.<sup>8</sup>

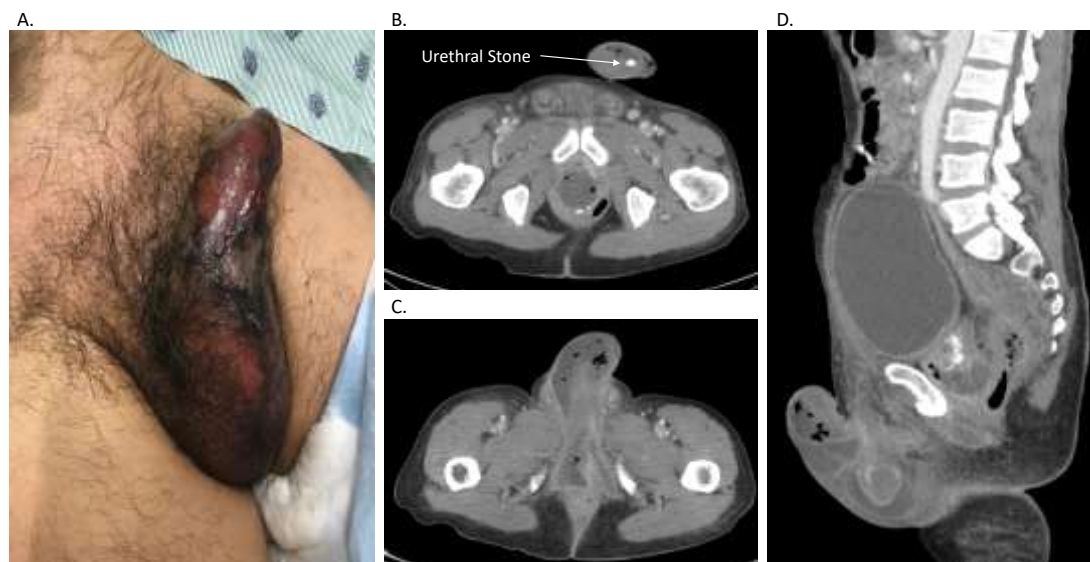
In recent years, thigh flaps and techniques utilizing local tissue rearrangements with the remaining scrotal tissue have gained favor.<sup>9,10</sup> However, in unusually advanced and severe cases of necrotizing infection where repeated debridements and delayed closure are necessary to promote wound granulation to allow for definitive reconstruction, we believe testicular thigh pouches still serve a valuable purpose. As highlighted above, this technique provides a relatively simple, but effective means of protecting the testes, reducing the surface area required for skin grafting, and potentially reducing overall recovery time given the smaller wound defect and ability to employ a wound vacuum dressing. Ultimately, the testes may be left in the thigh pouches indefinitely or mobilized back to the perineum at the time of grafting/closure depending on patient preference.

## References

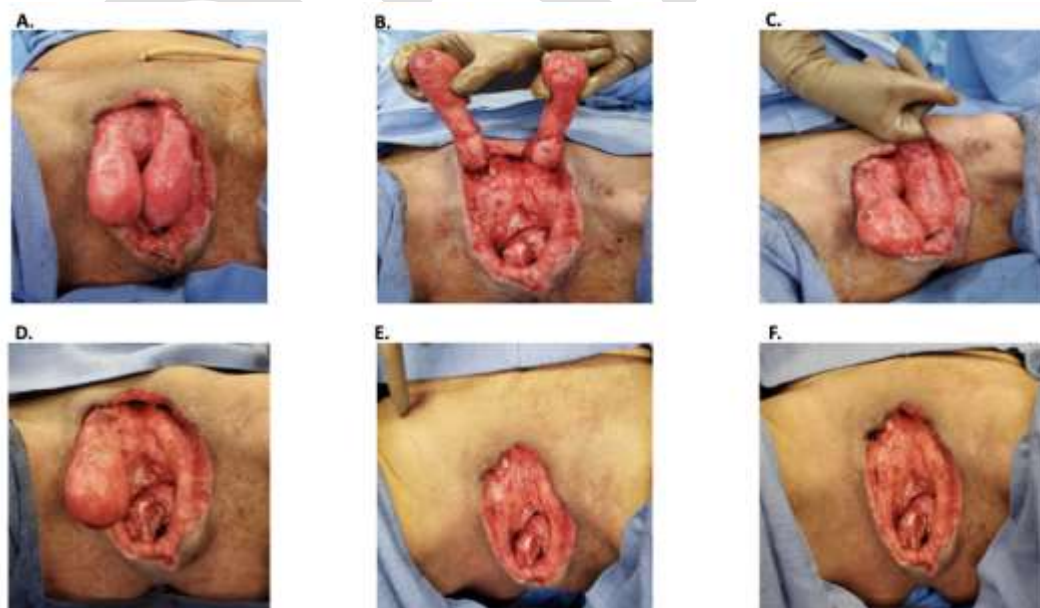
1. Hakkarainen TW, Kopari NM, Pham TN, et al. Necrotizing Soft Tissue Infections: Review and Current Concepts in Treatment, Systems of Care, and Outcomes. *Curr Probl Surg*. 2014;51(8):344-362. doi:10.1067/j.cpsurg.2014.06.001
2. Hagedorn JC, Wessells H. A contemporary update on Fournier's gangrene. *Nat Rev Urol*. 2017 Apr;14(4):205-214. doi: 10.1038/nrurol.2016.243. Epub 2016 Dec 13. PMID: 27958393.
3. Okwudili OA. Temporary Relocation of the Testes in Anteromedial Thigh Pouches Facilitates Delayed Primary Scrotal Wound Closure in Fournier Gangrene With Extensive Loss of Scrotal Skin-Experience With 12 Cases. *Ann Plast Surg*. 2016 Mar;76(3):323-6. doi: 10.1097/SAP.0000000000000505. PMID: 25785387.
4. Kwon EO, Pareek G, Fracchia JA, et al. Scrotal reconstruction using rapid intraoperative tissue expansion: a preliminary report. *J Urol*. 2008 Jan;179(1):207-9. doi: 10.1016/j.juro.2007.08.129. Epub 2007 Nov 14. PMID: 18001793.
5. Karian LS, Chung SY, Lee ES. Reconstruction of Defects After Fournier Gangrene: A Systematic Review. *Eplasty*. 2015 May 26;15:e18. PMID: 26171090; PMCID: PMC4447098.
6. Chennamsetty A, Khourdaji I, Burks F, et al. Contemporary diagnosis and management of Fournier's gangrene. *Ther Adv Urol*. 2015 Aug;7(4):203-15. doi: 10.1177/1756287215584740. PMID: 26445600; PMCID: PMC4580094.
7. McDougal WS. Scrotal reconstruction using thigh pedicle flaps. *J Urol*. 1983 Apr;129(4):757-9. doi: 10.1016/s0022-5347(17)52343-5. PMID: 6842695.
8. Yu P, Sanger JR, Matloub HS, et al. Anterolateral thigh fasciocutaneous island flaps in perineoscrotal reconstruction. *Plast Reconstr Surg*. 2002 Feb;109(2):610-6; discussion 617-8. doi: 10.1097/00006534-200202000-00030. PMID: 11818843.
9. Yao H, Zheng D, Wen J, et al. Reconstruction of major scrotal defects by anterolateral thigh flap. *Cell Biochem Biophys*. 2014 Nov;70(2):1331-5. doi: 10.1007/s12013-014-0060-z. PMID: 25022463.
10. Mopuri N, O'Connor EF, Iwuagwu FC. Scrotal reconstruction with modified pudendal thigh flaps. *J Plast Reconstr Aesthet Surg*. 2016 Feb;69(2):278-83. doi: 10.1016/j.bjps.2015.10.039. Epub 2015 Nov 18. PMID: 26774357.

## Figures and Tables

**Figure 1.** Initial presentation of Fournier's gangrene: (A) Physical presentation. (B, C, D) Computed tomography scan findings.



**Figure 2.** Surgical steps. (A) Testes/spermatic cords overlying wound base encased in granulation tissue. (B) Spermatic cords dissected free to the level of external inguinal ring. (C) Blunt dissection carried into the anteromedial thigh along the fascia lata. (D) Left testis placed within anteromedial thigh pouch. (E) Right testis placed within anteromedial thigh pouch. (F) Wound base optimized for placement of wound vacuum device.



**Figure 3.** Status post-reconstruction with an anterolateral thigh split-thickness skin graft.

