

⁶⁸Ga-prostate-specific membrane antigen positron emission tomography/computed tomography for patients with favorable intermediate-risk prostate cancer

Snir Dekalo^{1,2,3}, Jonathan Kuten^{2,4}, Jeffrey Campbell⁵, Ishai Mintz^{1,2}, Yuval Bar-Yosef^{1,2}, Daniel Keizman^{2,5}, David Sarid^{2,5}, Einat Even-Sapir^{2,5}, Ofer Yossepowitch^{1,2}, Roy Mano^{1,2}

¹Department of Urology, Tel-Aviv Sourasky Medical Center, Tel Aviv, Israel; ²Sackler School of Medicine, Tel-Aviv University, Tel Aviv, Israel; ³Department of Surgery, Western University, London, ON, Canada; ⁴Department of Nuclear Medicine, Tel Aviv Sourasky Medical Center, Tel Aviv, Israel; ⁵Department of Oncology, Tel Aviv Sourasky Medical Center, Tel Aviv, Israel

Cite as: Dekalo S, Kuten J, Campbell J, et al. ⁶⁸Ga-prostate-specific membrane antigen positron emission tomography/computed tomography for patients with favorable intermediate-risk prostate cancer. *Can Urol Assoc J* 2022;16(7):E381-5. <http://dx.doi.org/10.5489/cuaj.7739>

Published online February 28, 2022

Abstract

Introduction: Current guidelines do not support the use of pretreatment imaging in patients with favorable intermediate-risk prostate cancer. ⁶⁸Ga-prostate-specific membrane antigen positron emission tomography/computed tomography (PSMA PET/CT) is more accurate than conventional imaging for preoperative staging. We aimed to evaluate whether pretreatment ⁶⁸Ga-PSMA PET/CT is beneficial for identifying pathological lymph node involvement (LNI) and adverse pathology among patients with favorable intermediate-risk prostate cancer.

Methods: We reviewed 88 patients with favorable intermediate-risk prostate cancer who underwent ⁶⁸Ga-PSMA PET/CT prior to radical prostatectomy and lymph node dissection from 2016–2020. The primary endpoint was the presence of pathological LNI. Association between pretreatment characteristics and outcomes were evaluated.

Results: Preoperative ⁶⁸Ga-PSMA PET/CT showed suspicious uptake in lymph nodes in 4/88 patients (5%), hence, 20 patients would need to be scanned to identify a patient with a positive lymph node on imaging. Two patients had pathological LNI, only one of whom showed ⁶⁸Ga-PSMA PET/CT uptake prior to surgery. The sensitivity, specificity, positive predictive value, and negative predictive values of ⁶⁸Ga-PSMA PET/CT for identifying LNI were 50%, 97%, 25%, and 99%, respectively. After surgery, four patients had evidence of prostate-specific antigen (PSA) persistence. The rate of PSA persistence was higher among patients with LNI on preoperative ⁶⁸Ga-PSMA PET/CT (2/4, 50% vs. 2/84, 2%, $p=0.009$).

Conclusions: Preoperative imaging of favorable intermediate-risk prostate cancer patients using ⁶⁸Ga-PSMA PET/CT showed a low yield for identifying patients at higher risk. Consistent with current guidelines, our findings do not support the routine use of PET/CT in this group of patients. Future prospective studies are needed to validate our findings.

Introduction

Pretreatment imaging of patients diagnosed with prostate cancer is aimed at identifying lymph node involvement and distant metastases, which are more common in patients with higher tumor stage and grade, and influence treatment options.^{1,2} Pretreatment staging recommendations intend to reduce routine imaging in men with low-risk of distant disease; therefore, current guidelines do not recommend the use of routine conventional imaging for staging men with favorable intermediate-risk prostate cancer.³⁻⁵ However, data regarding the diagnostic yield of imaging in the pretreatment setting for prostate cancer are based mainly on studies using computed tomography (CT) scans of the abdomen and pelvis and bone scintigraphy.^{6,7}

⁶⁸Ga-prostate-specific membrane antigen positron emission tomography/computed tomography (⁶⁸Ga-PSMA PET/CT) is evolving as a more accurate method for staging prostate cancer.^{8,9} Several studies evaluated the preoperative use of ⁶⁸Ga-PSMA PET/CT within the context of high-risk patients, supporting its role in disease staging with a higher accuracy compared to conventional imaging.¹⁰ Consistent with these findings, the FDA has approved the use of PSMA PET/CT for the staging of high-risk patients. Less is known regarding the role of ⁶⁸Ga-PSMA PET/CT for the pretreatment staging of patients with intermediate-risk disease, especially in men diagnosed with favorable intermediate-risk prostate cancer.

In this study, we investigated the role of preoperative ⁶⁸Ga-PSMA PET/CT in a group of patients with favorable intermediate-risk prostate cancer who underwent radical prostatectomy and lymph node dissection. Specifically, we aimed to evaluate whether this novel modality can accurately identify patients who harbor higher risk or more advanced disease, justifying its use in this subgroup of prostate cancer patients.

Methods

After obtaining institutional review board approval, we identified 117 patients with National Comprehensive Cancer Network (NCCN) favorable intermediate-risk prostate cancer who underwent ^{68}Ga -PSMA PET/CT prior to treatment with radical prostatectomy between the years 2016 and 2020. According to the NCCN definition of favorable intermediate-risk prostate cancer,³ all patients had no high-risk or very-high-risk features and had one of the following intermediate-risk factors: clinical stage T2b or T2c, Gleason grade group 2 cancer, and a prostate-specific antigen (PSA) value of 10–20 ng/mL. In addition, all patients had <50% positive biopsy cores. Patients with multiple intermediate risk factors were not included in the cohort. Twenty-nine patients who did not undergo pelvic lymph node dissection at time of radical prostatectomy were excluded from the study cohort, leaving a total of 88 patients for further analyses.

Baseline patient and tumor characteristics were collected, including age, clinical stage based on digital rectal examination, pre-biopsy PSA score (ng/mL), biopsy Gleason grade group, total number of biopsy cores obtained, and number of positive biopsy cores. The risk of lymph node involvement (LNI) at radical prostatectomy was calculated for each patient using the nomogram developed by Gandaglia et al,¹¹ which included preoperative PSA, clinical T-stage, biopsy Gleason grade group, percentage of cores with highest-grade prostate cancer, and percentage of cores with lower-grade disease.

Prior to treatment, all patients underwent a PET/CT scan with ^{68}Ga -PSMA-11 (^{68}Ga -HBED-CC) used as the PSMA ligand. PET images were reconstructed by means of an ordered-subsets expectation-maximization algorithm. CT data were used for attenuation correction. Images were reported by high-volume dedicated nuclear medicine readers. Lesions with increased tracer uptake above background were considered positive. We obtained data regarding the number of men identified with PET-positive lymph node on imaging. In patients with positive lymph nodes, we noted the number of positive nodes and the short axis diameter (cm) of the largest lymph node.

All patients underwent robotic-assisted radical prostatectomy and bilateral pelvic lymph node dissection. None of the patients received neoadjuvant treatment. Surgical specimens were reviewed by a dedicated genitourinary pathologist, and the pathological Gleason grade group, presence of extracapsular extension, seminal vesicle invasion, and surgical margin status were reported. The total number of lymph nodes obtained and number of positive nodes were also collected. After surgery, patients were followed with serial PSA measurements. PSA persistence was defined as a PSA of ≥ 0.1 ng/mL within 4–8 weeks after radical prostatectomy.

The primary study endpoint was the presence of pathological LNI. Secondary endpoints included adverse pathology at

surgery and PSA persistence. Descriptive statistics were used to report baseline clinical characteristics, ^{68}Ga -PSMA PET/CT results, and findings at radical prostatectomy. The median and interquartile range (IQR) were used for continuous variable. Categorical variables were reported as number and percent. The sensitivity, specificity, positive predictive value, and negative predictive value of ^{68}Ga -PSMA PET/CT for the detection of LNI were calculated on a per-patient basis, with pathological LNI as the standard reference. Univariable logistic regression analyses were performed to evaluate the association between baseline clinical and pathological characteristics, including age, clinical T-stage, PSA, biopsy Gleason grade group, percent positive biopsy cores and LNI on ^{68}Ga -PSMA PET/CT, and the presence of one or more adverse outcomes at radical prostatectomy (pathological Gleason grade group ≥ 3 , extracapsular extension, seminal vesicle invasion, LNI, and PSA persistence). P-values for the univariable logistic regression analyses were adjusted using the Bonferroni method due to multiple testing. Receiver operating characteristic (ROC) curve analyses were performed to evaluate the diagnostic performance of ^{68}Ga -PSMA PET/CT, and the Gandaglia et al nomogram in predicting LNI and the areas under the ROC curves were obtained and compared using the DeLong test.¹² All statistical analyses were two-sided, and significance was defined as $p < 0.05$. All analyses were conducted using R Statistical Software (version 3.5.1; R Foundation for Statistical Computing, Vienna, Austria).

Results

The study cohort included a total of 88 men at a median age of 66 years (IQR 61, 69). Clinical stage was T1c in 58/88 patients (66%) and T2a in 30/88 (34%). Median PSA value was 6.30 (IQR 5.18, 8.50). Most patients (78/88, 89%) had Gleason grade group 2 tumors on prostate biopsy. The median estimated risk of LNI at surgery was 2% (IQR 2%, 3%). Patient and biopsy characteristics are reported in Table 1.

Preoperative ^{68}Ga -PSMA PET/CT showed uptake in all of the primary prostate lesions and suspicious uptake in lymph nodes in 4/88 patients (5%). Among the four patients with suspected node involvement, the median number of suspicious nodes was 1.50 (IQR 1.00, 2.00) and median short axis diameter of suspicious nodes was 8.00 mm (IQR 5.50, 10.75) (Table 1). The event rate of a positive finding on ^{68}Ga -PSMA PET/CT in our cohort of favorable intermediate-risk patients was 0.05 (4/88); since the event rate in patients who do not undergo PET-PSMA is zero, on average (number needed to scan = $1/0.05 = 20$), 20 patients would need to be scanned to identify a patient with a positive lymph node on ^{68}Ga -PSMA PET/CT.

Surgical pathological findings are reported in Table 2. The sensitivity, specificity, positive, and negative predictive value for seminal vesicle invasion were 53%, 98%, 70%, and 92%, respectively (Table 3). Two patients had pathological LNI, only

Table 1. Clinical, pathological, and imaging characteristics of the study cohort prior to radical prostatectomy and lymph node dissection (n=88)

Variable	Finding
Age (years)	66.00 (61.00, 69.00)
Clinical stage	
T1c	58 (65.9)
T2a	30 (34.1)
PSA (ng/mL)	6.30 (5.18, 8.50)
Biopsy Gleason grade group	
1	10 (11.4)
2	78 (88.6)
Number of biopsy cores	12.00 (12.00, 14.25)
Number of positive biopsy cores	3.00 (3.00, 5.00)
Percent positive biopsy cores (%)	25 (19, 42)
Estimated risk of lymph node involvement* (%)	2.00 (2.00, 3.00)
Lymph node involvement on PET-PSMA	
No	84 (95.5)
Yes	4 (4.5)
Number of involved nodes on PET-PSMA**	1.50 (1.00, 2.00)
Largest diameter of involved nodes on PET-PSMA (mm)**	8.00 (5.50, 10.75)
Suspected extra-capsular extension on PET-PSMA	
No	88
Yes	0
Suspected seminal vesicle invasion on PET-PSMA	
No	80
Yes	8

Continuous variables are reported as median and interquartile range and categorical variables as number and percent. *Calculated based on the nomogram by Gandaglia et al.¹¹ **Among 4 patients with positive lymph nodes on PET-PSMA. PET: positron emission tomography; PSA: prostate-specific antigen; PSMA: prostate specific membrane antigen.

one of whom showed ⁶⁸Ga-PSMA PET/CT uptake prior to surgery. The sensitivity, specificity, positive predictive value, and negative predictive value of ⁶⁸Ga-PSMA PET/CT for identifying LNI at radical prostatectomy were 50%, 97%, 25%, and 99%, respectively (Table 3), and the area under the ROC curve was 0.73. The area under the ROC curve for the detection of LNI using the predictive nomogram was 0.69 (p=0.87 using the DeLong test) (Figure 1). After surgery, four patients had evidence of PSA persistence. The rate of PSA persistence was higher among patients with LNI on preoperative ⁶⁸Ga-PSMA PET/CT (2/4, 50% vs. 2/84, 2%, p=0.009).

Univariable logistic regression analyses did not show an association between the preoperative predictors age, clinical stage, PSA, Gleason grade group on prostate biopsy, percent positive biopsy cores and LNI on ⁶⁸Ga-PSMA PET/CT, and any adverse outcome at radical prostatectomy after adjusting the p-value due to multiple testing (Table 4).

Table 2. Pathological findings at radical prostatectomy and lymph node dissection (n=88)

Variable	Finding
Gleason grade group at radical prostatectomy	
1	2 (2.3)
2	57 (64.8)
3	29 (33.0)
Extra-capsular extension	
No	44 (50.0)
Yes	44 (50.0)
Seminal vesical invasion	
No	77 (87.5)
Yes	11 (12.5)
Positive surgical margins	
No	79 (89.8)
Yes	9 (10.2)
Pathologic lymph node involvement	
No	86 (97.7)
Yes	2 (2.3)
Total number of lymph nodes obtained at prostatectomy	12.50 (11.00, 16.00)
PSA persistence after surgery	
No	84 (95.5)
Yes	4 (4.5)

Continuous variables are reported as median and interquartile range and categorical variables as number and percent. PSA: prostate-specific antigen.

Discussion

In the current study, we evaluated the role of preoperative ⁶⁸Ga-PSMA PET/CT imaging for patients diagnosed with favorable intermediate-risk prostate cancer who underwent radical prostatectomy with lymph node dissection. The rate of positive LNI on imaging was 5%; thus, 20 patients were needed to undergo a scan to identify a positive finding. Moreover, we found a low positive predictive value of 25% for pathological LNI and a small non-significant increase in the area under the ROC curve compared to preoperative nomogram findings, further questioning the utility of the preoperative scan in this risk group.

Pretreatment staging for patients diagnosed with prostate cancer is evolving with the advent of improved imag-

Table 3. Diagnostic characteristics of PET-PSMA in detecting seminal vesicle invasion and lymph node involvement

	Sensitivity (%)	Specificity (%)	Positive predictive value (%)	Negative predictive value (%)
Seminal vesicle invasion	53	98	70	92
Lymph node involvement	50	97	25	99

PET: positron emission tomography; PSMA: prostate-specific membrane antigen.

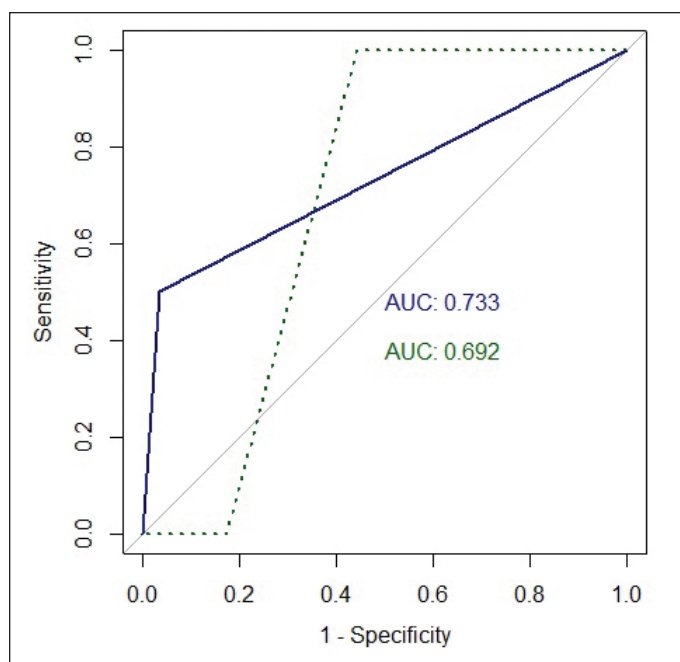


Figure 1. Receiver operating characteristic (ROC) curves evaluating the diagnostic performance of ^{68}Ga -PSMA PET/CT (blue) and the Gandaglia et al nomogram (green) in predicting LNI at radical prostatectomy and pelvic lymph node dissection with the appropriate areas under the curves. AUC: area under the curve; LNI: lymph node involvement.

ing modalities. Findings from the randomized, multicenter, proPSMA trial support replacing conventional imaging using bone scan and abdominopelvic CT with more sensitive imaging modalities for the initial staging of patients with high-risk prostate cancer. In the trial, ^{68}Ga -PSMA PET/CT had higher sensitivity (85% vs. 38%) and specificity (98% vs. 91%) than conventional imaging, translating to a 92% vs. 65% area under the curve for accuracy, thus favoring ^{68}Ga -PSMA PET/CT as the preferred imaging modality. This benefit was con-

sistent for the detection of both pelvic nodal involvement and distant metastases.¹⁰ When evaluated in the high-risk setting, ^{68}Ga -PSMA PET/CT had a good sensitivity and specificity for LNI, possibly impacting clinical decision-making. In a contemporary meta-analysis investigating the role of ^{68}Ga -PSMA PET/CT for primary staging, the sensitivity and specificity of ^{68}Ga -PSMA PET/CT were 77% and 97%, respectively.¹³

The role of ^{68}Ga -PSMA PET/CT in the evaluation of patients with lower-risk disease is less studied, as most publications evaluating the incremental value of ^{68}Ga -PSMA PET/CT included mostly high-risk prostate cancer patients.^{8,13} Even among studies that included small numbers of intermediate-risk patients, they were all diagnosed with unfavorable characteristics¹⁰ or were recognized only as intermediate-risk patients without further data regarding subclassification to favorable or unfavorable risk.¹⁴ None of these published studies reported data or presented the diagnostic characteristics of ^{68}Ga -PSMA PET/CT specifically among men with intermediate-risk disease and especially in a group of patients with favorable intermediate-risk prostate cancer. Due to the extensive use of ^{68}Ga -PSMA PET/CT in our center, we were able to evaluate the performance of ^{68}Ga -PSMA PET/CT when used preoperatively in a consecutive cohort of men with favorable intermediate-risk prostate cancer according to the NCCN criteria. In our cohort, the sensitivity for LNI was 50%, lower than previously published in cohorts of high-risk disease, and a low positive predictive value was observed (25%), possibly due to the low number of patients who are expected to have nodal involvement given the favorable risk of this group of patients. In addition, as published previously, it is difficult to identify extracapsular extension using ^{68}Ga -PSMA PET/CT alone, and none of the patients in our cohort were suspected to have a T3a disease preoperatively.¹⁵

Pelvic lymph node dissection based on predefined anatomical templates remains the gold standard for the detec-

Table 4. Univariable logistic regression analyses evaluating the association between preoperative clinical characteristics and adverse outcomes at radical prostatectomy, including one or more of the following findings: Gleason grade group >2, extracapsular extension, seminal vesicle invasion, lymph node involvement, and/or PSA persistence

Variable	OR	95% CI		p	Adjusted p*
Age (per 1 year)	1.074	1.011	1.149	0.027	0.161
Clinical stage					
T1c	Ref.			0.528	1
T2a	0.751	0.307	1.838		
PSA (per 1 ng/mL)	0.954	0.831	1.09	0.481	1
Biopsy Gleason grade group					
1	Ref.			0.59	1
2	1.437	0.372	5.565		
Percent positive biopsy cores (per 1%)	1.176	0.865	1.615	0.304	1
Lymph node involvement on PET-PSMA					
No	Ref.			0.743	1
Yes	0.714	0.082	6.185		

*p-values were adjusted using the Bonferroni method. CI: confidence interval; OR: odds ratio; PET: positron emission tomography; PSA: prostate-specific antigen; PSMA: prostate-specific membrane antigen; Ref: reference.

tion of nodal metastases. Given the potential morbidity associated with this procedure,¹⁶⁻¹⁸ it should be considered only in men with an increased risk of LNI. American Urological Association guidelines recommend lymph node dissection in every man with unfavorable-intermediate or high-risk prostate cancer.⁴ The European Association of Urology and NCCN guidelines recommend the use of predictive models to help identify patients with high probability of LNI and use various cutoffs for selecting the appropriate candidates for lymph node dissection.^{3,5} In our cohort, we used the nomogram developed by Gandaglia et al to evaluate preoperative risk of LNI. The area under the ROC curves of the nomogram and ⁶⁸Ga-PSMA PET/CT did not differ significantly and no benefit was noted when using PET/CT.

In medicine, the concept of number needed to treat is well-established, unlike the concept of number needed to image, which is less used when describing the benefit obtained from an imaging modality.¹⁹ The concept of number needed to image should be further developed to define how many negative imaging tests can be allowed for one positive finding, both from the perspective of optimal patient care, as well as from the perspective of cost-effective imaging, especially when the positive predictive value is low.²⁰ Physicians aim to avoid advanced imaging in the setting of a low clinical suspicion of finding abnormalities. From a clinical standpoint, according to our findings, ⁶⁸Ga-PSMA PET/CT does not improve the ability to identify patients at a higher risk of LNI, and its implementation in clinical practice would not substantially alter the number of patients destined to undergo lymph node dissection. Our results demonstrate that currently available nomograms to predict the risk of LNI are relatively accurate and still play an important role in guiding treatment decisions, and the value of ⁶⁸Ga-PSMA PET/CT in patients with favorable intermediate-risk prostate cancer is questionable.

Limitations

The study limitations include the small cohort size and the retrospective nature of the study. There was likely a selection bias in patients who had favorable intermediate-risk prostate cancer and underwent ⁶⁸Ga-PSMA PET/CT prior to surgery. This selection bias may explain, in part, the relatively high rate of extracapsular extension observed in our cohort. In addition, the ⁶⁸Ga-PSMA PET/CT scans and biopsy Gleason scores included in the study did not undergo central review; however, they were performed by experienced readers and dedicated genitourinary pathologists. Finally, in the current study we did not have a comparison group of patients who did not undergo imaging or who underwent imaging using conventional modalities; thus, we were unable to assess the incremental value of ⁶⁸Ga-PSMA PET/CT. However, given the diagnostic characteristics of ⁶⁸Ga-PSMA PET/CT in patients with favorable intermediate disease, it is unlikely this benefit will be substantial.

Conclusions

Preoperative imaging of favorable intermediate-risk prostate cancer patients using ⁶⁸Ga-PSMA PET/CT showed a low yield for identifying patients with LNI and adverse pathology at prostatectomy. Our findings do not support the routine use of ⁶⁸Ga-PSMA PET/CT in patients with favorable intermediate-risk prostate cancer. Future prospective studies are needed to validate our results.

Competing interests: The authors do not report any competing personal or financial interests related to this work.

This paper has been peer-reviewed.

References

- Huetting TA, Corneli EB, Somford DM, et al. External validation of models predicting the probability of lymph node involvement in prostate cancer patients. *Eur Urol Oncol* 2018;1:411-7. <https://doi.org/10.1016/j.euo.2018.04.016>
- Partin AW, Kattan MW, Subong ENP, et al. Combination of prostate-specific antigen, clinical stage, and Gleason score to predict pathological stage of localized prostate cancer: A multi-institutional update. *JAMA* 1997;277:1445-51. <https://doi.org/10.1001/jama.277.18.1445>
- Mohler JL, Antonarakis ES, Armstrong AJ, et al. Prostate cancer, version 2.2019, NCCN clinical practice guidelines in oncology. *J Natl Compr Canc Netw* 2019;17:479-505. <https://doi.org/10.6004/jncn.2019.0023>
- Sanda MG, Cadeddu JA, Kirkby E, et al. Clinically localized prostate cancer: AUA/ASTRO/SUO guideline. Part I: Risk stratification, shared decision making, and care options. *J Urol* 2018;199:683-90. <https://doi.org/10.1016/j.juro.2017.11.095>
- Mottet N, Bellmunt J, Bolla M, et al. EAU-ESTRO-SIOG guidelines on prostate cancer. Part 1: Screening, diagnosis, and local treatment with curative intent. *Eur Urol* 2017;71:618-29. <https://doi.org/10.1016/j.eururo.2016.08.003>
- Kindrick AV, Grossfeld GD, Stier DM, et al. Use of imaging tests for staging newly diagnosed prostate cancer: Trends from the CAPSURE database. *J Urol* 1998;160:2102-6. [https://doi.org/10.1016/S0022-5347\(01\)62252-3](https://doi.org/10.1016/S0022-5347(01)62252-3)
- Abraham N, Wan F, Montaghet C, et al. Decrease in racial disparities in the staging evaluation for prostate cancer after publication of staging guidelines. *J Urol* 2007;178:82-7. <https://doi.org/10.1016/j.juro.2007.03.035>
- Satapathy S, Singh H, Kumar R, et al. Diagnostic accuracy of ⁶⁸Ga-PSMA PET/CT for initial detection in patients with suspected prostate cancer: A systematic review and meta-analysis. *Am J Roentgenol* 2021;216:599-607. <https://doi.org/10.2214/AJR.20.23912>
- Herlemann A, Wenter V, Kretschmer A, et al. ⁶⁸Ga-PSMA positron emission tomography/computed tomography provides accurate staging of lymph node regions prior to lymph node dissection in patients with prostate cancer. *Eur Urol* 2016;70:553-7. <https://doi.org/10.1016/j.eururo.2015.12.051>
- Hofman MS, Lawrentschuk N, Francis RJ, et al. Prostate-specific membrane antigen PET-CT in patients with high-risk prostate cancer before curative-intent surgery or radiotherapy (proPSMA): A prospective, randomized, multicenter study. *Lancet* 2020;395:1208-16. [https://doi.org/10.1016/S0140-6736\(20\)30314-7](https://doi.org/10.1016/S0140-6736(20)30314-7)
- Gandaglia G, Ploussard G, Valerio M, et al. A novel nomogram to identify candidates for extended pelvic lymph node dissection among patients with clinically localized prostate cancer diagnosed with magnetic resonance imaging-targeted and systematic biopsies. *Eur Urol* 2019;75:506-14. <https://doi.org/10.1016/j.eururo.2018.10.012>
- DeLong ER, DeLong DM, Clarke-Pearson DL. Comparing the areas under two or more correlated receiver operating characteristic curves: A non-parametric approach. *Biometrics* 1988;44:837-45. <https://doi.org/10.2307/2531595>
- Perera M, Papa N, Roberts M, et al. Gallium-68 prostate-specific membrane antigen positron emission tomography in advanced prostate cancer-updated diagnostic utility, sensitivity, specificity, and distribution of prostate-specific membrane antigen-avid lesions: a systematic review and meta-analysis. *Eur Urol* 2020;77:403-17. <https://doi.org/10.1016/j.eururo.2019.01.049>

14. Roach PJ, Francis R, Emmett L, et al. The impact of ^{68}Ga -PSMA PET/CT on management intent in prostate cancer: Results of an Australian prospective multicenter study. *J Nucl Med* 2018;59:82-8. <https://doi.org/10.2967/jnumed.117.197160>
15. Dekalo S, Kuten J, Majeesh NJ, et al. ^{68}Ga -PSMA PET/CT: Does it predict adverse pathology findings at radical prostatectomy? *Urol Oncol Sem Orig Invest* 2019;37:574.e19-24. <https://doi.org/10.1016/j.urolonc.2019.05.015>
16. Briganti A, Chun FKH, Salonia A, et al. Complications and other surgical outcomes associated with extended pelvic lymphadenectomy in men with localized prostate cancer. *Eur Urol* 2006;50:1006-13. <https://doi.org/10.1016/j.eururo.2006.08.015>
17. Oderda M, Diamand R, Albisinni S, et al. Indications and complications of pelvic lymph node dissection for prostate cancer: are currently available nomograms accurate to predict lymph node invasion? *BJU Int* 2021;127:318-25. <https://doi.org/10.1111/bju.15220>
18. Touijer K, Fuenzalida RP, Rabbani F, et al. Extending the indications and anatomical limits of pelvic lymph node dissection for prostate cancer: Improved staging or increased morbidity? *BJU Int* 2011;108:372-7. <https://doi.org/10.1111/j.1464-410X.2010.09877.x>
19. Nuovo J, Melnikow J, Chang D. Reporting number needed to treat and absolute risk reduction in randomized controlled trials. *JAMA* 2002;287:2813-4. <https://doi.org/10.1001/jama.287.21.2813>
20. Haller S. The concept of number needed to image. *AJNR Am J Neuroradiol* 2017;38:E79-80. <https://doi.org/10.3174/ajnr.A5276>

Correspondence: Dr. Snir Dekalo, Department of Urology, Tel Aviv Sourasky Medical Center, Tel Aviv, Israel; snirdekalo@gmail.com