

# An update on urethral diverticula: Results from a large case series

Athina Pirpiris<sup>1</sup>, Garson Chan<sup>2,3</sup>, Richard C. Chaulk<sup>3</sup>, Henley Tran<sup>1</sup>, Madalena Liu<sup>1,4</sup>

<sup>1</sup>Monash Health, Clayton, Victoria, Australia; <sup>2</sup>Austin Health, Heidelberg, Victoria, Australia; <sup>3</sup>University of Saskatchewan, Saskatoon, SK, Canada; <sup>4</sup>Knox Private Hospital, Wantirna, Victoria, Australia

**Cite as:** Pirpiris A, Chan G, Chaulk RC, et al. An update on urethral diverticula: Results from a large case series. *Can Urol Assoc J* 2022;16(8):E443-7. <http://dx.doi.org/10.5489/cuaj.7650>

Published online March 11, 2022

## Abstract

**Introduction:** We aimed to describe the presentation, investigations, and management of patients with urethral diverticula and to review the importance of magnetic resonance imaging (MRI) in the diagnosis and surgical management of urethral diverticula.

**Methods:** This was a retrospective review of female patients who underwent urethral diverticulectomies. This study was approved by the research ethics review board. Data was collected on patient demographics, presenting symptoms, investigations performed, operative technique, and minimum of two-year followup.

**Results:** A total of 17 patients were included in this study, with a median age of 43 years. Most patients (70%) presented with a palpable vaginal lump; 64% presented with either lower urinary tract symptoms (LUTS) or recurrent urinary tract infections (UTIs). Patients underwent a preoperative MRI, which demonstrated that 59% of diverticula were distal and 53% were locally round. These imaging findings were consistent with the operative findings. MRI also demonstrated communication between the urethral diverticulum and the urethral lumen in 80% of cases, compared to only 47% endoscopically.

**Conclusions:** The most common presentation of a woman with a urethral diverticulum is with either a palpable vaginal lump, LUTS, or recurrent UTIs. A high index of suspicion is required. Pelvic MRI appears to be an ideal imaging modality for the diagnosis of urethral diverticulum. A preoperative MRI is important to exclude alternative pathologies, appropriately counsel the patient, and assist with the surgical planning.

## Introduction

Urethral diverticula are outpouchings of the urethral mucosa into the periurethral tissue.<sup>1</sup> Typically, diverticula occur in the middle to distal aspect of the posterior urethra.<sup>2</sup> They can have a variable appearance in terms of size, shape, and location.<sup>2,3</sup> They are uncommon, with an incidence rate of 0.6–6%, and are generally considered to be acquired secondary to chronic inflammation of a blocked duct.<sup>1,2,4</sup> The periurethral glands are believed to be the common site of origin. They are often benign but can be complicated by

infection, calculi, and very rarely, malignant changes can be seen.<sup>2,5</sup> Congenital origins are considered exceedingly rare and attributed to anomalies of an ectopic ureter insertion or, rarely, Skene's gland cysts.<sup>6-8</sup>

Urethral diverticula are a challenging diagnosis, as the symptoms can be varied and non-specific. The most common presenting symptom is urinary incontinence (37%), followed by pelvic and urethral pain (35%), and then recurrent urinary tract infection (UTI) (33%).<sup>3</sup> The classic “3 Ds” of dysuria, dyspareunia, and terminal dribbling only rarely occur.<sup>9</sup> The clinical examination findings can be subtle. The clinician may be unable to palpate the diverticulum and endoscopically, the ostium may not be visible. Therefore, diagnostic imaging is useful. Multiple imaging modalities have been used previously, including voiding cystourethrograms (VCU), double-balloon tests, and ultrasound. These have largely been superseded by magnetic resonance imaging (MRI), which has become the gold standard for diagnosing a urethral diverticulum. MRI is more expensive but less invasive and more accurate compared to the other tests.<sup>10,11</sup> Additionally, the improved anatomical detail is crucial for surgical planning. Therefore, MRI is the imaging modality of choice when clinical findings suggest the presence of a urethral diverticulum.<sup>12</sup>

Our study aimed to describe the clinical presentations of our patients with urethral diverticula, the benefits and the role of preoperative MRI, as well as our surgical outcomes.

## Methods

A retrospective study of all patients who underwent a urethral diverticulectomy between 2010 and 2018 was undertaken. Patients were screened by medical record chart review based on a combination of diagnosis, treatment, and billing identifiers. The operations were all performed by a single surgeon with subspecialty training in functional and reconstructive urology. The Monash Human Research and Ethics Committee approved this study as a quality assurance study. A comprehensive chart review was performed on all health medical records in all patients that had undergone a urethral diverticulectomy during that period. Clinical data from both electronic and paper-based medical records was collected on demographics, symptoms, investigations performed, the operative technique, and the followup of these patients.

In our center, a 2 Tesla MRI pelvis was performed using a torso phase array coil without endoluminal coils. Axial, coronal, and sagittal fast spin-echo T2-weighted sequences were taken. A T2 postvoid phase was also performed in addition to a T1 fat-suppressed sequence. All the MRIs in our study were reviewed by experienced uro-radiologists.

## Results

A total of 17 female patients were included in this study. The median age of our patients was 43 years old (range 28–71).

Regarding the risk factors for urethral diverticula, 94% of women had previous pregnancies, with 70% of these undergoing vaginal delivery. There were no patients who had previous incontinence or fistulae operations. None of these operations were revisions of previous urethral diverticulectomies.

The mean time from onset of symptoms to their diagnosis was three years. All these patients had been referred by their general practitioner.

### Presenting symptoms

Most of these women (70%) presented with a palpable lump for investigation, while 47% experienced lower urinary tract symptoms (LUTS), including dysuria, and 18% had recurrent UTIs. Only 12% described stress urinary incontinence (SUI). There were no women who complained of dribbling or discharge as their main complaint (Table 1). On clinical examination, all women had a palpable lump, of which 29% complained of pain on palpation.

### Imaging

A pelvic MRI was used to diagnose the urethral diverticulum in 16 patients (Table 2). Only one patient did not have any preoperative imaging, as the examination under anesthesia (EUA) demonstrated a clearly palpable diverticulum and an endoscopically visible ostium. The diverticulum itself could be endoscopically inspected. Only one patient had a VCU prior to the review by a urologist. The VCU did not provide sufficient detail and, therefore, an MRI was arranged. There were no ultrasounds or double-balloon tests performed in our cohort.

MRI was able to detect the location of the diverticulum's communication with the urethra in 80% of the cases, compared to only 47% that were able to be visualized endoscopically. This is in the context of over 90% of the diverticula in this study having a communication with the urethra.

There is currently no consensus regarding how urethral diverticula should be classified. Table 3 outlines the characteristics of the urethral diverticula in this study. In our series, 94% of the urethral diverticula were a single diverticulum that communicated with the urethra. Almost

**Table 1. Patient demographics**

Select demographics	n=17 (%)
Average age	43 years (range 28–71)
Risk factors	
Previous pregnancy	16 (94%)
Vaginal deliveries	12 (70%)
Previous incontinence/fistula surgery	0 (0%)
Presenting symptoms	
Palpable lump	12 (70%)
LUTS (including dysuria)	8 (48%)
Recurrent UTI	3 (18%)
SUI	2 (12%)
Dyspareunia	2 (12%)
Dribbling/discharge	0 (0%)
Mean time from symptom onset to diagnosis	3 years
Clinical examination findings	
Palpable lump	17 (100%)
Pain with palpation	5 (29%)

LUTS: lower urinary tract symptoms; SUI: stress urinary incontinence; UTI: urinary tract infection.

half (53%) were locally round and well-defined. The majority (60%) were located distally.

### Operation

All women had a transvaginal approach to the excision of their urethral diverticulum, with careful identification and dissection of the peri-urethral fascia (Figures 1, 2). The urethral defect was repaired with a three-layer closure, with non-overlapping suture lines (Figure 3). Eight women (47%) also had a Martius flap interposed to minimize the risk of a urethrocutaneous fistula for cases where the diverticula were large with a large urethral defect. The decision to proceed with a Martius flap was made intraoperatively and based on the surgeon's discretion and experience. The mean length of stay in hospital was two days. The indwelling catheter remained in situ for one week. No urethrograms were routinely performed prior to trial of void.

### Followup

The mean postoperative followup was 12 months. This ranged from six months (when eight patients were discharged) up

**Table 2. The diagnostic imaging tests performed**

Imaging modality	Number
MRI	16 (94%)
VCU	1 (6%)
Double balloon test	0
Vaginal ultrasound	0
No imaging	1 (6%)

MRI: magnetic resonance imaging; VCU: voiding cystourethrogram.

**Table 3. Urethral diverticula characteristics**

	Diverticulum characteristics	Number (%)
Location along the urethra	Proximal	3 (18%)
	Mid	4 (24%)
	Distal	10 (60%)
Number	1	16 (94%)
	2 or more	1 (6%)
Size	Mean (mm)	18x16x17
Configuration	Saddle	3 (18%)
	Partially circumferential	5 (30%)
	Locally round/oval	9 (54%)
Communication with urethra	Yes	16 (94%)
	No	1 (6%)*

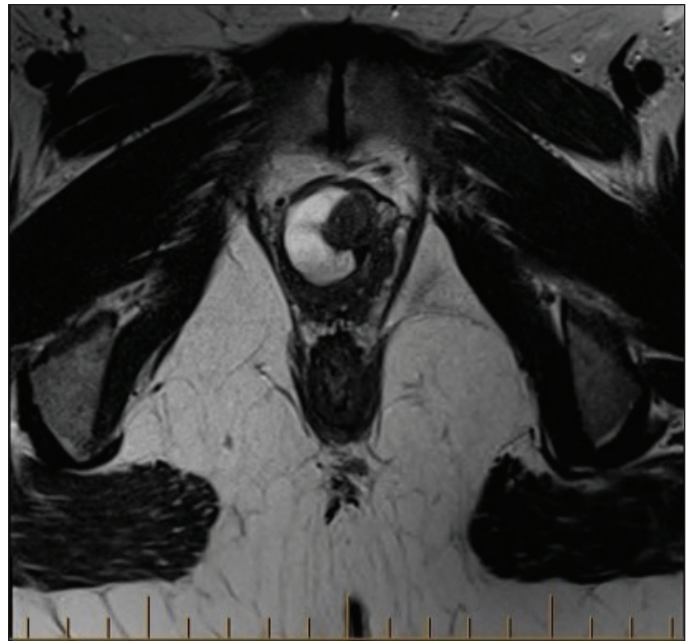
\*Magnetic resonance imaging demonstrated a likely communication with urethra, but during operation it was difficult to find the opening. This could represent a possible closure/narrowing during delay from imaging to surgery.

to 24 months. Three patients (18%) did not return for their scheduled six-month followup.

There were no postoperative complications or recurrences within the followup period in this cohort of women. There were no patients that developed de novo SUI or fistula. Additionally, the two patients that had dyspareunia preoperatively did not have any more pain after the diverticulectomy.

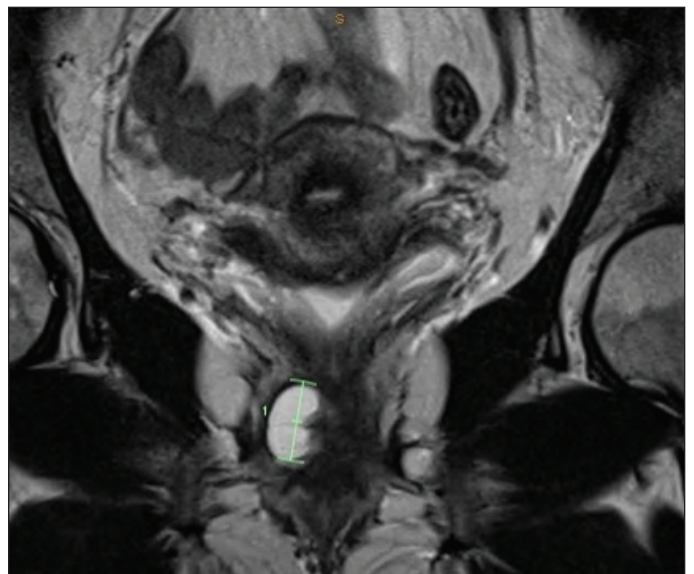
## Discussion

Urethral diverticulum remains an uncommon urological presentation. It can be a challenging diagnosis to make based on symptoms, and the examination findings can often be subtle. Standard renal tract ultrasound for the investigation of recurrent UTIs will not detect a urethral diverticulum. As such, a high index of suspicion is required. Our study has demonstrated that women may have up to a three-year delay from the onset of their symptoms to the time of a

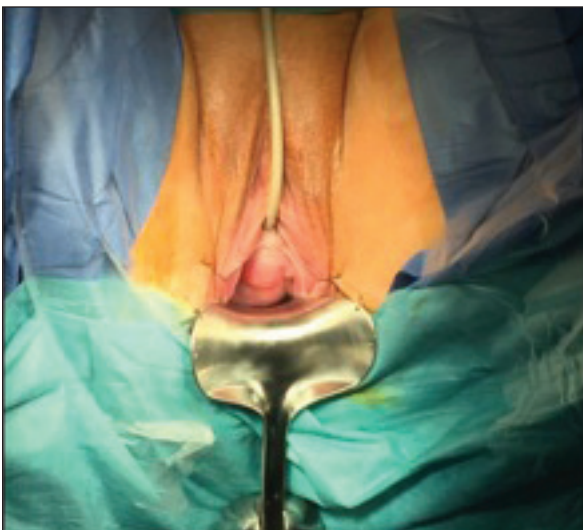


**Figure 2.** T2 postvoid axial magnetic resonance imaging of saddle urethral diverticulum.

diagnosis being made. This delay can significantly impact a woman's quality of life, with prolonged discomfort and pain from the presence of the anterior vaginal wall lump. Multiple studies, including ours, did not find that the "3 Ds" were as classic as previously described.<sup>9</sup> There were no patients who complained of dribbling or discharge as their main complaint. More commonly, women presented with LUTS and recurrent UTIs. SUI has also been reported as a significant presenting symptom in several other studies. The prevalence of SUI on presentation in our study was low, at only 12% (two patients).



**Figure 3.** T2 postvoid coronal magnetic resonance imaging of saddle urethral diverticulum.



**Figure 1.** Urethral diverticulum.



Reasons to account for this difference could include that our median age was lower or that women reported dribbling as incontinence in other studies.<sup>13</sup>

Urethral diverticula are infrequent entities and as such there is no consensus for adhering to a specific classification system. One useful system that may allow for the improved standardization clinically and for research purposes is the L/N/S/C3 (location, number, size, configuration, communication, and continence configuration) classification system.<sup>14</sup> The L/N/C3 system describes the diverticulum's characteristics that are important in the surgical planning. The system aims to describe the location along the urethra, the number of diverticula, size, configuration, whether it communicates with the urethra, and the continence configuration. This classification system has not been widely adopted, owing to its complexity. Most clinicians instead classify a urethral diverticulum into either simple or complex or according to the axial MRI configuration as simple, horseshoe, or circumferential.<sup>15-17</sup> A complex urethral diverticulum is defined as proximal, greater than 3 cm in the greatest dimension, horseshoe or circumferential on transverse MRI, and can be associated with previous pelvic or vaginal surgery.<sup>18,19</sup>

The gold standard imaging modality for diagnosing a urethral diverticulum has changed over the years, as technology has improved. Previously used imaging modalities for investigating a urethral diverticulum (such as double-balloon test and VCU) are almost obsolete and have been superseded by MRI. Foster et al described how 14% of their patients had multiple imaging-based investigations that failed to diagnose urethral diverticula until the patient eventually had an MRI performed.<sup>20</sup> A VCU was traditionally used as the initial diagnostic study for urethral diverticulum and had an overall accuracy of up to 85% among an experienced group of radiologists.<sup>21</sup> This investigation, however, was time-consuming, used ionizing radiation, required catheterization, and the woman had to void in the standing position. It was often challenging to also identify the location of the diverticular orifice on the VCU.<sup>22</sup>

The double-balloon test was first performed in 1959.<sup>23</sup> It required a Trattner catheter with two balloons to be inserted: one to occlude the bladder neck and the other to prevent the leaking of contrast from the urethral meatus. It is technically challenging to create the ideal closed urethral system. It also requires an experienced radiologist, specialized equipment, and ionizing radiation. Patients reported significant discomfort from this procedure.<sup>23</sup> This test is therefore rarely, if ever, used.

Ultrasound is the other imaging modality that has been previously used, with a diagnostic rate of 66%.<sup>24,25</sup> Ultrasound can be performed either transabdominally, transvaginally, or translabially for the investigation of a urethral diverticulum. It is widely available, affordable, and emits no radiation. It can also provide some anatomical information, including

whether the diverticulum has any solid or cystic components and its relationship with the urethra, as well as the sphincter complex; however, its value, as with all ultrasound imaging, is operator-dependent.<sup>5,26</sup>

MRI has now become the gold standard imaging modality for the preoperative anatomical definition of a urethral diverticulum. The sensitivity and specificity of MRI are both approaching 100% and inter-observer agreement is reported as 93% in diagnosing urethral diverticulum.<sup>14,20,27</sup> Various techniques, including endorectal and endovaginal coils, have been used to try to further improve the sensitivity and specificity of MRI.<sup>20</sup> The majority of centers, including ours, do not use endoluminal coils, as they are invasive and expensive. They also do not significantly improve the detection rate of urethral diverticula. The most important phase remains the postvoid T2 phase that can be used to capture urine within the diverticulum to facilitate the anatomical outlining of the diverticulum. We believe, having an experienced radiologist with an interest in pelvic pathology MRI scans is vital.

MRI is also able to provide information that is important for surgical planning. It can give accurate information regarding the size, configuration, and location of the ostium. Han et al looked at a series of 17 patients following urethral diverticulectomies. They reported that 33% of the U-shaped and 60% of the circumferential diverticula recurred.<sup>28</sup> The authors concluded that this was due to the incomplete excision of the diverticula. The ostium location is important to ensure complete excision and proper reconstruction, as well as determining the risk of postoperative de novo SUI. Despite urologists relying predominantly on cystoscopic examination of the urethra to determine the location of the ostium, MRI has been shown to be far more reliable.<sup>27</sup>

In our study, 85% of the ostia were correctly identified on MRI, compared to only 47% endoscopically. Cystoscopy still has a role in cases of suspected urethral diverticulum. It facilitates not only the ability to identify and locate an ostium but also to rule out an ectopic ureter. Further, it optimizes stress testing for SUI and can possibly rule out other causes of recurrent UTI, such as inflammatory processes or foreign bodies; however, MRI is superior for identifying the location of the ostium and in our patients, the MRI and surgical congruence was quite high, which aided surgical planning and preoperative counselling.

Given the above-described utility of MRI, the imaging modality should be considered as a part of the workup for patients with recurrent UTI where other causes have been eliminated. Our case series showed that 100% of patients had a palpable lump on clinical examination. Therefore, with this finding on clinical examination and following endoscopic evaluation for the patient presenting with recurrent UTI, MRI could be considered for the confirmatory diagnosis of urethral diverticulum and preoperative planning.

The additional benefit of MRI has been its reliability in being able to diagnose other causes of vaginal lumps, including Skene's gland abscesses, peri-urethral cysts, and most importantly, carcinomas.<sup>28</sup> There have only been few studies in the literature questioning the reliability of MRI. Chung et al demonstrated that 24% of their patients were misdiagnosed based on the preoperative MRI.<sup>27</sup> Their patients were diagnosed on MRI with a urethral diverticulum but intraoperatively were found to have either a sterile abscess, a Bartholin's cyst, or collagen from a previous peri-urethral injection site. Concerningly, two cancers (one squamous cell carcinoma and one adenocarcinoma) were also missed on the MRIs.<sup>27</sup> This error rate is surprising and not replicated by many other studies. This could be due to either their imaging equipment or perhaps the experience of the radiologist.

Limitations of this study include the retrospective review of a single surgeon. Additionally, three patients were lost to followup, a significant number given the already small sample size. Future studies to contribute to this literature can include larger sample sizes, additional surgeons, and more robust followup protocols.

## Conclusions

Our study showed that an MRI of the pelvis is an ideal imaging modality for diagnosing a urethral diverticulum and determining its important characteristics, including size, location, configuration, number, and relationship to the sphincter complex. This information is crucial to planning the surgical approach to minimize intraoperative and postoperative complications. The information obtained from the MRI can also facilitate appropriate preoperative counselling of the patient regarding the risk of fistula and de novo SUI. This study also confirmed that the most common presentation of a urethral diverticulum is not the classical "3Ds," but rather a vaginal lump and recurrent UTIs. Therefore, in a patient with recurrent UTIs, where other causes have been eliminated with cystoscopy and vaginal exam reveals a palpable lump, MRI should be considered.

**Competing interests:** The authors do not report any competing personal or financial interests related to this work.

This paper has been peer-reviewed.

## References

- Lee JWS, Fynes MM. Female urethral diverticula. *Best Pract Res Clin Obstet Gynaecol* 2005;19:875-93. <https://doi.org/10.1016/j.bpobgyn.2005.08.008>
- Foley CL, Greenwell TJ, Gardiner RA. Urethral diverticula in females. *BJU Int* 2011;108:20-3. <https://doi.org/10.1111/j.1464-410X.2011.10714.x>
- Thomas AA, Rackley RR, Lee U, et al. Urethral diverticula in 90 female patients: A study with emphasis on neoplastic alterations. *J Urol* 2008;180:2463-7. <https://doi.org/10.1016/j.juro.2008.08.040>
- Martensson O, Duchek M. Translabial ultrasonography with pulsed color Doppler in the diagnosis of female urethral diverticula. *Scandinav J Urol Nephrol* 1994;28:101-4. <https://doi.org/10.3109/00365599409180480>
- Laudano MA, Jamzadeh AE, Dunphy C, et al. Pathologic outcomes following urethral diverticulectomy in women. *Adv Urol* 2014;2014:861940. <https://doi.org/10.1155/2014/861940>
- Kochakorn W, Ratana-Olam K, Viseshsindh V, et al. Urethral diverticulum in females: 25 years' experience at Ramathibodi Hospital. *J Med Assoc Thai* 2000;83:1437-41.
- Lee NH, Kim SY. Skene's duct cysts in female newborns. *J Paediatr Surg* 1992;27:15-7. [https://doi.org/10.1016/0022-3468\(92\)90094-N](https://doi.org/10.1016/0022-3468(92)90094-N)
- Kimbrough HM Jr, Vaughan ED Jr. Skene's duct cyst in a newborn: A case report and review of literature. *J Urol* 1977;117:387-8. [https://doi.org/10.1016/S0022-5347\(17\)58470-0](https://doi.org/10.1016/S0022-5347(17)58470-0)
- Baradaran N, Chiles LR, Freilich DA, et al. Female urethral diverticula in the contemporary era: Is the classic triad of the "3Ds" still relevant? *Urology* 2016;94:53-6. <https://doi.org/10.1016/j.urology.2016.04.005>
- Rovner ES. Urethral diverticula: a review and an update. *NeuroUrol and Urodyn* 2007;26:972-7. <https://doi.org/10.1002/nau.20434>
- Chou CP, Levenson RB, Elsayes KM, et al. Imaging of female urethral diverticulum: An update. *Radiographics* 2008;28:1917-30. <https://doi.org/10.1148/rg.287075076>
- Romanzi LJ, Groutz A, Blaivas JG. Urethral diverticulum in women: Diverse presentations resulting in diagnostic delay and mismanagement. *J Urol* 2000;164:428-33. [https://doi.org/10.1016/S0022-5347\(05\)67377-6](https://doi.org/10.1016/S0022-5347(05)67377-6)
- Nitti V. The prevalence of urinary incontinence. *Rev Urol* 2001;3:S2-6. <https://www.ncbi.nlm.nih.gov/pmc/articles/PMC16985992/>
- Leach GE, Sirls LT, Ganabathi K, et al. L N S C3: A proposed classification system for female urethral diverticula. *NeuroUrol Urodyn* 1993;12:523-31. <https://doi.org/10.1002/nau.1930120602>
- Kim B, Hricak H, Tanagho EA. Diagnosis of urethral diverticula in women: Value of MR imaging. *AJR Am J Roentgenol* 1993;161:809-15. <https://doi.org/10.2214/ajr.161.4.8372765>
- Rovner ES, Wein AJ. Diagnosis and reconstruction of the dorsal or circumferential urethral diverticulum. *J Urol* 2003;170:82-6. <https://doi.org/10.1097/01.ju.0000067291.70172.b5>
- Ingber MS, Firooz F, Vasavada SP, et al. Surgically corrected urethral diverticula: Long-term voiding dysfunction and reoperation rates. *Urology* 2011;77:65-9. <https://doi.org/10.1016/j.urology.2010.06.004>
- Shim JS, Oh MM, Kang JI, et al. Calculus in a female urethral diverticulum. *Int NeuroUrol J* 2011;15:55-7. <https://doi.org/10.5213/inj.2011.15.1.55>
- Diabate I, Sow I. Female urethral diverticulum containing multiple calculi. *Prog Urol* 2011;21:229-32. <https://doi.org/10.1016/j.purol.2010.04.002>
- Foster RT, Amundsen CL, Webster GD. The utility of magnetic resonance imaging for diagnosis and surgical planning before transvaginal periurethral diverticulectomy in women. *Int Urogynecol J Pelvic Floor Dysfunct* 2007;18:315-9. <https://doi.org/10.1007/s00192-006-0145-3>
- Blander DS, Rovner ES, Schnall MD, et al. Endoluminal magnetic resonance imaging in the evaluation of urethral diverticula in women. *Urology* 2001;57:660-5. [https://doi.org/10.1016/S0090-4295\(00\)01082-7](https://doi.org/10.1016/S0090-4295(00)01082-7)
- Golomb J, Leibovitch I, Mor Y, et al. Comparison of voiding cystourethrography and double balloon urethrography in the diagnosis of complex female urethral diverticula. *Eur Radiol* 2003;13:536-42. <https://doi.org/10.1007/s00330-002-1539-3>
- Jacoby K, Rowbotham RK. Double balloon positive pressure urethrography is a more sensitive test than voiding cystourethrography for diagnosing urethral diverticulum in women. *J Urol* 1999;162:2066-9. [https://doi.org/10.1016/S0022-5347\(05\)68102-5](https://doi.org/10.1016/S0022-5347(05)68102-5)
- Tancer MI, Ravski NA. Suburethral diverticulae. *Clin Obstet Gynaecol* 1982;25:831-7. <https://doi.org/10.1097/00003081-198212000-00018>
- Romanzi LJ, Groutz A, Blaivas JG. Urethral diverticula in women: Diverse presentations resulting in diagnostic delay and management. *J Urol* 2000;164:428-33. [https://doi.org/10.1016/S0022-5347\(05\)67377-6](https://doi.org/10.1016/S0022-5347(05)67377-6)
- Keefe B, Warshauer DM, Tucker MS, et al. Diverticula of the female urethra: Diagnosis by endovaginal and transperineal sonography. *AJR Am J Roentgenol* 1991;156:1195-7. <https://doi.org/10.2214/ajr.156.6.1903021>
- Chung DE, Purohit RS, Gishman J, et al. Urethral diverticula in women: Discrepancies between magnetic resonance imaging and surgical findings. *J Urol* 2010;183:2265-9. <https://doi.org/10.1016/j.juro.2010.02.016>
- Han DH, Jeong YS, Choo MS, et al. Outcomes of surgery of female urethral diverticula classified using magnetic resonance imaging. *Eur Urol* 2007;51:1664-70. <https://doi.org/10.1016/j.euro.2007.01.103>

**Correspondence:** Dr. Garson Chan, University of Saskatchewan, Saskatoon, SK, Canada; [garson.chan@saskhealthauthority.ca](mailto:garson.chan@saskhealthauthority.ca)