

# Images – Appendico-vesical fistula

Edem A. Afenu<sup>1</sup>, Shaun Trecarten<sup>2</sup>, Sarah Neu<sup>2</sup>, Jennifer Locke<sup>2</sup>, Sender Herschorn<sup>2</sup>

<sup>1</sup>Faculty of Medicine, University of Toronto, Toronto, ON, Canada; <sup>2</sup>Division of Urology, Department of Surgery, University of Toronto, Toronto, ON, Canada

**Cite as:** Afenu EA, Trecarten S, Neu S, et al. Images – Appendico-vesical fistula. *Can Urol Assoc J* 2022;16(7):E411-4. <http://dx.doi.org/10.5489/cuaj.7619>

Published online February 28, 2022

## Introduction

Appendico-vesical fistula (AVF) is an uncommon type of enterovesical fistula that can present with symptoms of recurrent or persistent urinary tract infection (UTI) and, in some instances, with gastrointestinal symptoms. AVFs occur more commonly in males and are mainly attributed to unrecognized or conservatively managed appendicitis.<sup>1</sup>

Herein, we describe a case of a 21-year-old male who presented with fevers, urgency, and hematuria, and on extensive workup was found to have an AVF requiring surgical repair. Drawing from our case and the literature, we conclude that AVF occurs rarely and requires a high index of suspicion among physicians. Past medical history of previous acute appendicitis and UTIs with or without gastrointestinal symptoms should raise suspicion for AVF.

## Case report

A 21-year-old male presented to a community hospital with fevers, urinary urgency, and gross hematuria. Initial urinalysis was positive for nitrites, and serum creatinine was 78. A non-contrast computed tomography (CT) scan of his abdomen/pelvis demonstrated a complex focus of gas extraluminal to the posterior wall of the bladder. There was note of an incidental left-sided duplex collecting system, no hydronephrosis, and possible bladder calcification (Figure 1). Focused ultrasound demonstrated significant bladder wall thickening and echoes located at the dome of the bladder, compatible with calcifications. Repeat abdomen/pelvis CT scan with contrast indicated diffuse bladder wall thickening and an exophytic fluid collection with a calcification that did not fill on delayed imaging (Figure 2). He was referred to urology and discharged home with antibiotics for a presumed UTI.

His symptoms did not improve with antibiotics. Cystoscopy demonstrated inflammatory tissue at the trigone to the right of

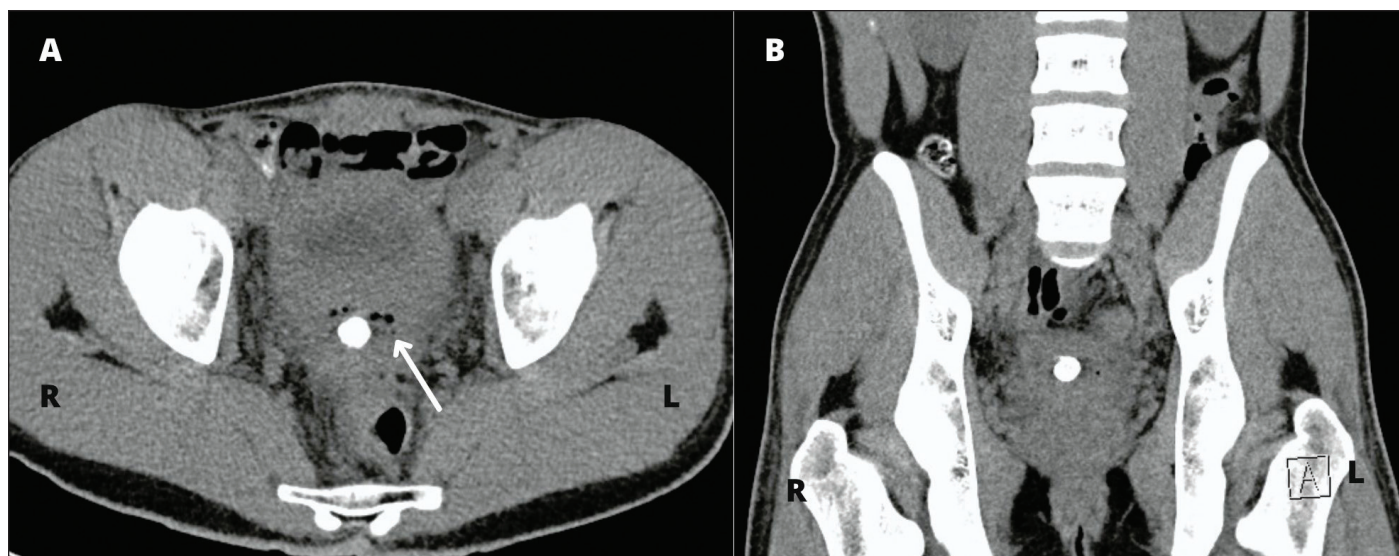
the midline, with no evidence of stones, tumors, or diverticula. Magnetic resonance imaging (MRI), which was ordered for further assessment, demonstrated posterior bladder wall thickening, with an associated cavity containing a stone (Figure 3). Biopsy confirmed no malignancy of the inflammatory tissue at the trigone. Static cystogram at the time was normal.

Due to his ongoing urinary symptoms, he was referred to our center, where he had a voiding cystourethrogram (VCUG) and cystoscopy. VCUG demonstrated a smooth-walled bladder with contrast extending into a possible diverticulum posteriorly (Figure 4A). During voiding of contrast, an extension from the diverticulum was observed (Figure 4B) and when the bladder was empty, the appendix was observed to be filled with contrast (Figure 4C). These findings, which are consistent with an AVF, were misinterpreted as an extension of contrast into the vas deferens or seminal vesicle. Cystoscopy was subsequently performed under general anesthetic due to patient discomfort. This demonstrated inflammation at the trigone in addition to a diverticular neck/fistulous opening just above the right ureteric orifice.

Due to ongoing symptoms and unclear etiology after repeated investigations, he was consented for an open transvesical stone removal and resection of a possible fistulous tract.

Intraoperatively, he had a cystoscopy that confirmed the previous findings. 5 Fr ureteric catheters were placed in each ureteric orifice endoscopically. A midline cystotomy was performed, and the suspected diverticular opening was explored, revealing a 2–3 cm stone (Figure 5). Although the dissection of the pocket was limited, a fistulous tract was suspected. Laparotomy revealed that the appendix was in close contact with the bladder at the site of the fistula. It was therefore mobilized, separated from the posterior bladder wall, and excised. This confirmed the presence of an AVF. Fecal material was removed. The eroded portion of the bladder was irrigated with saline and the posterior bladder wall was approximated with two layers of monofilament absorbable sutures and an omental patch applied. The cystotomy was closed and Foley catheter and JP drain were placed.

The patient was discharged home with a urethral catheter on postoperative day 2. Unfortunately, his catheter became blocked and he presented to hospital with fevers and abdominal pain. CT scan indicated a midline wound urine leakage and infection (Figure 6), which improved after upsizing his



**Figure 1.** (A) Transverse section of non-contrast computed tomography, hence bladder poorly observed. Presence of thick bladder wall with approximately 1 cm calcified ring structure surrounded by free bubbles of gas. (B) Presence of incidental left sided duplex collecting system and bladder wall thickening on coronal image.

Foley catheter, placing it on wall suction intermittently, and antibiotic treatment.

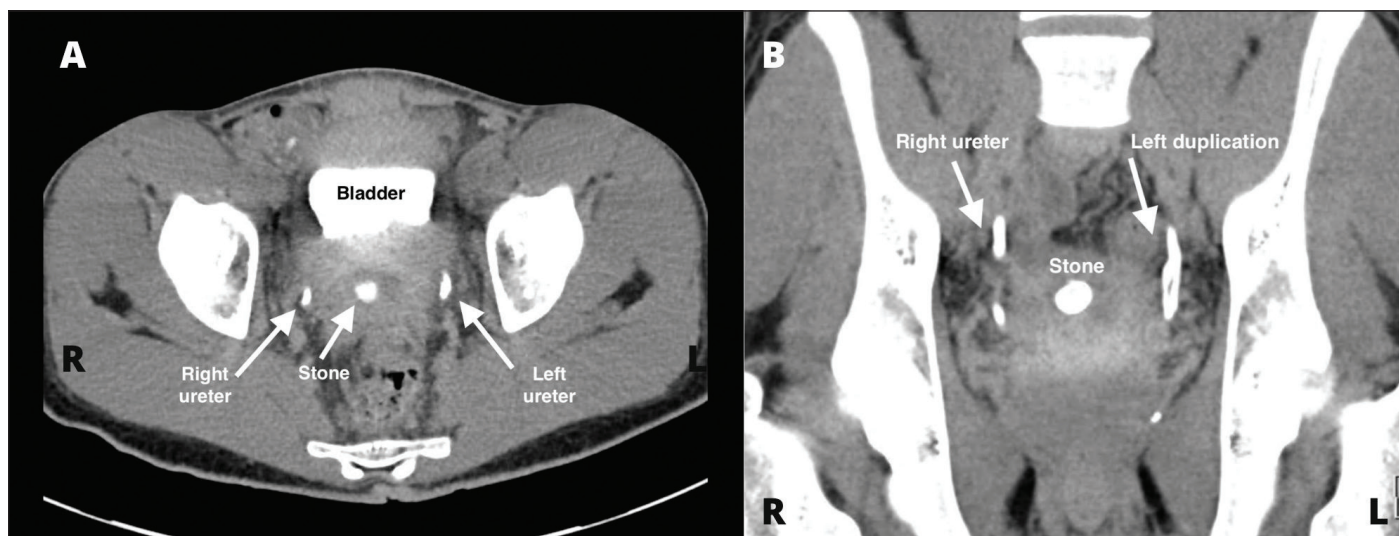
His wound healed well and CT cystogram a month after his incident showed no evidence of urine leak or fistula, hence his catheter was removed (Figure 7). Upon followup three weeks later, he denied any urinary tract symptoms and returned to work.

## Discussion

AVFs constitute less than 5% of all discovered enterovesical fistulas and are frequently attributed to rare complications of appendicitis.<sup>2</sup> However, appendiceal adenocarcinoma, car-

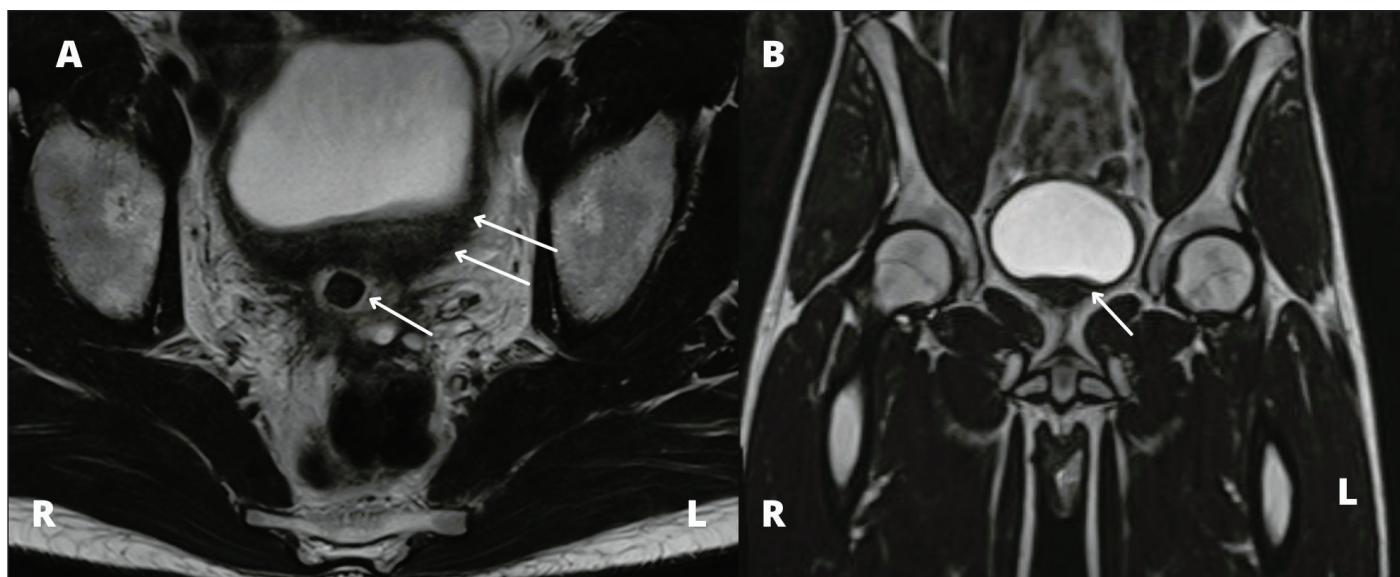
cinoid, neuroma, papillovillous adenoma, polypoid urinary bladder tumor, actinomycosis, cystic fibrosis, Crohn's disease, and Hirschsprung's disease have also been identified as causes.<sup>3</sup> Procedures such as transurethral resection of the prostate (TURP),<sup>4</sup> extravasation of chemotherapy into the bladder tumor, instillation of mitomycin C,<sup>5</sup> and radiation treatment have also resulted in the formation of AVFs on rare occasions.<sup>6</sup> AVFs are less likely to occur in females, as the uterus is situated between the appendix and bladder, hence serving as a barrier.<sup>7</sup>

Patients may present with UTI symptoms, such as frequency, urgency, and dysuria, as well as gastrointestinal symptoms, such as lower abdominal pain and mild abdominal distention.<sup>6,7</sup> Although pneumaturia, fecaluria, and foul-



**Figure 2.** (A) Transverse section of computed tomography with contrast indicating diffuse bladder wall thickening and presence of an exophytic fluid collection containing a calcification, which did not fill on delayed imaging. (B) Coronal section indicating both right and left ureters and confirming left sided duplex collecting system, which is difficult to appreciate without contrast and presence of stone.





**Figure 3.** (A) Transverse magnetic resonance imaging (MRI) demonstrating posterior bladder wall thickening, with an associated cavity containing a stone as indicated by arrows. (B) MRI indicative of bladder wall thickening.

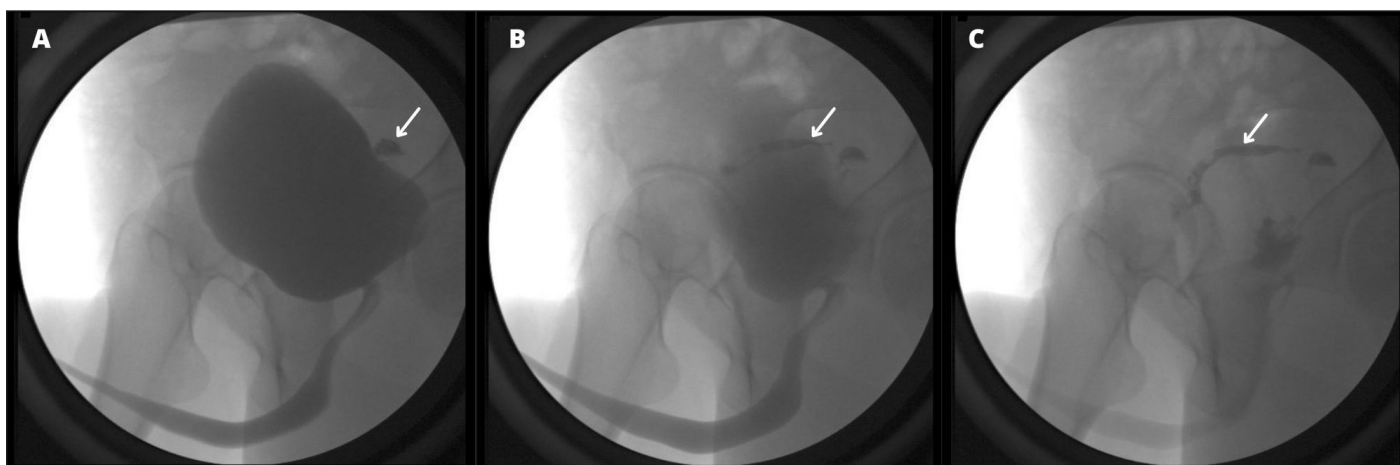
smelling urine are not consistent features of AVFs, they are pathognomonic for enterovesical fistulas in general, and thus require prompt investigation.<sup>6-9</sup> Our case emphasizes awareness of this condition, as our patient presented with non-specific urgency, hematuria, fever, and had no previous documented history of appendicitis. The diagnosis was made only after surgical exploration.

Most authors propose combining multiple imaging modalities when diagnosing AVFs (CT scan, cystography, cystoscopy, colonoscopy, and barium enema).<sup>10</sup> However, CT remains the most sensitive and non-invasive examination for AVF, with a diagnostic accuracy of 60–100%, followed by cystoscopy with a 40% diagnostic accuracy.<sup>9,10</sup> Hence, a CT cystogram or basic cystogram followed by a post-evacuation non-contrast CT

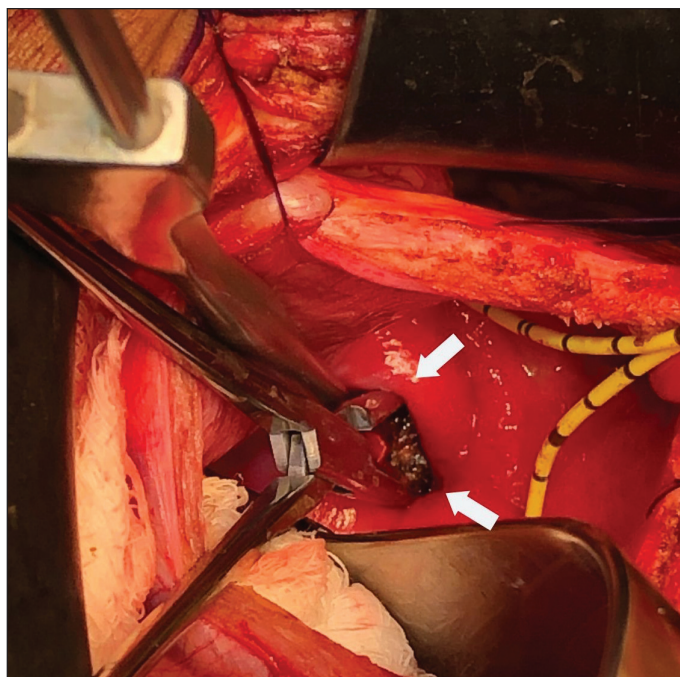
to obtain a 3D image showing leakage of contrast may have identified the fistula sooner. In retrospect, our patient's voiding cystogram identified the fistula, which was misinterpreted, again underscoring the need for awareness of the entity.

Treatment of AVFs involves appendectomy, fistula resection, and primary reconstruction, followed by urethral catheter drainage and antibiotic treatment. Treatment is curative and patients experience complete resolution of symptoms after surgery.<sup>8</sup>

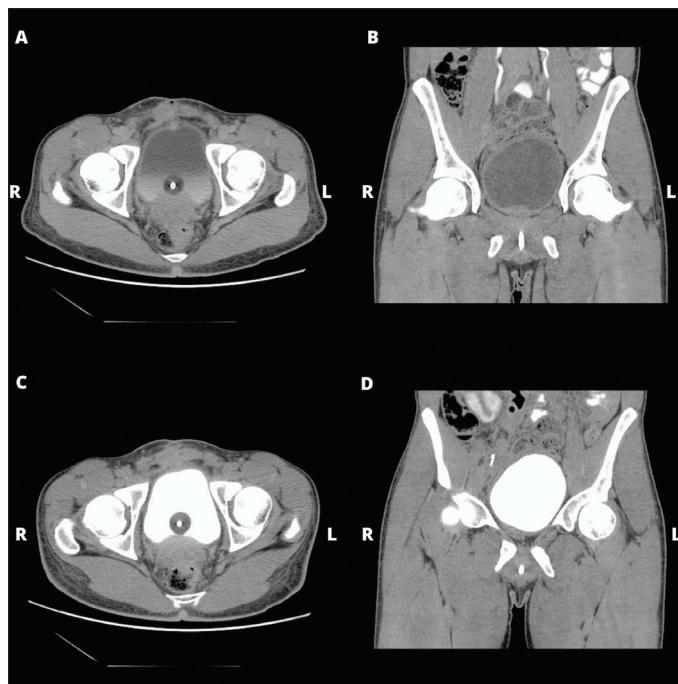
**Competing interests:** Dr. Herschorn has been an advisory board member for Abbvie, Astellas, Boston Scientific, and Pfizer; has received research grants from Astellas and Urovent; and has participated in clinical trials supported by Allergan, Astellas, and Urovent. The remaining authors do not report any competing personal or financial interests related to this work.



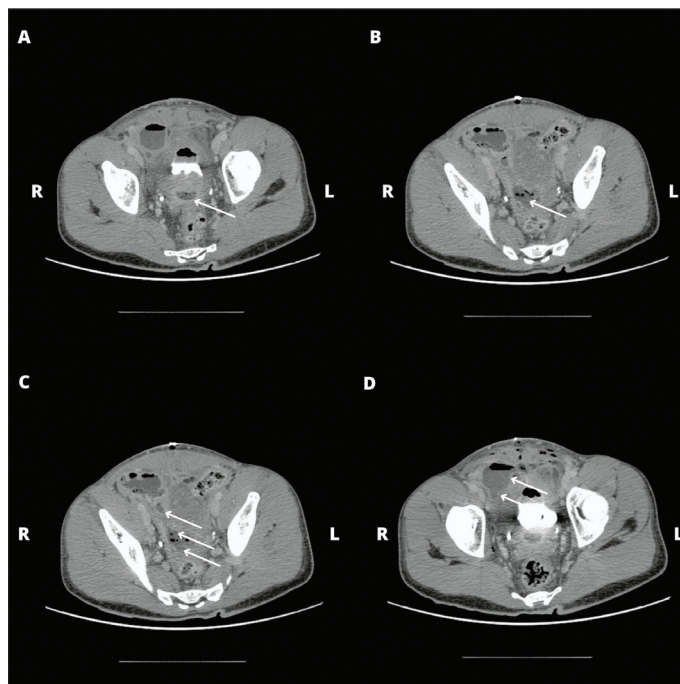
**Figure 4.** (A) Voiding cystourethrogram (VCUG) demonstrating presence of diverticulum-like structure posteriorly upon filling bladder with contrast. (B) Selected image indicating an extension from the diverticulum that was observed during voiding. (C) Voiding cystourethrogram image during emptying of the bladder indicating filling of the appendix with contrast.



**Figure 5.** Intraoperative intravesical image indicating presence of the stone in the fistulized tract connecting the appendix and bladder.



**Figure 7.** Computed tomography scan with oral and intravenous contrast. Images (A) to (D) indicate resolution of fluid filled due to urine leak from bladder into pelvis when compared to Figure 6.



**Figure 6.** Postoperative urine leak probably secondary to a blocked catheter resulting in disruption of the cystostomy incision illustrated on computed tomography. (A) Complex collection within the deep pelvis, extending from the posterior bladder wall and moving along the right lateral and pelvic sidewall, as illustrated by arrows on images (B) and (C) and then into a focal fluid and gas collection at the anterior right lower quadrant, as indicated by the arrow on image (D).

This paper has been peer-reviewed.

## References

1. Alis D, Samanci C, Namda Y, et al. A very rare complication of acute appendicitis: Appendicovesical fistula. *Case Rep Urol* 2016;2016:4517029. <https://doi.org/10.1155/2016/4517029>
2. Athanassopoulos A, Speakman MJ. Appendicovesical fistula. *Int Urol Nephrol* 1995;27:705-8. <https://doi.org/10.1007/BF02552135>
3. Golfam F, Foroootan SK, Golfam P, et al. Appendicovesical fistula: A rare complication of appendicitis. *Acta Medica Iranica* 2008;46.
4. Doherty AP, Whitfield HN. A case of appendico-vesical fistula. *J R Soc Med* 1992;85:757. <https://www.ncbi.nlm.nih.gov/pmc/articles/PMC1494167/>
5. Feng TS, Rusnack S, Kaminski J, et al. Appendicovesical fistula following transurethral resection of bladder tumor with mitomycin C. *Urology* 2016;89:e1-2. <https://doi.org/10.1016/j.urology.2015.12.011>
6. Lai CW, Chen JH, Wu MH, et al. Complicated appendicitis with unusual complication: Appendicovesical fistula. *Am J Med Sci* 2015;349:376-7. <https://doi.org/10.1097/MAJ.0000000000000404>
7. Jeppesen LJ. Appendicovesical fistula: Case report. *Scand J Urol Nephrol* 1993;27:133-4. <https://doi.org/10.3109/00365599309180432>
8. Sharifiaghdas F, Ghoad M, & Mirzaei M. Appendico-vesical fistula in a woman. *Urol J* 2014;11:1703-5. <http://journals.sbmu.ac.ir/urology/index.php/uj/article/view/2033>
9. Kawamura YJ, Sugamata Y, Yoshino K, et al. Appendico-ileo-vesical fistula. *J Gastroenterol* 1998;33:868-71. <https://doi.org/10.1007/s005350050190>
10. Li S, Chen Z, Zhang Q, et al. Four cases of enterovesical fistula and the importance of CT in the diagnosis. *BJR case reports* 2016;3:20150124. <https://doi.org/10.1259/bjrcr.20150124>

**Correspondence:** Dr. Sender Herschorn, Division of Urology, Department of Surgery, University of Toronto, Toronto, ON, Canada; [s.herschorn@utoronto.ca](mailto:s.herschorn@utoronto.ca)