

Standing open magnetic resonance imaging improves detection and staging of pelvic organ prolapse

Lynn Stothers, MD^{1,2,3}; Jennifer A. Locke, MD, PhD¹; Marwa Abdulaziz, PhD¹;
Darren Lazare, MD³; Alex Kavanagh, MD^{1,2}; Andrew Macnab, MD^{1,4}

¹Department of Urologic Sciences, University of British Columbia, Vancouver, BC, Canada; ²International Collaboration on Repair Discoveries (ICORD); ³Department of Obstetrics and Gynecology, University of British Columbia, Vancouver, BC, Canada; ⁴Stellenbosch Institute for Advanced Study, Wallenberg Research Centre at Stellenbosch University, South Africa

Cite as: Stothers L, Locke JA, Abdulaziz M, et al. Standing open magnetic resonance imaging improves detection and staging of pelvic organ prolapse. *Can Urol Assoc J* 2021 August 26; Epub ahead of print. <http://dx.doi.org/10.5489/cuaj.7244>

Published online August 26, 2021

Acknowledgements/funding: The authors would like to thank the Vancouver Coastal Research Institute Translational research award program for funding support.

Corresponding author: Dr. Lynn Stothers, Blusson Spinal Cord Centre, Vancouver, BC, Canada; lynns@mail.ubc.ca

Abstract

Introduction: The role of imaging in pelvic organ prolapse (POP) assessment is unclear. Open magnetic resonance imaging (MRI) systems have a configuration that allows for imaging women with POP in different positions. Herein, we use a 0.5 Tesla open MRI to obtain supine, seated, and standing images. We then compare these images to evaluate the impact of posture on detection and staging of POP.

Methods: Women presenting with symptoms of POP at a tertiary care university hospital were asked to participate in this prospective cohort study. Symptom scores, POP-Q staging and three-position MRI imaging of the pelvis data were collected. The pubococcygeal line (PCL) was used to quantify within-patient changes in pelvic organ position as defined by: no displacement, <1 cm inferior to the PCL, mild (1–3 cm), moderate (3.1–6 cm), and severe (>6 cm) in the axial and sagittal T2-weighted images. Statistical analysis was completed (T-test; $p < 0.05$ significant).

Results: A total of 42 women, age range 40–78 years, participated. There was a significant difference in the mean values associated with anterior prolapse in the supine (0.7 ± 1.8), seated (2.4 ± 3.4), and upright (4.2 ± 1.6) positions ($p=0.015$). There was a significant difference in the mean values associated with apical prolapse in the supine (0.5 ± 1.5), seated (1.5 ± 1.4), and upright (2.1 ± 1.5) positions ($p=0.036$).

Conclusions: Our findings suggest that POP is more readily detected and upstaged with standing MRI images as compared to supine and seated positions. The developed two-minute standing MRI protocol may enable clinicians to better assess the extent of POP.

Introduction

The International Continence Society guideline for management of pelvic organ prolapse (POP) states that, “imaging may assist the clinical assessment of POP or intercurrent pelvic floor diagnoses,” but also emphasizes that it is entirely optional¹. There is recognition that gravity and posture affect the interplay of the pelvic support structures/organs and hence influence the detection and staging of POP²⁻⁵. Currently clinicians rely on the POP-Q score for staging and therapeutic decision making of POP⁶. However, physical examination in the upright position or when the patient performs a Valsalva maneuver during the POP-Q assessment are known to have inherent limitations⁶⁻⁸. Magnetic resonance imaging (MRI) has been proposed to be a useful method for diagnosing and staging POP¹. However, conventional scanners require the patient to be in a supine position, thus limiting visualization of the effects of posture and gravity.

Reoperation rate in POP is “unacceptably high and likely represents an underestimate of the true rate”⁹. DeLancey proposes that approximately 30% of the operations performed are reoperations, and states “the high prevalence of this problem indicates the need for treatment improvement which will only be possible if research clarifies causative biomechanical mechanisms and scientifically valid studies discover why operations fail”¹⁰. Suboptimal staging of POP with the POP-Q and conventional MRI assessments, due to the inability to capture the full influence of posture and gravity, may be a reason for such a high reoperation rate.

Hence, we propose imaging in the upright position, particularly in those women with symptoms of POP but negative POP-Q results. Open MRI systems allows patients to be imaged supine, seated, standing and fully weight bearing. In 1996 the concept of MRI imaging in the upright position was introduced by Fielding *et al.*¹¹. Evaluating 5 volunteers with the open MRI most of the pelvic floor structures were stable, with the exception of the posterior urethrovesical angle, which was increased in the sitting position as compared to the standing position. Apart from a study by Grob *et al.*², where the effect of upright scanning on staging with patients straining, the potential for standing MRI to add to the evaluation of POP was not explored further until the study of Friedman

*et al.*¹² Friedman *et al.*¹² compared MRI images of 11 women in the supine and standing positions and found differences in bladder position in patients with POP between the two positions ($p=0.03$). This was not observed in controls. As these studies included very few patients standing MRI is not part of imaging recommendations from international bodies^{1,13}.

While it is assumed that an accurately performed POP-Q physical exam equates with an accurate diagnosis we know that surgical failure rates are a concern. The objective of this study was to use a 0.5Tesla open MRI scanner to obtain supine, seated and standing images, and compare them to evaluate the impact of posture on detection and staging of POP in women. We propose a role for open MRI evaluation in women with symptoms of POP and a negative POP-Q assessment.

Methods

Study population

Following ethical approval (UBC Ethics H14-03507) we recruited women aged 18 years and older with symptomatic POP from female pelvic medicine subspecialty practices of urologists/urogynecologists at multiple tertiary care, university based medical practices. All subjects were surgically naïve for prolapse surgery. Initial evaluation and staging of patients included a complete history incorporating validated symptom questionnaires of the UDI-6^{14,15}, CRADI 8¹⁶ and POPDI-6¹⁷. Physical examination included height, weight, urinalysis, post void residual and POP-Q staging.

Imaging

All subjects were screened using the MRI safety checklist. Open MRI of the pelvis was performed using a 0.5Tesla system (Paramed Medical Systems, Italy) located at the University of British Columbia Centre for Hip Health. Subjects emptied their bladder prior to entering the scanner. To avoid any anatomical distortion neither contrast agents nor a surface body coil was used.

The dynamic sequence of imaging acquisition was supine followed by seated views followed by transition to the standing position. Parameters used to obtain axial and sagittal views of the full pelvis in the supine and seated positions were: TR 470 TE 10; echo train length, 32; bandwidth, 32 kHz; excitation, one; matrix size, 256×160; field of view, 100; section axial T2-weighted images with thickness 5 mm and slice gap 1mm. The protocol used a T2- weighted single-shot fast spin-echo (SSFSE) sequence (TR: 1,300 ms, TE: 60 ms, slice thickness: 6 mm, field of view 32–36 cm, matrix: 256×160, 1 excitation and half- Fourier acquisition.

Then subjects were transitioned to the standing position, and to assist with balance and stability a support bar was provided which patients held onto. The upright scan was limited to a 10cm field of view centered on the pubis in order to limit the time

patients had to stand still. The standing image acquisition time was 2-minutes in recognition that some patients find standing immobile for a long time difficult or uncomfortable. In addition, to address the possibility of subjects feeling faint when upright, all patients wore leg deep venous thrombosis external pneumatic compression devices.

Pelvic reference lines

To quantify the degree of descent of the pelvic organs and to compare the differences between standing, seated and supine images in centimeters, pelvic reference lines were used. The pubococcygeal line (PCL) was drawn as a line extending from the most inferior portion of the symphysis pubis to the tangent of the last coccygeal joint¹⁸. Differences between the supine, seated and upright distance of the bladder neck, cervix and pouch of Douglas from the PCL were measured in centimeters. Pelvic organ position was defined as: no displacement or less than 1cm inferior to the PCL, mild (1-3 cm), moderate (3.1-6 cm) and severe (>6 cm).

Statistical analysis

Demographic and clinical questionnaire data were reported as mean with standard deviation. Displacement related to the PCL was compared between supine, seated and upright position using IBM© SPSS statistical software for analysis with t-test $p < 0.05$ as significant.

Results

Patient demographics

Forty-two women with symptoms of POP participated. Mean age was 65 years (range 40-78). Eight percent had undergone forceps delivery. Thirteen were premenopausal and 29 post-menopausal. Parity, smoking history and validated symptom scores are shown in TABLE I and SUPPLEMENTAL SECTION. Mean body mass index was 33.5 kg/m (range 20–38). Mean POP-Q stage supine was 2.0 (Range 0–3.5) and POP-Q stage upright was 2.5 (Range 0–3.5).

Supine, seated and standing images of good diagnostic quality were obtained in all 42 subjects. A composite image comparing supine, seated and standing position in the same subject is shown as an example (FIGURE I). Specifically, all subjects were able to complete the 2-minute standing sequence without evidence of motion artefact. Results comparing mild, moderate and severe prolapse based on the PCL line are shown in TABLE II. There was a significant difference in the mean values associated with anterior prolapse in the supine (0.7 ± 1.8), seated (2.4 ± 3.4) and upright (4.2 ± 1.6) positions ($p = 0.015$). There was a significant difference in the mean values associated with apical prolapse in the supine (0.5 ± 1.5), seated (1.5 ± 1.4) and upright (2.1 ± 1.5) positions ($p = 0.036$).

Five of the 42 women had a negative POP-Q assessment for prolapse in both supine and upright but on the POPDI 6, answered affirmatively to question 2 relating to having a bulge that they could see or feel. In these five subjects prolapse was identified when imaged in the standing position (FIGURE II example). In brief, anterior prolapse was not seen in the supine scan that was observed in the upright scan.

Discussion

Overall, standing MRI imaging identified a greater degree of prolapse in symptomatic women with POP compared to supine imaging. These results suggest that open MRI should have a role in evaluating women with symptoms of POP, especially if they are found to have a negative POP-Q assessment. We also note that our protocol described, which includes a short scan time and central field of view using the 0.5Tesla MRI scanner, provides images of high diagnostic quality and can be applicable in subjects with a broad range of BMI's. The open MRI scanner has been primarily used in the context of orthopaedic care for the evaluation of weight bearing effects and the impact of gravity on joints and ligaments^{19,20}. This application of open MRI to better define and stage POP builds on our initial pilot studies applying the technology in urology^{12,21}.

In the 42 women studied, no downstaging occurred when comparing upright to supine images. Importantly, in the five subjects with symptoms of protrusion, but no detectable prolapse on POP-Q exam, prolapse was identified in the standing open MRI images.

The relevance of what we report relates to several clinical scenarios. Women who present with a clear history suggestive of prolapse can have negative findings on a clinical exam. The literature discusses reasons for this including supine positioning, patient inability to Valsalva effectively and limited ability to distinguish all organ positions during standing exam². However, in the context of imaging, neither the European Society of Urogenital Radiology pelvic floor working group nor the European Society of Gastrointestinal and Abdominal Radiology nor the International Urogynecology Association include standing position in their recommendations for standard MRI imaging in pelvic floor dysfunction.^{1,13}

In addition the choice of surgical procedure is primarily based on the stage of prolapse defined clinically. The greater detail of pelvic anatomy and enhanced definition of organ relationships provided by standing imaging may allow for greater refinement in surgical correction of POP, as the clinician is able to choose a procedure that better matches the anatomical defect(s). We propose that the additional information standing images provide will help reduce the rate of post-operative failure. For example, in a patient who presents with only anterior prolapse on POP-Q exam but is discovered with standing MRI to have apical prolapse. This patient may benefit from repair of both anterior and apical prolapse in terms of possible post-operative failure.

Although we found a statistical difference in stage between seated and supine images, we suggest that there is no clinical benefit to seated imaging in women who are able to stand. The rationale for studying subjects when seated was to aid in the evaluation of women who cannot weight bear, such as those with neurologic conditions. This is illustrated (FIGURE I) where prolapse identified in the standing position is not demonstrated when seated. Iacobellis *et al.* also found differences between organ position between the supine and seated position²². In our study some subjects upstaging was evident when seated, but, the full extent was not demonstrated until standing. A further consideration is that women who have severe prolapse detected supine compress the prolapse when seated and this can result in artificial downstaging of the extent of POP.

We suggest that the protocol described for supine and standing image acquisition can be used clinically; the combination of using a 0.5Tesla open magnet and ability to image patients when standing upright allowed the full effect of posture and gravity to be evident, and provided diagnostic quality images. Also, because the standing image segment of the protocol involves a short image acquisition time (2-minutes), as a limited central field of view is scanned, it is possible to scan almost anyone who can stand. Keeping the duration of the standing sequence short also reduces potential motion artifact.

Importantly this protocol was designed to be noninvasive, free of radiation and practical clinically, with short duration and without coils or contrast. Because this patient group frequently has lower urinary tract symptoms, the potential exists for stress or urgency incontinence during the study. Hence patients voided prior to being scanned and none were incontinent. We suggest that aiming to standardize bladder volume for this investigation without catheterization is not practical and would convert the protocol into an invasive study. Furthermore, many women with POP have incomplete bladder emptying as part of their condition.

Grob *et al.* reported the effect of upright scanning on staging with patients straining². They found the distance from the bladder neck, cervix and pouch of Douglas to the PCL increased significantly from the supine straining position relative to an upright rest and straining position. However, this study involved a small presurgical cohort of 15 subjects who had stage 2 or higher POP. The authors state image quality obtained was not optimal; their technique required the use of a coil, a lower Tesla magnet and inclined rather than fully vertical imaging. In addition, their protocol was restricted as they could not image subjects with USA jean size 14 or greater, and the National Health and Nutrition Examination Survey indicate that 66.9% of women in the USA are overweight or obese (definition of BMI 25-29.9 for overweight and 30 or more for obese)²³.

Our ability to quantify upstaging through upright imaging builds on the discipline of using pelvic reference lines^{13, 18}. A technical point when considering the benefits of standing images is the current practice of viewing supine images in a vertical orientation

and publishing illustrations of them in the same manner. We suggest that for clarity, with the availability of upright images, supine images should be shown horizontally and standing images vertically.

We recognize limitations of this study. In this study patients voided prior to starting the MRI and filled spontaneously throughout the study. The International Consultation on Incontinence recommendation is that patients should have an empty bladder during physical examination to avoid a filled bladder causing an obstruction on descensus during the Valsalva maneuver thus missing a diagnosis of POP²⁴. Patients did not strain, cough or Valsalva; this was for practical reasons to limit the duration of the protocol, limit motion artifact and ensure image quality. Reporting of posterior prolapse was not included; our protocol was designed to be noninvasive and hence avoid contrast. Comparison with women without POP was not made; control data have been published previously¹². Patients were screened for contraindications to safe conduct of MRI; not all patients with POP will be eligible. This technique does require access to an open MRI facility. These are increasing in number and thus may be a viable option in the future. All participants were sufficiently able bodied to be able to stand; in practice some patients will be too compromised in this regard to be able to complete the standing segment of the protocol, or will be wheelchair bound. Due to the cost of each MRO study, we were limited by funding restraints to recruiting only 42 patients in this study; it may be of benefit to evaluate more women with symptoms on POP in future studies using this technology.

Future directions could include the investigation of pre and post-operative patients to understand the anatomic changes achieved surgically and how these are affected by upright posture. This could potentially impact changes in surgical technique for primary and secondary procedures. In future we could also perform a randomized clinical trial to compare the surgical outcomes in those women who have negative POP-Q assessments who undergo MRO evaluation who have a positive finding and those who do not to determine the pre-operative role of standing MRO in surgical planning/counseling. Future studies should include exploration of additional pelvic reference lines to define the impact of upright posture on quantification of rectal prolapse. In complex cases 3D image reconstruction from upright images can be applied where the protocol allows for high quality images to be obtained²¹. Biomechanical models of pelvic organ relationships¹⁰, are currently done using supine images, and are one area to explore in future research using standing imaging. Additional studies could also allow exploration of how the POP-Q stage could be complimented by the addition of standing imaging data. The image quality that can be obtained using this protocol may have applicability to understanding changes to the female urethra based on posture and gravity.

Conclusions

Standing images obtained using this open MRI technology allow the influence of posture and gravity on POP to be identified. Comparison of standing to supine images indicates statistically significant upstaging in both anterior prolapse and apical prolapse. The developed 2-minute standing MRI protocol may enable clinicians to better assess the extent of POP, especially in those with a negative POP-Q assessment.

DRAFT

References

1. Haylen BT, Maher CF, Barber MD, et al. An International Urogynecological Association (IUGA) / International Continence Society (ICS) Joint Report on the Terminology for Female Pelvic Organ Prolapse (POP). *Neurourol Urodyn* 2016;35(2):137-68. doi:10.1002/nau.22922
2. Grob ATM, Olde Heuvel J, Futterer JJ, et al. Underestimation of pelvic organ prolapse in the supine straining position, based on magnetic resonance imaging findings. *Int Urogynecol J* 2019;30(11):1939-1944. doi:10.1007/s00192-018-03862-0
3. Bø K. Pelvic floor muscle strength and response to pelvic floor muscle training for stress urinary incontinence. *Neurourol Urodyn* 2003;22(7):654-8. doi:10.1002/nau.10153
4. Barber MD, Lambers A, Visco AG, Bump RC. Effect of patient position on clinical evaluation of pelvic organ prolapse. *Obstet Gynecol* 2000;96(1):18-22. doi:10.1016/s0029-7844(00)00859-0
5. Hendrix SL, Clark A, Nygaard I, Aragaki A, Barnabei V, McTiernan A. Pelvic organ prolapse in the Women's Health Initiative: gravity and gravidity. *Am J Obstet Gynecol* 2002;186(6):1160-6. doi:10.1067/mob.2002.123819
6. Bump RC. The POP-Q system: two decades of progress and debate. *Int Urogynecol J* 2014;25(4):441-3. doi:10.1007/s00192-013-2262-0
7. Bump RC, Mattiasson A, Bø K, et al. The standardization of terminology of female pelvic organ prolapse and pelvic floor dysfunction. *Am J Obstet Gynecol* 1996;175(1):10-7. doi:10.1016/s0002-9378(96)70243-0
8. Riss P, Dwyer PL. The POP-Q classification system: looking back and looking forward. *Int Urogynecol J* 2014;25(4):439-40. doi:10.1007/s00192-013-2311-8
9. Denman MA, Gregory WT, Boyles SH, Smith V, Edwards SR, Clark AL. Reoperation 10 years after surgically managed pelvic organ prolapse and urinary incontinence. *Am J Obstet Gynecol* 2008;198(5):555.e1-5. doi:10.1016/j.ajog.2008.01.051
10. DeLancey JO. The hidden epidemic of pelvic floor dysfunction: achievable goals for improved prevention and treatment. *Am J Obstet Gynecol* 2005;192(5):1488-95. doi:10.1016/j.ajog.2005.02.028
11. Fielding JR, Versi E, Mulkern RV, Lerner MH, Griffiths DJ, Jolesz FA. MR imaging of the female pelvic floor in the supine and upright positions. *J Magn Reson Imaging* 1996;6(6):961-3. doi:10.1002/jmri.1880060622
12. Friedman B, Stothers L, Lazare D, Macnab A. Positional pelvic organ prolapse (POP) evaluation using open, weight-bearing magnetic resonance imaging (MRI). *Can Urol Assoc J* 2015;9(5-6):197-200. doi:10.5489/cuaj.2767
13. El Sayed RF, Alt CD, Maccioni F, et al. Magnetic resonance imaging of pelvic floor dysfunction - joint recommendations of the ESUR and ESGAR Pelvic Floor Working Group. *Eur Radiol* 2017;27(5):2067-2085. doi:10.1007/s00330-016-4471-7
14. Shumaker SA, Wyman JF, Uebersax JS, McClish D, Fantl JA. Health-related quality of life measures for women with urinary incontinence: the Incontinence

- Impact Questionnaire and the Urogenital Distress Inventory. Continence Program in Women (CPW) Research Group. *Qual Life Res* 1994;3(5):291-306.
doi:10.1007/BF00451721
15. Cam C, Sakalli M, Ay P, Cam M, Karateke A. Validation of the short forms of the incontinence impact questionnaire (IIQ-7) and the urogenital distress inventory (UDI-6) in a Turkish population. *Neurourol Urodyn* 2007;26(1):129-33.
doi:10.1002/nau.20292
 16. Barber MD, Kuchibhatla MN, Pieper CF, Bump RC. Psychometric evaluation of 2 comprehensive condition-specific quality of life instruments for women with pelvic floor disorders. *Am J Obstet Gynecol* 2001;185(6):1388-95.
doi:10.1067/mob.2001.118659
 17. Barber MD, Walters MD, Bump RC. Short forms of two condition-specific quality-of-life questionnaires for women with pelvic floor disorders (PFDI-20 and PFIQ-7). *Am J Obstet Gynecol* 2005;193(1):103-13.
doi:10.1016/j.ajog.2004.12.025
 18. Betschart C, Chen L, Ashton-Miller JA, Delancey JO. On pelvic reference lines and the MR evaluation of genital prolapse: a proposal for standardization using the Pelvic Inclination Correction System. *Int Urogynecol J* 2013;24(9):1421-8.
doi:10.1007/s00192-013-2100-4
 19. Yamamura M, Miki H, Nakamura N, Murai M, Yoshikawa H, Sugano N. Open-configuration MRI study of femoro-acetabular impingement. *J Orthop Res* 2007;25(12):1582-8. doi:10.1002/jor.20448
 20. Johal P, Williams A, Wragg P, Hunt D, Gedroyc W. Tibio-femoral movement in the living knee. A study of weight bearing and non-weight bearing knee kinematics using 'interventional' MRI. *J Biomech* 2005;38(2):269-76.
doi:10.1016/j.jbiomech.2004.02.008
 21. Abdulaziz M, Deegan EG, Kavanagh A, Stothers L, Pugash D, Macnab A. Advances in basic science methodologies for clinical diagnosis in female stress urinary incontinence. *Can Urol Assoc J* 2017;11(6Suppl2):S117-S120.
doi:10.5489/cuaj.4583
 22. Iacobellis F, Brillantino A, Renzi A, et al. MR Imaging in Diagnosis of Pelvic Floor Descent: Supine versus Sitting Position. *Gastroenterol Res Pract* 2016:6594152. doi:10.1155/2016/6594152
 23. NIH Overweight & Obesity Statistics. 2021. Accessed April 9, 2021.
<https://www.niddk.nih.gov/health-information/health-statistics/overweight-obesity>
 24. Abrams P, Andersson KE, Apostolidis A, et al. 6th International Consultation on Incontinence. Recommendations of the International Scientific Committee: Evaluation and treatment of urinary incontinence, pelvic organ prolapse and faecal incontinence. *Neurourol Urodyn* 2018;37(7):2271-2272.
doi:10.1002/nau.23551

Figures and Tables

Fig. 1. A composite image of (A) supine, (B) seated, and (C) upright scans in a 65-year-old G2P2 post-menopausal female with prolapse staged using the pubococcygeal line. The standing image demonstrates the presence of significant prolapse upstaging pelvic organ prolapse (POP) in this subject.

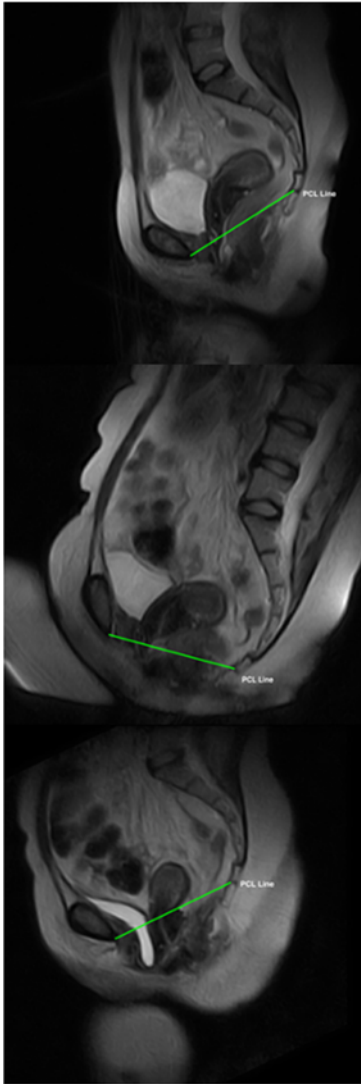


Fig. 2. A sample image demonstrating the extent to which gravity dependent pelvic organ prolapse (POP) can be upstaged by comparing standing to supine images. A 60-year-old G1P1 female who presented with increasing urinary incontinence and a feeling of vaginal heaviness when ambulant. On pelvic exam supine and inclined, at rest and with Valsalva, revealed no organ descent. Evaluation using upright open imaging shows (A) supine and (B) standing imaging confirming evidence of prolapse with the effects of posture and gravity. This shows also shows the adequacy of the abbreviated two-minute scan for diagnostic purposes.

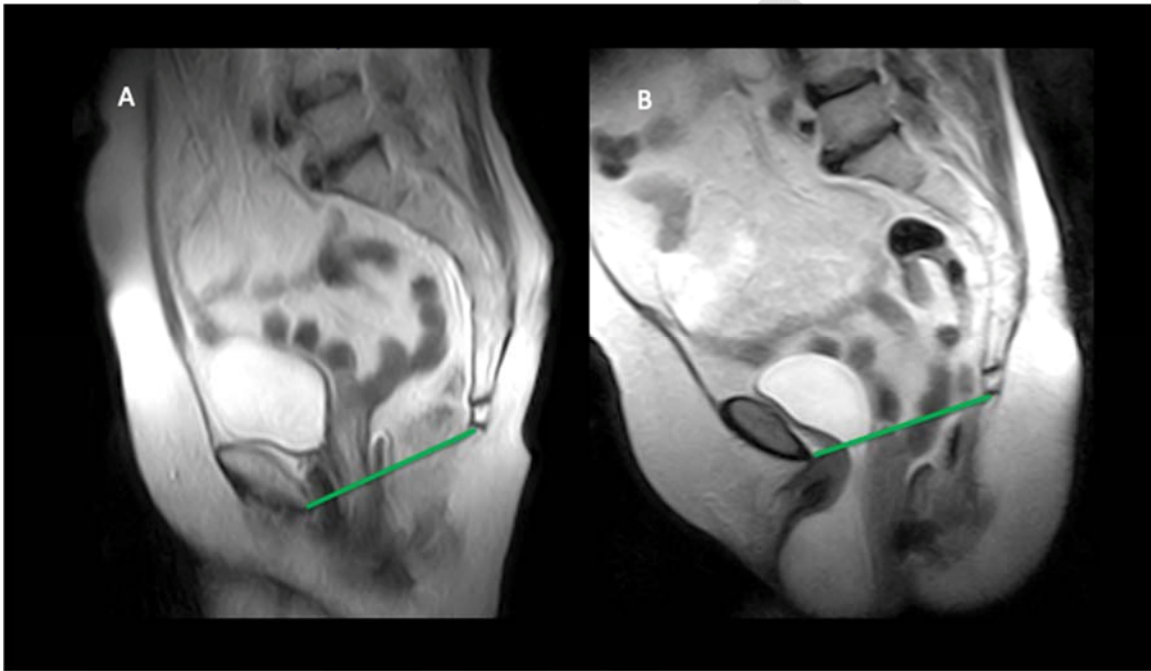


Table 1. Demographics of 42 women with symptomatic pelvic organ prolapse who underwent open MRI scanning in the supine, seated, and upright full weightbearing positions

	Symptomatic subjects POP (N=42)			
Parity	0	1	2	3
	1	15	20	6
Smoking history	Never	Current	Remote	
	35	0	7	

MRI: magnetic resonance imaging.

Table 2. Percentage of subjects based on 42 women with symptoms of prolapse who have findings of anterior and apical prolapse on open MRI images (based on severity of finding)

		Mild	Moderate	Severe
Supine	Anterior prolapse	6%	1%	1%
	Apical Prolapse	22%	1%	1%
Upright	Anterior prolapse	36%	42%	12%
	Apical Prolapse	36%	12%	1%

MRI: magnetic resonance imaging.

DRAFT