

Case — Persistent vesico-cutaneous fistula in an “hour-glass” deformity ileocystoplasty: Successful repair using abdominal wall perforator flaps

James Paul Joseph Ross, MD¹; Hannah St. Dennis Katz, MD²; Jing Zhang, MD, PhD²; Humberto Vigil, MD, MSc¹; Duane Hickling, MD, MSc¹

¹Division of Urology, Department of Surgery, University of Ottawa, Ottawa, ON, Canada; ²Division of Plastic Surgery, Department of Surgery, University of Ottawa, Ottawa, ON, Canada

Cite as: Ross JPJ, St. Denis Katz H, Zhang J, et al. Case — Persistent vesico-cutaneous fistula in an “hour-glass” deformity ileocystoplasty: Successful repair using abdominal wall perforator flaps. *Can Urol Assoc J* 2021;15(7):E373-5. <http://dx.doi.org/10.5489/cuaj.6894>

Published online December 15, 2020

Introduction

Bladder augmentation is a surgery to increase bladder capacity and compliance. It involves the transposition of a tissue segment, most commonly ileum (ileocystoplasty), into the native bladder. A narrowing can develop at the vesico-intestinal anastomosis resulting in an “hourglass deformity;” this is a rare complication, with few studies describing clinical implications and treatment.¹

We present a case of a 35-year-old male with a history of bladder exstrophy and ileocystoplasty who presented with an hourglass deformity with a large stone in both the augmented and native bladder. Following open cystolithotomy, he developed a vesico-cutaneous fistula requiring a complex repair.

Case report

The patient is a 35-year-old male born with bladder exstrophy who had initial repair in infancy. In childhood, he underwent bladder neck closure and ileocystoplasty with a continent catheterizable channel (Mitrofanoff). He was referred to the adult reconstructive urology service with two large calculi within the augmented and native bladder.

After failed endoscopic management, the patient was brought for open cystolithotomy. During initial dissection, significant scarring along his previous midline incision was noted. An “hourglass” deformity was noted, with a large augment and small native bladder separated by a narrowed

and elongated vesico-intestinal anastomosis. Both calculi were removed, and the bladder was closed and confirmed to be watertight.

Two days postoperatively, the patient developed a small wound dehiscence and urine leak, which was confirmed via cystography. A urine leak persisted despite maximal drainage (bilateral nephrostomy tubes and channel catheter) and he was brought back to the operating room (OR) for primary closure. Repeat closure was initially successful, however, upon capping his nephrostomy tubes, the small urine leak recurred, eventually developing into a mature vesico-cutaneous fistula (Fig. 1).

After maturation of the fistula, the patient was brought back to the OR in a joint case with the plastic and reconstructive surgery team for definitive repair. The fistulous tract was identified and excised circumferentially. A large cystotomy was created and the posterior wall of the narrowed vesico-intestinal anastomosis was incised vertically through the scar tissue. The incision was closed horizontally in a Hienke-Mikulicz fashion to widen the narrowed anastomosis (Fig. 2). The anterior bladder was closed in a watertight manner.

To reconstruct the lower abdominal wall defect and provide soft tissue coverage of the exposed augmented bladder, a pedicled left hemi-abdominal wall flap was elevated above the fascia using a deep inferior epigastric artery (DIEA) and a superficial circumflex iliac artery (SCIA) perforator flap. The medial part of the flap was deepithelialized, folded over itself, and used to eliminate the dead space in the central lower abdomen. The lateral part of the donor site was closed in a V-Y fashion (Fig. 3).

Postoperatively, he was left with a catheter in his channel, a suprapubic catheter, and bilateral nephrostomy tubes. Computed tomography (CT) cystogram at six weeks revealed persistent urine extravasation. An additional six weeks of maximal urinary diversion was recommended and a repeat CT cystogram at three months was negative for urine leak. Furthermore, imaging demonstrated significant widening of the vesico-enteric anastomosis (Fig. 4). The patient's indwell-

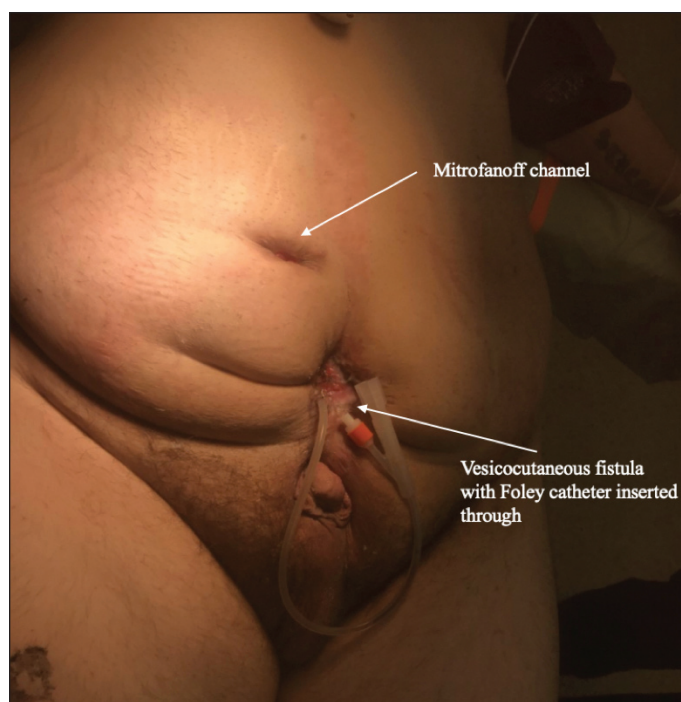


Fig. 1. Patient with previously repaired bladder exstrophy and ileocystoplasty/ Mitrofanoff channel creation with vesico-cutaneous fistula.

ing catheters and bilateral nephrostomy tubes were removed, and the patient successfully resumed intermittent catheterization without difficulty. He has had no recurrent urinary tract infections or urolithiasis to date.

Discussion

Ileocystoplasty is a surgical procedure involving the transposition of a segment of ileum into the native bladder in patients with reduced bladder capacity and/or compliance, typically performed when more conservative treatments have

failed. If the initial cystostomy is too small, the anastomosis may narrow, resulting in an “hourglass deformity.”¹

There are few studies on sequelae and management of hourglass deformity post-augmentation. The largest is a case series of seven patients who underwent removal of the ileal augment, enlargement of the cystostomy, and re-anastomosis of the ileal patch. Postoperative followup demonstrated resolution of the hourglass deformity and improvement in voiding pressures.¹ A study on the need for re-augmentation in patients with bladder exstrophy found the formation of an hourglass deformity to be an indication for re-augmentation in one of 17 patients.²

Patients with bladder exstrophy are challenging, given their small native bladder, making enlargement of the original cystostomy difficult. After a failed attempt at primary bladder repair, on reoperation, we repaired the hourglass deformity with a previously undescribed technique wherein a deep vertical incision was made posteriorly through the area of narrowing and closed in a Hienke-Mikulicz fashion. Although on postoperative cystogram the narrow anastomotic segment appeared more patent, long-term followup with clinical, radiographic, and video-urodynamic studies will be required to evaluate overall success and sustainability.

At the time of initial cystolithotomy, there was significant scarring of the patient’s midline abdomen, given his history of multiple corrective surgeries and wide pubic and rectus diastases. This placed him at higher risk of wound complications and was thought to contribute to wound dehiscence, as well as the persistence of his vesico-cutaneous fistula. Challenging wounds are an indication to consider other reconstructive options to provide well-vascularized tissue interposition, wound healing, and tension-free closure. In this case, a fasciocutaneous perforator flap was used. This flap type can be harvested based on any dominant and clinically relevant perforator vessel and provides more precise dissection and vascularity than a traditional myocutaneous flap with minimal donor site morbidity.^{3,4}

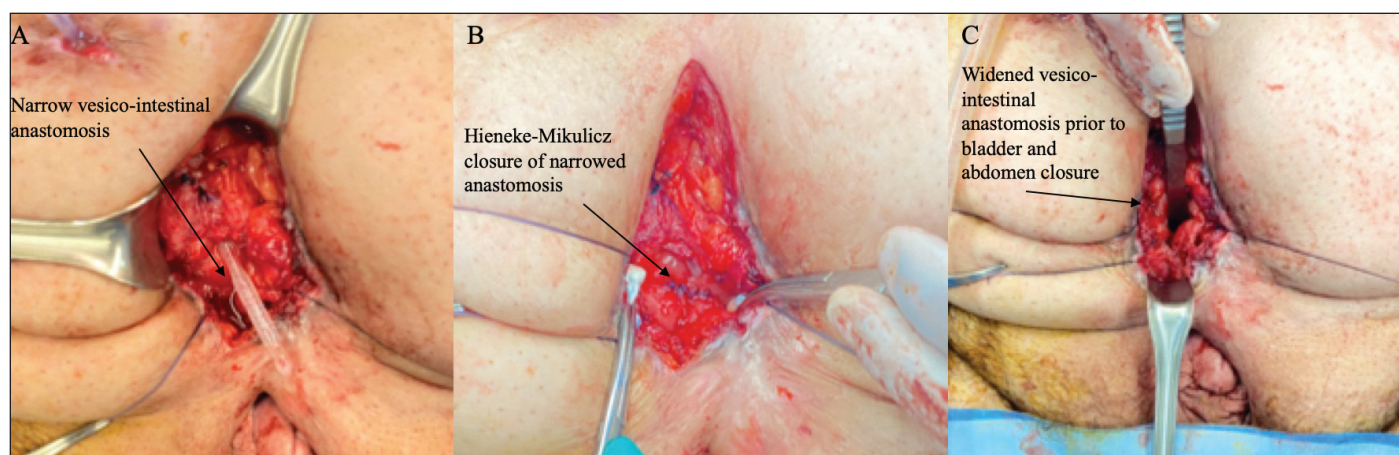


Fig. 2. (A) Post-excision of vesico-cutaneous fistula and cystostomy with catheter through Mitrofanoff channel and narrowed vesico-intestinal anastomosis. (B) Hienke-Mikulicz closure of vesico-intestinal stenosis in “hourglass bladder.” (C) Wider vesico-intestinal anastomosis following repair of stenotic segment.

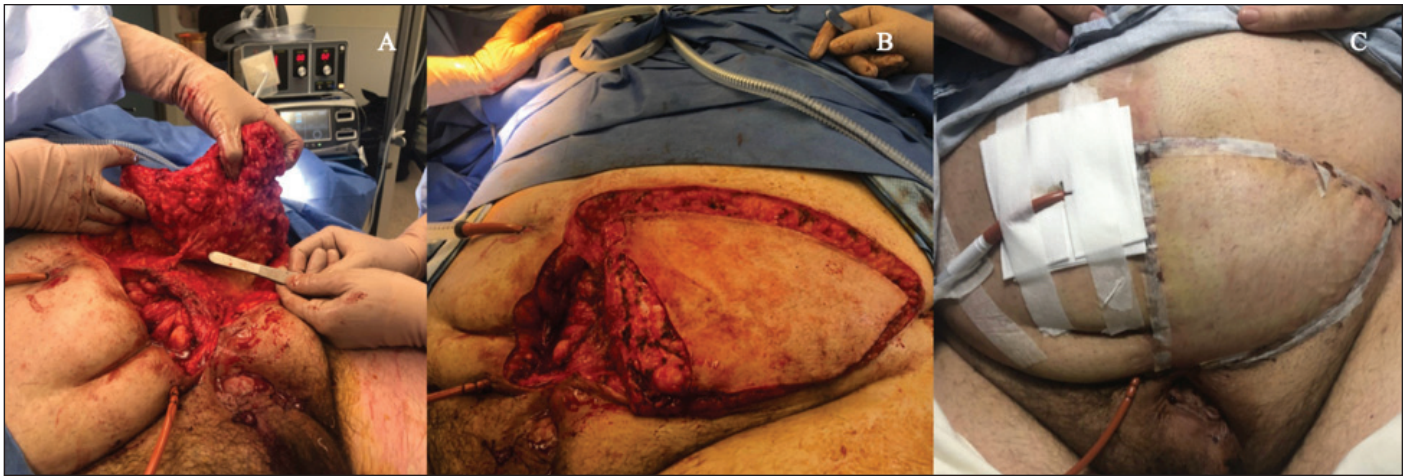


Fig. 3. (A) Identification of deep epigastric perforator vessel. (B) Pedicled left hemi-abdominal wall flap with the medial aspect of the skin paddle deepithelialized, folded over on itself, and used to eliminate the dead space in the central lower abdomen. (C) Postoperative appearance of pedicled left hemi-abdominal wall flap.

The perforator flap can be used for a variety of reconstructive procedures.⁴ In this case, a large hemi-abdominal wall flap was raised based on two perforators (DIEA and SCIA) without violation of abdominal fascia or injury of abdominal muscle.⁵ The pedicled flap provided reliable soft tissue coverage for a large, midline abdominal wound with exposed bladder and augment in the same surgical field. This novel approach of a pedicled perforator flap allowed us to successfully avoid the use of a myocutaneous thigh flap, such as the gracilis flap, which is a more commonly used option for lower abdominal wall reconstruction.

Conclusions

Hourglass deformity is a rare complication following ileocystoplasty. We described the formation of a vesico-cutaneous fistula following open cystolithotomy in an hourglass bladder that was successfully repaired with a posterior Hienke-Mikulicz incision and an abdominal wall perforator flap.

Competing interests: Dr. Hickling has been an advisory board member for Allergan and Pfizer; and has received a travel grant from Allergan. No other authors report any competing personal or financial interests related to this work.

This paper has been peer-reviewed.

References

1. Pariser JJ, Elliott SP. Opportunities for augmentation cystoplasty revision without additional bowel harvest: "Hourglass" deformity or non-detubularized augment. *Can Urol Assoc J* 2019;13:E140-4. <https://doi.org/10.5489/cuaj.5548>
2. Benz KS, Jayman J, Doersch K, et al. Bladder re-augmentation in classic bladder exstrophy: Risk factors and prevention. *Urology* 2018;115:157-61. <https://doi.org/10.1016/j.urology.2018.02.003>
3. Hou C, Chang S, Lin J, et al. A brief history of perforator flaps. In: *Surgical Atlas of Perforator Flaps: A Microsurgical Dissection Technique*. Edited by C Hou, S Chang, J Lin, et al. Dordrecht: Springer Netherlands 2015. pp 1-4. <https://doi.org/10.1007/978-94-017-9834-1>
4. Kim JT, Kim SW. Perforator flap vs. conventional flap. *J Korean Med Sci* 2015;30:514-22. <https://doi.org/10.3346/jkms.2015.30.5.514>
5. Buntic R. The deep inferior epigastric artery perforator (DIEP) flap. Available at: <https://www.microsurgery.org/diep>. Accessed July 26, 2020

Correspondence: Dr. Duane Hickling, Division of Urology, Department of Surgery, University of Ottawa, Ottawa, ON, Canada; dhickling@toh.ca

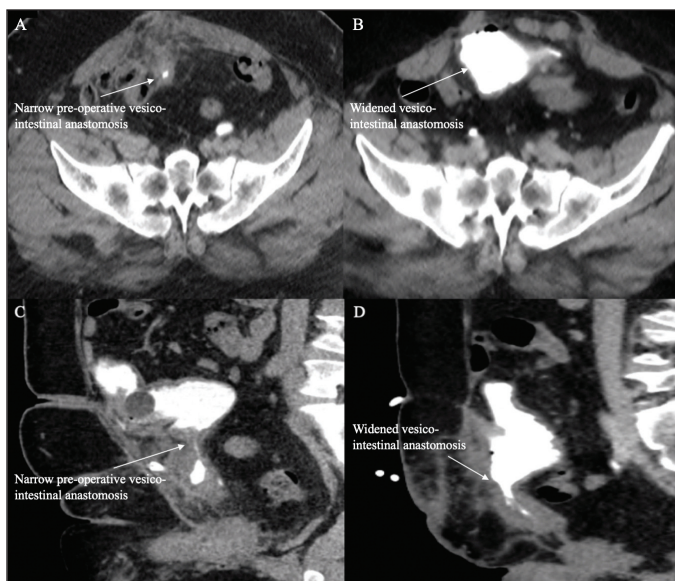


Fig. 4. (A) Axial view of preoperative cystogram of hourglass ileocystoplasty. (B) Axial view of postoperative cystogram following Hienke-Mikulicz repair of stenotic segment. (C) Sagittal view of preoperative cystogram of hourglass ileocystoplasty. (D) Sagittal view of postoperative cystogram following Hienke-Mikulicz repair of stenotic segment.