

## Case – Unique complication of continent catheterizable stoma after bariatric surgery

Rebecca Briskin, DO; Humphrey Atiemo, MD

Henry Ford Health System, Detroit, MI, United States

**Cite as:** Briskin R, Atiemo H. Case – Unique complication of continent catheterizable stoma after bariatric surgery. *Can Urol Assoc J* 2021;15(7):E370-2. <http://dx.doi.org/10.5489/auaj.6773>

Published online December 15, 2020

### Introduction

Indiana augmentation cystoplasty (IAC) is a popular form of continent catheterizable diversion where the terminal ileum forms a catheterizable channel, and a buttressed ileocecal valve is used as the continence mechanism. The ascending colon is detubularized and sutured to the opened bladder, creating a low pressure urinary reservoir.<sup>1</sup> Elimination of urinary drainage bags, increased independence, and improved body image have been cited by up to 80% of patients undergoing continent urinary tract reconstruction as factors improving quality of life.<sup>2</sup>

Limited literature exists on standards of management of efferent channel catheterization complications. Difficulty catheterizing may represent stenosis or stricture of the efferent limb, or the creation of a false passage during repeated catheterizations. Initial evaluation should include endoscopy to investigate the channel and pouch, in particular the efferent limb, which tends to elongate and stretch over time. Revision requires mobilization and shortening of the channel via an open approach. Care must be taken to preserve channel functionality. Principles of open revision generally employ the simplest technique possible, while avoiding creating new complications, such as bowel obstruction and fistula. Typically, the efferent limb is mobilized and the revision efforts are localized to the region of the pouch to avoid the rest of the abdominal cavity unless necessary.<sup>3</sup> In this case report, we present a patient with difficulty catheterizing the efferent limb of her IAC after significant weight loss.

### Case report

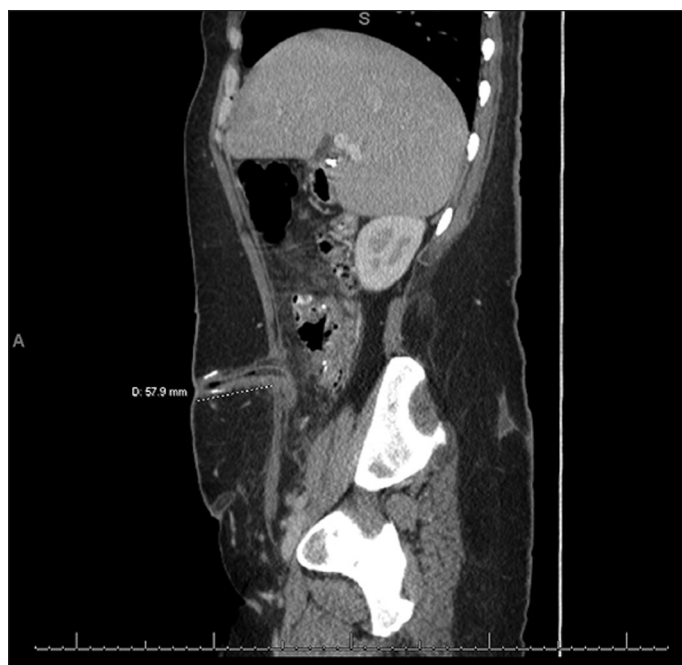A 40-year-old female presented to the urology department with a history of non-obstructive urinary retention. Her past

medical history was significant for anorexia, bulimia, and bipolar disorder. She was unable to perform intermittent self-catheterization (ISC) due to both body habitus and history of sexual abuse. Her past surgical history was significant for an Interstim trial and prior suprapubic tube (SPT) placement. Her Interstim device was removed due to lack of efficacy, and she did not desire a SPT for long-term treatment. In July 2012, she underwent an IAC with continent catheterizable stoma and appendectomy. At the time of her initial surgery, her body mass index (BMI) was 33 kg/m<sup>2</sup>. A postoperative computed tomography (CT) scan of her abdomen revealed the length of the catheterizable channel to be 5.8 cm measured from the skin to anterior rectus fascia (Fig. 1).

Within 15 months of her procedure, she experienced significant weight gain, and her BMI had increased to 51.4 kg/m<sup>2</sup> by December 2013. She reached her maximal BMI of 60 kg/m<sup>2</sup> in September 2016. The catheterizable channel now measured 7.3 cm in length from the skin to the anterior rectus fascia (Fig. 2). In spite of modest weight loss, she sought consultation with a bariatric surgeon at a BMI of 46 kg/m<sup>2</sup>. She underwent a laparoscopic sleeve gastrectomy in August 2018, and she developed increasing difficulty and pain with stomal catheterization within 10 days.

A subsequent cystoscopy with direct visualization of a catheter advanced through the stoma demonstrated excessive mucosal redundancy of the channel, impeding catheter passage. A CT scan confirmed redundancy of the continent catheterizable channel and an incidental fat containing parastomal hernia adjacent to her stoma (Fig. 3). At this time, the length of the continent catheterizable channel was 6.6 cm. With her continued weight loss, the patient developed a large abdominal pannus, further exacerbating catheterization difficulty. Ptosis of the channel required the patient to lift her pannus in order to pass an 18-French (18F) red rubber catheter.

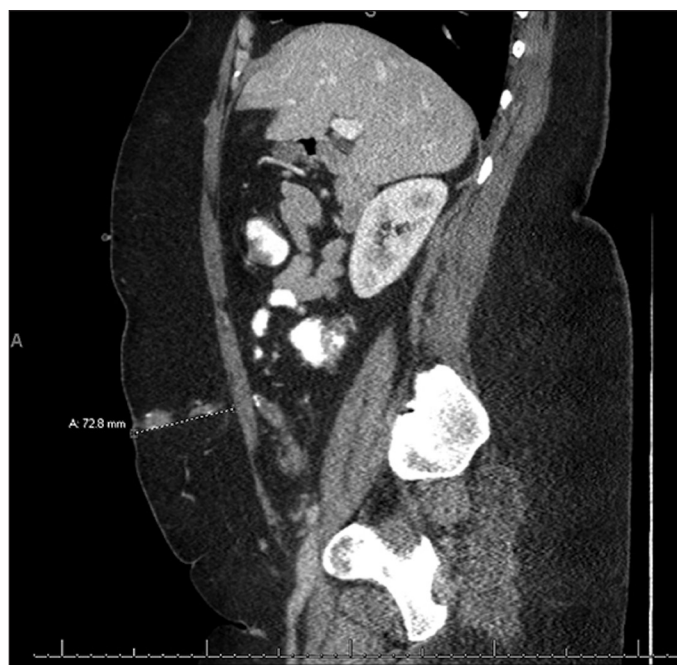By one year after sleeve gastrectomy, the patient had lost 72 kg, and her BMI had stabilized at 30.7 kg/m<sup>2</sup>. ISC had become extremely difficult and time-consuming. Stomal leakage was experienced nightly, accompanied by the sensation of incomplete emptying with ISC, thus a decision was made to revise her continent catheterizable stoma with concomitant parastomal hernia repair and panniculectomy.



**Fig. 1.** Computed tomography of the abdomen and pelvis after initial continent catheterizable stoma creation. Skin to fascial distance measures 57.9 mm.

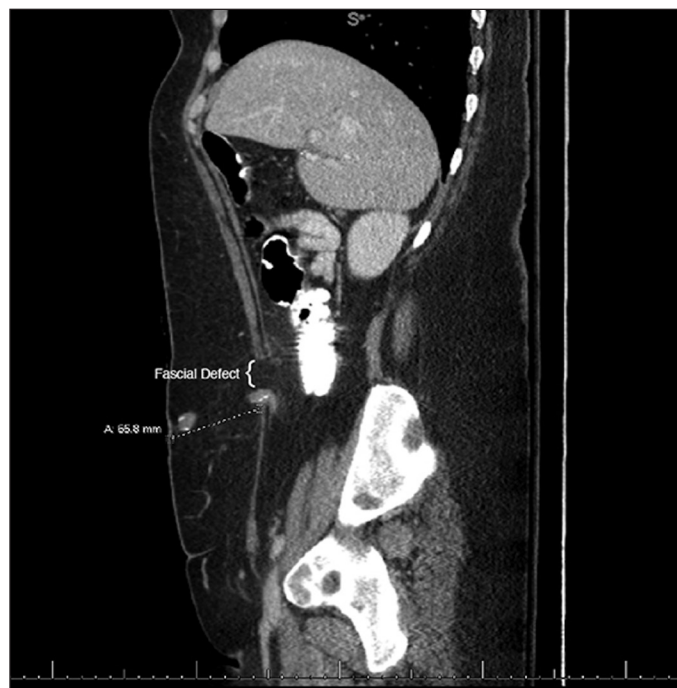
The abdominal cavity was entered via the prior midline abdominal incision and adhesiolysis was performed, isolating and releasing the catheterizable channel of tapered ileum. The channel was dissected away from the skin and subcutaneous adipose with cautery using a Colorado tip. The channel was grasped with a Babcock clamp and inverted through the fascial defect.

Once the efferent channel was disconnected from the fascia, buckling of the channel was noted adjacent to the ileocecal junction when passing an 18F red rubber catheter. A single 2-0 polydioxanone suture was placed in a Lembert fashion under the area of buckling for reinforcement, and the catheter was then easily passable into the augmented bladder. After the plastic surgeon had raised skin flaps and removed excess tissue in anticipation of panniculectomy, the stoma was re-sited through the rectus muscle and fascia, up to the level of the skin, away from the pre-existing hernia. The channel was straightened and shortened by removing 3 cm from the distal end. The channel was spatulated on the anti-mesenteric side and secured to the skin with polyglactin sutures. The channel was also secured to the anterior abdominal wall with a 3-0 polydioxanone to further facilitate straightening the channel. The bladder was then refilled with 600 mL, confirming absence of leakage from the channel, and a 14F catheter was easily passed with return of clear fluid. Lastly, the general surgeon performed repair of the parastomal hernia with bio-absorbable mesh, and the plastic surgeon completed the panniculectomy. A 14F stomal catheter with a catheter plug, and a 16F Foley catheter were in place at the conclusion of the procedure.



**Fig. 2.** Computed tomography of the abdomen and pelvis at maximal body mass index. Skin to fascial distance measures 72.8 mm.

Three weeks postoperatively, her stomal catheter and Foley catheter were removed, and the patient resumed ISC without issue. At a three-month followup visit, she reported complete resolution of catheterization difficulty, and she continues to perform ISC 4–6 times daily.



**Fig. 3.** Computed tomography of the abdomen and pelvis after bariatric surgery with fascial defect and parastomal hernia. Skin to fascial distance measures 65.8 mm.

## Discussion

Complications of a continent catheterizable channel in the setting of morbid obesity and bariatric surgery are a rare but relevant entity. To our knowledge, there are no studies that investigate obesity-related efferent channel complications. This presentation is unique in that excessive weight gain did not impede her ability to catheterize her stoma, but rather the extreme weight loss after seeking bariatric surgery, which led to mucosal redundancy of the catheterizable channel. This case elucidates the ways in which the catheterizable channel may change with changing body habitus, elongating with an increasing BMI, and inability to retract spontaneously after a subsequent decrease in BMI. Enterocystoplasty is more commonly performed in children, and as these patients mature, it is important to anticipate future complications that may arise with aging, such as fluctuations in weight.

In the setting of profound weight loss, conservative or iatrogenic continent catheterizable channel complications may arise. This case stresses the significance of weight-related complications in patients with prior enterocystoplasty with continent catheterizable stoma. The author feels that bariatric surgery for overall health benefits should not be discouraged in patients with prior IAC; however, potential complications should be discussed preoperatively. Proper evaluation should include voiding diary, cystoscopy while passing a catheter through the stoma from above, and appro-

priate imaging to assess for possible parastomal hernias. Timing of intervention is critical, and must be coordinated when weight loss has stabilized, as well as in concert with other specialties if multiple procedures may be required. Surgical correction of efferent channel elongation may be necessary and can be successfully achieved with correction of any parastomal hernia, with shortening and re-siting of the catheterizable channel.

This paper has been peer-reviewed.

**Competing interests:** The authors report no competing personal or financial interests related to this work.

## References

1. Khavari R, Fletcher SG, Liu J, et al. A modification to augmentation cystoplasty with catheterizable stoma for neurogenic patients: technique and long-term results. *Urology* 2012;80:460-4. <https://doi.org/10.1016/j.urology.2012.03.038>
2. Zommick JN, Simoneau AR, Skinner DG, et al. Continent lower urinary tract reconstruction in the cervical spinal cord injured population. *J Urol* 2003;169:2184-7. <https://doi.org/10.1097/01.ju.0000061761.24504.47>
3. Syan-Bhanvadia S, Daneshmand S. Management of the continent cutaneous stomal complications. *Curr Bladder Dysfunct Rep* 2012;7:294-301. <https://doi.org/10.1007/s11884-012-0159-2>

**Correspondence:** Dr. Rebecca Briskin, Henry Ford Health System, Detroit, MI, United States; [rbriskin@gmail.com](mailto:rbriskin@gmail.com)