

Case report – Primary renal echinococcal infection

Jennifer Bjazevic, MD¹; Dor Golomb, MD¹; Michael S. Silverman, MD²; Stephen E. Pautler, MD¹; Hassan Razvi, MD¹

¹Division of Urology, Department of Surgery, University of Western Ontario, London, ON, Canada; ²Division of Infections Diseases, Department of Medicine, University of Western Ontario, London, ON, Canada

Cite as: *Can Urol Assoc J* 2020;14(8):E383-6. <http://dx.doi.org/10.5489/cuaj.6394>

Published online March 23, 2020

Abstract

Renal echinococcal infection is an uncommonly encountered infection in North America but is endemic in many parts of the world. With increasing migration, it is conceivable that practicing Canadian physicians will see more patients presenting at various stages of infection. Herein, we describe an unusual presentation of primary renal echinococcal infection and describe current diagnostic, as well as medical and surgical management strategies.

Introduction

Echinococcus is a parasitic infection due to the cestode, *Echinococcus granulosus*, and is endemic in the Middle East, China, Eastern and Sub-Saharan Africa, South and Central America, New Zealand, Australia, and Alaska.¹ The dog is the definitive host, with the adult *Echinococcus* worm residing in the proximal jejunum mucosa. Sheep are the intermediate host, and humans become infected through oral ingestion of parasite eggs in contaminated water, soil, vegetables, or from direct contact with the animal hosts.² Once ingested, the embryo exits the egg, penetrates the human intestinal mucosa, and enters the blood circulation.³ Systemic dissemination through the portal venous and lymphatic systems most commonly affects the liver (75%) and lungs (15%); however, infection may affect almost any anatomical location.⁴ Primary renal echinococcal infection is rare, accounting for only 2–3% of cases.⁵

Renal involvement usually occurs in the form of hydatid cysts. Most patients with primary renal involvement remain asymptomatic.⁴ Over time, the cysts enlarge and may be associated with abdominal pain due to hydatiduria, fever, hematuria, abdominal mass, and hypertension.⁶ Hydatiduria is reported to occur in 10–20% of cases due to rupture of the cysts into the collecting system and results in the pas-

sage of whitish material in the urine.⁶ Rarely, cyst rupture can occur, resulting in anaphylaxis.⁷ Herein, we describe a rare case of primary renal echinococcal infection presenting in Canada with hydatiduria.

Case report

A 34-year-old man was referred for evaluation of an ultrasound finding of a complex right renal cyst (Fig. 1A). He had been granted refugee status and immigrated to Canada four months prior. He had emigrated from Lebanon but was born in Syria and had lived there until age 15. While living in Syria, he had worked as a shepherd. In his mid-twenties, he reported undergoing an open surgical procedure on his kidney but could not relay the reason, nor were there any medical records available. He did not recollect receiving any prolonged courses of antibiotics and denied a history of tuberculosis.

A three-phase, contrast-enhanced computed tomography (CT) scan of the abdomen was performed revealing a right thick-walled, upper pole cortical renal cyst, without enhancement, consistent with a Bosniak 2F lesion. There were no signs of any calculi, hydronephrosis or other organ findings (Fig. 1B). At followup six months later, he remained asymptomatic and an ultrasound revealed a stable cyst.

Three months later, he presented to the emergency department complaining of new onset, intermittent right flank pain. A non-contrast CT revealed new right hydronephrosis to the bladder, without any ureteric or renal calculi. He denied fever, hematuria, or seeing a stone pass, but had noted some brownish-colored debris in his urine.

Urine microscopy demonstrated pyuria, without any evidence of bacteria; and urine culture and cytology were unremarkable. Urine for acid fast bacilli and mycobacteria were negative, a tuberculosis (TB) skin test was non-reactive, and chest x-ray was normal. Complete blood count (CBC) revealed a mild eosinophilia ($0.9 \times 10^9/L$), and serum creatinine was normal.

Retrograde pyelography revealed a large, irregular-shaped filling defect in the right upper pole (Fig. 2A). Flexible nephroscopy revealed whitish amorphous-looking material

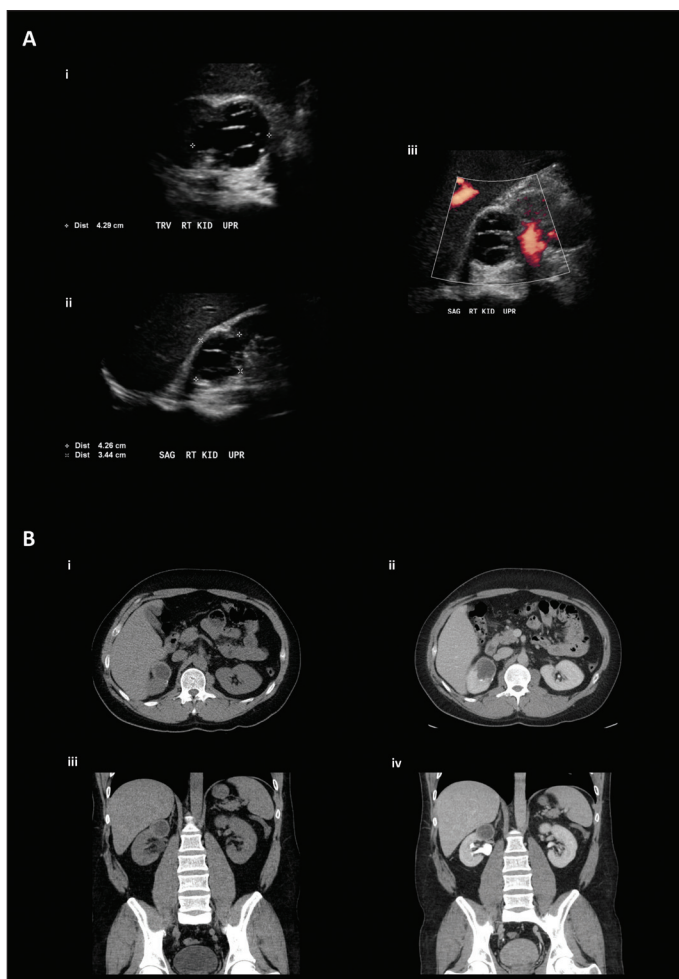


Fig. 1. (A) Ultrasound images of complex right renal cyst: **(i)** transverse view; **(ii)** sagittal view; **(iii)** sagittal view with doppler flow. **(B)** Triphasic computed tomography images of complex right renal cyst: **(i)** selected non-contrast axial image; **(ii)** selected arterial and urogram phase axial image; **(iii)** selected non-contrast coronal image; **(iv)** selected arterial and urogram phase coronal image.

adherent to the urothelium, and biopsies were taken and sent for pathology (Fig. 2B).

The pathology of the amorphous material was compatible with fragments of urothelium, with underlying mixed chronic inflammation and abundant eosinophils. No granulomas, dysplasia, or malignancy were present. The urothelial biopsy consisted of predominantly acellular eosinophilic material with a laminated appearance and thin ribbons of densely eosinophilic granular material. No organisms were identified. The pathological diagnosis was suspicious for echinococcal infection.

The patient was referred to Infectious Disease. *Echinococcal* species IgG enzyme-linked immunoassay (EIA) serology was found to be strongly reactive (IgG EIA Index: 10.19; cutoff for reactive >1.1), indicating detectable levels of echinococcal antibodies. Abdominal ultrasound demonstrated no liver involvement.

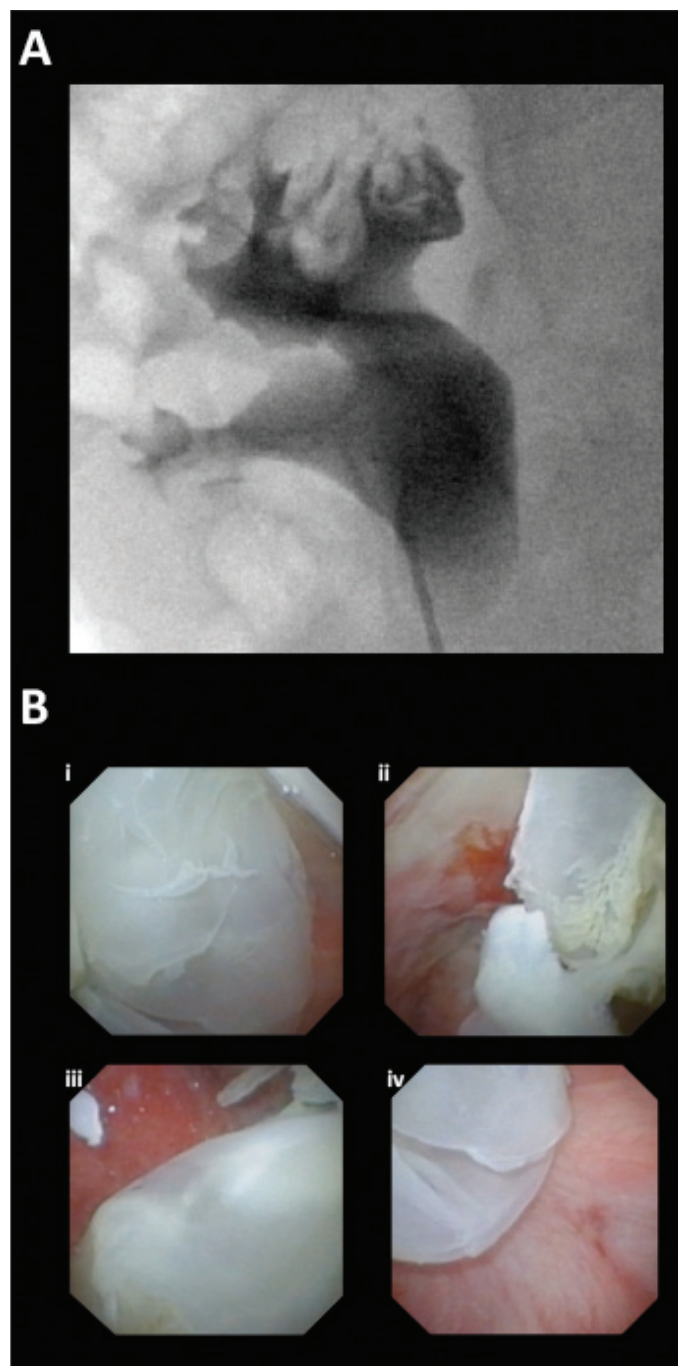


Fig. 2. (A) Retrograde pyelogram demonstrating large filling defect in the upper pole calyces. **(B)** Selected images from flexible ureteroscopy demonstrating amorphous material adherent to the mucosa within the upper pole and an erythematous appearance of the surrounding mucosa.

Surgical therapy was recommended for definitive management of his Echinococcal disease. Given his prior open surgery, with what seemed to be incomplete excision of the hydatid cyst, total nephrectomy was recommended. He was prescribed oral albendazole (400 mg twice daily) as a suppressive anthelmintic one week preoperatively. Open right nephrectomy

through a subcostal incision was performed. Care was taken to successfully avoid rupturing the cyst during the dissection.

Pathological examination of the kidney specimen revealed a cystic lesion with a thick fibrous wall, with an abundant chronic inflammatory process, composed of lymphocytes, plasma cells, occasional multinucleated giant cells, and eosinophils. Within the cyst, there was a residual inner acellular layer, with a prominent laminated appearance and an overlying eosinophilic germinal layer. No protoscolices (parasitic larvae) were seen. The features were in keeping with a treated echinococcus cyst (Fig. 3).

His postoperative course was unremarkable, and he was maintained on suppressive albendazole for an additional one month postoperatively. Followup abdominal ultrasound did not demonstrate any evidence of daughter cysts and his eosinophilia resolved. Both ultrasound and CT imaging have a high sensitivity and specificity (>90%) for detection of daughter cysts.⁸

Discussion

The diagnosis of echinococcal infection may be difficult to establish, even in areas where the condition is endemic. The clinical course may be variable, and imaging techniques may assist in the diagnosis, but are occasionally inconclusive. Eosinophilia suggests parasitic infection but is not specific. Serological testing is helpful especially for liver involvement, although may be much less sensitive where other organs are involved. Sensitivity and specificity of newer commercial Echinococcal IgG assays are reported to be as high as 95.2% and 94.3%, respectively.⁹ False-positive serology is an issue due to cross-reactivity with antigens from other helminths.¹⁰ Therefore, diagnosis remains heavily reliant on clinical suspicion.

Various treatments have been described for the treatment of renal echinococcal infection, including percutaneous intervention, open surgical excision, laparoscopic surgery, and medical treatment.¹¹ However, definitive treatment remains surgical and requires removal of the entire intact cyst in order to reduce the risk of disease recurrence and prevent anaphylaxis with cyst rupture.¹² While traditionally an open retroperitoneal approach has been recommended to avoid contamination of the peritoneal cavity, minimally invasive techniques have been described.¹² When possible a nephron-sparing approach is preferred; however, in cases where the kidney is poorly functioning, there is hydatiduria, or when partial nephrectomy is not feasible, removal of the entire kidney is the treatment of choice.¹² Puncture aspiration-injection-re-aspiration (PAIR) performed under imaging guidance in association with systemic medical therapy has been quite effective in patients with hepatic hydatid disease, but experience in renal hydatid disease has been quite limited and is generally restricted to non-operable patients.¹³

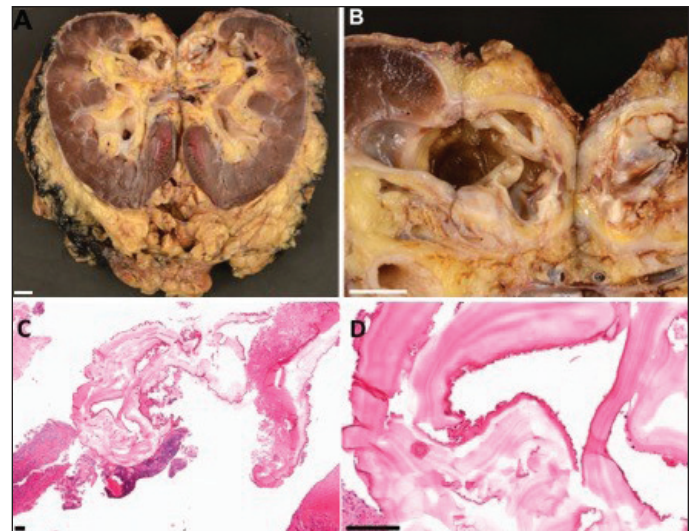


Fig. 3. (A) Pathology images from radical nephrectomy specimen; and (B) gross specimen bivalved with 1 cm scale bar. (B) Gross specimen of echinococcal cyst bivalved with 1 cm scale bar. (C) Microscopy images with hematoxylin and eosin stain under 4X magnification with 100 micron scale bar. (D) Microscopy images with hematoxylin and eosin stain under 4X magnification with 100 micron scale bar.

Medical management with anthelmintics alone has been reported to achieve poor results due to the drugs' low penetration into the cyst. These agents are also not without potentially serious adverse effects, such as hepatotoxicity, leukopenia, and allergic reactions.¹⁴ The main role for medical management is in conjunction with surgery, where the anthelmintics have been used in order to reduce the size of cysts, sterilize them, and to prevent relapses.¹⁵ Addition of praziquantel to albendazole has been recommended by some authors, but again, the evidence for this approach remains quite limited.¹⁵

Conclusions

Although a rare condition in North America, echinococcal infections are common in many other parts of the world. With population migration, it is conceivable that more patients will be seen outside endemic areas. While primary renal involvement is rare, Canadian urologists should be aware of appropriate diagnostic testing and recommended therapies.

Competing interests: Dr. Silverman has been an advisory board member for Merck (HIV); a speaker for Gilead (HIV); and has participated in clinical trials supported by Seres Therapeutics. Dr. Pautler has been a paid proctor for robotic surgery for Minogue Medical. Dr. Razvi holds a patent for a surgical device marketed by Cook Urological. The remaining authors report no competing personal or financial interests related to this work.

This paper has been peer-reviewed

References

1. Vuitton DA. The WHO informal working group on echinococcosis. The coordinating board of the WHO-IWGE. *Acta Trop* 1997;67:147-8. [https://doi.org/10.1016/S0001-706X\(97\)00059-4](https://doi.org/10.1016/S0001-706X(97)00059-4)
2. Fazeli F, Narouie B, Firoozabadi MD, et al. Isolated hydatid cyst of kidney. *Urology* 2009;73:999-1001. <https://doi.org/10.1016/j.urolgy.2008.10.049>
3. Sayilir K, Iskender G, O an C, et al. A case of isolated renal hydatid disease. *Int J Infect Dis* 2009;13:110-2. <https://doi.org/10.1016/j.ijid.2007.12.016>
4. Bandyopadhyay A, Khatua S, Das S, et al. A rare case of primary renal hydatid cyst presenting with hydatiduria. *J Parasit Dis* 2015;39:577-80. <https://doi.org/10.1007/s12639-013-0362-x>
5. Kumar SA, Shetty A, Vijaya C, et al. Isolated primary renal echinococcosis: A rare entity. *Int Urol Nephrol* 2013;45:613-6. <https://doi.org/10.1007/s11255-013-0402-6>
6. Kundu A, Mongha R, Narayan S. Primary hydatid cyst of kidney and ureter with gross hydatiduria: A case report and evaluation of radiological features. *Indian J Urol* 2008;24:116. <https://doi.org/10.4103/0970-1591.38617>
7. Neumayr A, Troia G, de Bernardis C, et al. Justified concern or exaggerated fear: The risk of anaphylaxis in percutaneous treatment of cystic echinococcosis: A systematic literature review. *PLoS Negl Trop Dis* 2011;5:e1154. <https://doi.org/10.1371/journal.pntd.0001154>
8. Mehta P, Prakash M, Khandelwal N. Radiological manifestations of hydatid disease and its complications. *Trop Parasitol* 2016;6:103-12. <https://doi.org/10.4103/2229-5070.190812>
9. Public Health Ontario. Parasitic serology update – Test methodology change 2017. Available at: <https://www.publichealthontario.ca/-/media/documents/lab/lab-sd-117-parasitic-serology-test-method-change.pdf?la=en>. Accessed Nov. 27, 2019.
10. Fathi S, Jalousian F, Hosseini S, et al. A study of cross-reactivity between recombinant EPC1 antigen of *Echinococcus granulosus* in serum from patients with confirmed cystic echinococcosis infection and other parasitic infections. *Am J Trop Med Hyg* 2016;94:1313-7. <https://doi.org/10.4269/ajtmh.15-0680>
11. Aggarwal S, Bansal A. Laparoscopic management of renal hydatid cyst. *JSL S J Soc Laparoendosc Surg* 2019;18:361-6. <https://doi.org/10.4293/108680813X13753907291396>
12. Paramythiotis D, Bangeas P, Kofina K, et al. Presence of an isolated hydatid cyst in the left kidney: Report of a case of this rare condition managed surgically. *Case Rep Urol* 2016; 2016:6902082. <https://doi.org/10.1155/2016/6902082>
13. Rexiati M, Mutalifu A, Azhati B, et al. Diagnosis and surgical treatment of renal hydatid disease: A retrospective analysis of 30 cases. *PLoS One* 2014;9:e96602. <https://doi.org/10.1371/journal.pone.0096602>
14. Von Sinner WN, Hellström M, Kagevi I, et al. Hydatid disease of the urinary tract. *J Urol* 1993;149:577-80. [https://doi.org/10.1016/S0022-5347\(17\)36153-0](https://doi.org/10.1016/S0022-5347(17)36153-0)
15. Velasco-Tirado V, Alonso-Sardón M, Lopez-Bernus A, et al. Medical treatment of cystic echinococcosis: Systematic review and meta-analysis. *BMC Infect Dis* 2018;18:306. <https://doi.org/10.1186/s12879-018-3201-y>

Correspondence: Dr. Hassan Razvi, Division of Urology, Department of Surgery, University of Western Ontario, London, ON, Canada; hrazvi@uwo.ca