

Case – Confirmed testicular mass on ultrasound with no evidence on histology: Report of two cases in teenagers

Sarah Emilie Lebel; Stéphane Bolduc; Katherine Moore
Division of Urology, CHU de Québec, Université Laval, Quebec City, QC, Canada

Cite as: *Can Urol Assoc J* 2019 September 27; Epub ahead of print.
<http://dx.doi.org/10.5489/cuaj.6083>

Published online September 27, 2019

Introduction

The estimated incidence of testicular masses in pediatrics is 0.5–2 in every 100 000 children.¹ The first peak of incidence is found around two years of age, and a second peak occurs around puberty.¹ Patients generally present with painless palpable mass, but it may also be an incidental finding on scrotal ultrasound performed for another testicular complain, most commonly pain.² Among the possible diagnoses of intratesticular mass, benign teratoma is the most frequently encountered in pediatrics prior to puberty.¹ Despite abundant literature on this subject, we present, to our knowledge, the first two cases of peripubertal testicular masses demonstrated on ultrasound whose tumor markers, surgical exploration, and histological analyses showed no significant abnormality. Ultrasonographic followups showed no recurrence for more than two years after surgical exploration.

Case reports**Case 1**

A healthy 11 year-old Caucasian boy initially presented at his community hospital, after minor scrotal trauma, for left testicular pain with oedema and palpable mass. Ultrasound showed a hyperechoic left intratesticular mass (10 x 4.4 mm) with no vascular flow. A second ultrasound performed at our pediatric center 1 month later confirmed the persistence of the non-vascularized hyperechoic homogeneous nodular image (9 mm x 6 mm) (Figure 1). On physical exam, both testicles were symmetrical, with no persistent oedema or palpable mass in this Tanner 1 boy. Preoperative alpha-fetoprotein (AFP) and human chorionic gonadotropin (hCG) were negative, and lactate dehydrogenases (LDH) were slightly above normal at 204 (normal <200). During surgical exploration, an inguinal partial orchiectomy was performed 2 days after the ultrasound, but no mass was palpated or visualized. An intraoperative testicular ultrasound did not show the

previously described hyperechoic lesion and the right testis remained within the normal range. We performed several large testicular biopsies and they revealed normal testicular parenchyma without significant lesion. Two control ultrasounds, at 6 and 18 months postop, showed no pathology other than the changes associated with surgical exploration. Four years out of his scrotal exploration, the patient has not been seen back in urology.

Case 2

A healthy 13-year-old Caucasian man, with no relevant history, presented for acute left testicular pain without other symptoms. No mass was palpated. On ultrasound, homogeneous and hyperechoic intratesticular mass with well-defined contours of 6.8 x 5.6 x 4.2 mm was visualized in the left testicle, with few microlithiasis and signs of epididymitis. One month later, the ultrasound was repeated and the mass had slightly decreased on size (3,4 x 5,6 x 6) with no vascular flow. At referral, 2 months after his initial presentation, a third ultrasound was performed and still demonstrated the presence of the stable left testicular mass in this Tanner 1 teenager (Figure 2). AFP and hCG were negative and LDHs were slightly elevated at 207 (normal <200). An ultrasound-guided inguinal partial orchiectomy was performed 1 month after the latest ultrasound. However, the appearance of the 2 testicles appeared quite normal on palpation and ultrasound. As for the first case, the fresh frozen sections analysis showed no abnormality and the definitive histological aspect of the several large random biopsies was negative for malignancy. Ultrasonographic follow-ups were regularly performed and were still normal at 2 years post exploration. We can extrapolate that 2,5 years later the patient has not had testicular problem as he was not referred back to our center, the closest (300 km) pediatric urological center and no further scrotal ultrasound was seen on the provincial imaging database.

Discussion

As in adults, the assessment of pediatric testicular masses is mainly based on the clinic, tumor markers and Doppler ultrasound, the imaging study of choice². However, ultrasound solely cannot exclude malignant tumor but can be used to guide surgical exploration of nonpalpable testicular mass.³ In the peripubertal period, physiological changes are observed on testicular echogenicity, mainly related to the increasing in size of seminiferous tubules. At age 9, there is gradual increase in testicular echogenicity on ultrasound, which is more marked between 12 and 15 years of age. According to the available literature, however, these changes on imaging studies occur homogeneously throughout the testis, regardless of the stage of maturation⁴. A recent Brazilian study by Camela *et al.*, conducted with Dorper rams, demonstrated significant difference in testicular heterogeneity during puberty, which was more pronounced in the peripubertal than in the postpubertal period⁵. By extrapolation, this study supports our main hypothesis regarding the two previously reported cases, namely that the hyperechoic masses discovered on ultrasound could represent a normal but inhomogeneous maturation of the testis.

Despite the fact that the majority of pediatric testicular tumors are hypoechoic, they can also be hyperechoic or mixed². Although less likely, several cases of germinal tumors with spontaneous regression (burned-out) have been reported in the literature⁶⁻⁸. To our knowledge, no pediatric cases of this phenomenon have been described and all patients had retroperitoneal metastases and / or positive tumor markers, both absent for our two patients. On ultrasound, these tumors usually appear as hypoechoic or heterogeneous mass, and all burned-out testicular tumors have a well-circumscribed fibrous scar with generalized testicular atrophy⁶. These findings have not been demonstrated in the two paediatric cases that we are reporting. Therefore, we did not retain this hypothesis as the interval between imaging and surgery was short. Frequent tumors of the prepubertal period (teratoma, Yolk sac tumor, and stromal tumors) were part of the differential diagnosis, but they do not tend to regress spontaneously^{6,7}.

Active surveillance can be considered for small testicular lesions, especially in the prepubertal population with negative markers, benign masses being more frequent. This practice seems to have also been adopted in the adult population for small masses incidentally found during infertility screening.⁹ If surgical exploration is considered, we reiterate that it remains essential to opt for a conservative approach for small intratesticular masses, namely the inguinal partial orchiectomy in the pediatric and peripubertal population.

Conclusions

We present the first two cases of intratesticular masses seen on several ultrasounds in peripubertal males, in whom paraclinical assessment, surgical exploration, histopathological analysis as well as ultrasound follow-up were all negative. Knowing that most pediatric testicular lesions with negative markers are benign, active surveillance should be discussed as a legitimate option. Given the significant consequences of total orchiectomy for an ultimately histologically normal testis, we conclude that a partial approach should be prioritized in pre-puberty, but also during the peripubertal period if surgical management is chosen.

References

1. Chapter 156: Pediatric Urologic Oncology In: Alan J. Wein, Louis R. Kavoussi, Alan W. Partin, Craig A. Peters, *Campbell-Walsh Urology* 11th ed. Elsevier 2016:3590-96
2. Hamm B. Differential diagnosis of scrotal masses by ultrasound. *European radiology* 1997;7:668-79.
3. Philips S, Nagar A, Dighe M, et al. Benign non-cystic scrotal tumors and pseudotumors. *Acta radiologica* 2012;53:102-11.
4. Hamm B, Fobbe F. Maturation of the testis: ultrasound evaluation. *Ultrasound in medicine & biology* 1995;21:143-7.
5. Camela ESC, Nociti RP, Santos VJC, et al. Changes in testicular size, echotexture, and arterial blood flow associated with the attainment of puberty in Dorper rams raised in a subtropical climate. *Reproduction in domestic animals = Zuchthygiene* 2018.
6. Balzer BL, Ulbright TM. Spontaneous regression of testicular germ cell tumors: an analysis of 42 cases. *The American journal of surgical pathology* 2006;30:858-65.
7. Ulbright TM. Germ cell tumors of the gonads: a selective review emphasizing problems in differential diagnosis, newly appreciated, and controversial issues. *Modern pathology : an official journal of the United States and Canadian Academy of Pathology* 2005;18 Suppl 2:S61-79.
8. Bissen L, Brasseur P, Sukkarieh F. [Spontaneous regression of testicular tumor]. *JBR-BTR : organe de la Societe royale belge de radiologie* 2003;86:319-21.
9. Bieniek JM, Juvet T, Margolis M, et al. Prevalence and Management of Incidental Small Testicular Masses Discovered on Ultrasonographic Evaluation of Male Infertility. *The Journal of urology* 2018;199:481-6.

Figures and Tables

Fig. 1. Patient 1: Preoperative testicular ultrasound.

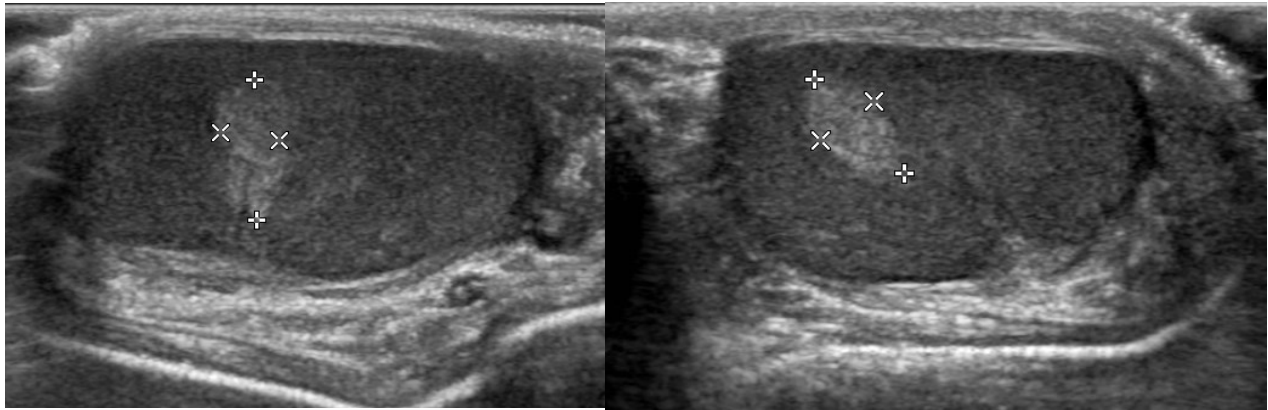


Fig. 2. Patient 2: Preoperative testicular ultrasound.

