

The futility of continued surveillance of epididymal cysts: A study of the prevalence and clinico-demographics in pre- vs. post-pubertal boys

Fardod O'Kelly, MD^{1,2}; Kristen McAlpine, MD^{1,2}; Nishard Abdeen, MD^{2,3}; Melise A. Keays, MD^{1,2}; Luis A. Guerra, MD^{1,2}; Michael P. Leonard, MD^{1,2}

¹Division of Pediatric Urology, Children's Hospital of Eastern Ontario, Ottawa, ON, Canada; ²University of Ottawa, Ottawa, ON, Canada; ³Department of Medical Imaging, Children's Hospital of Eastern Ontario, Ottawa, ON, Canada

Cite as: *Can Urol Assoc J* 2019;13(12):E398-403. <http://dx.doi.org/10.5489/cuaj.5667>

Published online April 26, 2019

Abstract

Introduction: The first description of epididymal cysts in children appears from a 1976 case study. Since then, there have been a total of 24 indexed publications relating to pediatric epididymal cysts. Risk factors that may exist for children presenting with epididymal cyst remain unknown, as has the best method of management. And there have not been any studies looking at the cost implications of this diagnosis. The aim of this study was to assess the incidence, clinico-demographics, outcomes, and costs of epididymal cysts in pre-pubertal boys compared with a post-pubertal epididymal cyst cohort, and to assess whether this cohort requires continued surveillance.

Methods: Our institutional ultrasound (US) database was searched for all scrotal US. From these, a filtered, institution review board-approved search was performed for any reports containing the word "cyst." These were then cross-referenced with a retrospective chart review (October 2006 to September 2017). Clinico-demographics, cyst characteristics, and outcomes were analyzed for both pre- and post-pubertal boys using descriptive and non-parametric statistical methods.

Results: Of 4508 boys undergoing scrotal US during the study period, 191 were indicated to contain cysts. This was manually reduced to 109 scans (2.4%) that met inclusion criteria (85 pre-pubertal; 24 post-pubertal). Thirty-one scans were ordered by urology, including all those with abnormal testicular echotexture (n=5). The average age of the post-pubertal cohort was 15.8 years, compared with 3.8 years in the pre-pubertal cohort. Most (70.5%) epididymal cysts were incidental. There was no difference between the pre- and post-pubertal cohorts in terms of presence of hydroceles (p=0.9), symptoms (p=0.9), ordering service (p=0.61), rate of resolution (4.2% vs. 8.2%; p=0.68), or length of followup (4 vs. 4.5 years; p=0.44). Pre-pubertal cysts were significantly smaller in size (3.35 vs. 14.52 mm; p=0.025) and more likely to trigger repeat scanning (67 vs. 10; p=0.008). There were no operative interventions and no subsequent clinical deterioration occurred with observation. At a cost of \$71.10 CAD per US, \$15 002.10 CAD was expended on epididymal cyst surveillance in direct cost to the healthcare system.

Conclusions: Epididymal cysts are comparable in both pre- and post-pubertal boys and can be safely managed non-operatively without the use of continued US surveillance or urological referral. The higher than expected rate of detection may be a result of the improved ultra-resolution of modern scanners. These children should not require continued followup with repeat surveillance imaging solely for epididymal cysts and could be managed in the primary care setting as part of routine clinical examination.

Introduction

The term epididymal cyst was initially described by Guerin in 1785 in an adult with an inflammatory process of the testicle, which in no way bears any resemblance to the modern-day definition. In 1840, Liston described an entity of an encysted structure near the epididymis that appeared to contain spermatozoa and seminal fluid, and usually formed as a result of testicular trauma. In children, the first appearance of epididymal cysts appears from a study by Bissada et al in 1976, who described a case series of unusual scrotal findings. It is not possible to distinguish epididymal cysts from spermatoceles clinically or sonographically.¹ The distinction is made based on analysis of the cyst contents. If it contains seminal fluid/spermatozoa, then it is termed a spermatocele, which is generally reserved for post-pubertal males. However, the two descriptive terms have been used interchangeably, and sometimes incorrectly, over the last 40 years.

Epididymal cysts usually present as a painless, scrotal swelling in adolescents as a result of dilatation of the efferent epididymal tubules from prior injury or inflammation. Sonographically, they are seen as thin-walled, septated cysts within the epididymal head with dependent echoes.² They can occur at any age and can be found anywhere along the epididymis. They are also thought to regress in children.^{3,4} There have been a total of 24 publications relating to epididymal cysts in children since 1976 that appear on Pubmed/Medline, and that meet the inclusion criteria of childhood (0–18 years) and articles pertaining to humans. Of these, seven have been case reports. Within these publica-

tions, there have been an average of 32 patients per study (median $n=1$).

The first paper to describe the natural history of epididymal cysts in children was by Homayoon et al in 2004, with a 50% resolution across 20 children with an average age of 10.5 years and in whom 75% presented with a non-painful testicular mass.⁵ Posey et al described the incidence of epididymal cysts at their institution and found a incidence of 14.4% across 1765 patients who underwent scrotal ultrasound (US), whereas Niedzielski et al demonstrated an even higher incidence of 16.2% across 363 patients, and suggested that those under 10 mm could be managed conservatively.^{6,7} Shah et al suggested that in those 57 children who had an epididymal cyst excision in their cohort, there was no clinical or economic benefit in the pathological analysis.⁸

Although, it is thought that epididymal cysts may demonstrate some regression in children, it remains unknown as to any risk factors relating to development that may exist for children presenting with epididymal cysts, their natural history, and the best method with which to manage them, nor have there been any studies looking at the cost implications of this diagnosis. In Ontario, each US performed for a suspected epididymal cyst costs the provincial health insurance plan \$71.10 CAD.⁹ In addition, on top of the direct cost of each US are the costs incurred by patients' families when parents must take time off work, travel, and pay for parking for the US appointment. There is also an incalculable emotional cost, as parents and children suffer anxiety when medical tests are performed, and an inaccurate result may cause additional undue worry.^{10,11}

The hypothesis of this study is that epididymal cysts are a benign scrotal finding in both pre- and post-pubertal boys, which should not automatically mandate treatment or surveillance. There is very limited data available relating to followup in this cohort, with a recent study advocating continued surveillance;^{12,13} however, this is costly and time-consuming, with a greater longitudinal burden to the health service in pre-pubertal children, as they would require longer periods of followup and theoretically more scans than if they presented at an older age. The aim of this study was to assess the incidence, clinico-demographics, outcomes, and basic costs of epididymal cysts in pre-pubertal boys compared with a post-pubertal epididymal cyst cohort, and to assess whether continued surveillance in this cohort is beneficial.

Methods

We retrospectively analyzed all pediatric scrotal US reports at our institution between January 1, 2010 and October 31, 2016 inclusively, in order to unearth a cohort of those diagnosed with epididymal cysts.

Variables including age at presentation, comorbidities, known family history of benign scrotal disease, Tanner

pubertal stage, length of followup, presence of other scrotal pathology (such as testicular torsion/testicular cysts/testicular, or epididymal appendages/varicoceles to determine whether continued surveillance would be justified), frequency of repeat scanning, clinical outcome, and reason for presentation were captured. The ordering department was also included in order to capture those scans that were not under the control of pediatric urology. In addition to physical examination, diagnosis of epididymal cysts was confirmed by US and/or Doppler US by observing an echo-free cystic structure on the epididymis. Sonographic analysis included cyst diameter and all testicular dimensions (length, width, and transverse diameter) in those with epididymal cysts, as well as those with normal contralateral testicles, and therefore, covariance analysis to adjust for age was not required.

Descriptive analysis by means of tables and graphs for patients' baseline characteristics were performed. Continuous variables were analyzed using t-test and categorical variables were compared using Chi-square or Fisher's tests. A p value equal or less than 0.05 was considered significant. We also calculated the total cost of followup US for patients diagnosed with epididymal cysts based on the current Ontario Health Insurance Plan fee schedule.

Results

Of 4508 boys undergoing scrotal US during the study period, 191 were indicated to contain cysts. These were individually assessed by two authors (FK/KM) and reduced to 109 unique patients (2.4%) who met inclusion criteria (85 pre-pubertal; 24 post-pubertal) after those patients with a history of testicular tumors, cystic dysplasia of the testis, or cystic fibrosis and an alternative specific need to continue surveillance were excluded. All of these patients were seen in the urology clinic, including those who were not initially seen by urology for other diagnoses, as the US reports had suggested the need for further clinical correlation. Thirty-one scans were ordered by urology, including for all those who were suspected to have an epididymal cyst on physical examination ($n=6$). The average age of the post-pubertal cohort was 15.8 years compared with 3.8 years in the pre-pubertal cohort (Table 1). Most (70.5%) epididymal cysts were incidental, while 29.5% were identified on physical examination and confirmed by US. There was a bimodal distribution of the prevalence of epididymal cysts in this cohort, with 47% of cysts being detected under the age of two years old; this then decreased to just under 14% from the ages of 2–10 years old, with an increase peri- and post-pubertally to 22% ($p=0.0001$) (Fig. 1). Forty-five percent of epididymal cysts were measured at 2 mm or less in size. Given the difference in mean cyst size, there was a significant difference in correctly identifying cysts through palpation in the pubertal vs. the pre-pubertal group ($p=0.025$).

Table 1. Characteristics of epididymal cysts in pre-pubertal vs. pubertal patients

Characteristic	Prepubertal EC cohort	Pubertal EC cohort	p
Number of EC patients	85	24	0.42
Mean age \pm SEM (years)	3.8 \pm 0.53	15.8 \pm 0.2	<0.0001
EC unilateral vs. bilateral, n (%)	8 (9.4); 78 (90.6)	8 (33); 16 (67)	0.012
EC right vs. left, n (%)	49 (57.6); 36 (42.4)	13 (54.2); 11 (45.8)	0.85
Single vs. multiple cysts, n (%)	76 (89.4); 9 (10.6)	18 (75); 6 (25)	0.02
Mean cyst size \pm SEM (mm)	3.35 \pm 0.2	14.52 \pm 2.3	0.025
Annual rate of resolution (%)	4.2	8.2	0.68
Followup surveillance US ordered by urology (%)	27	33	0.61

EC: epididymal cysts; SEM: standard error of the mean; US: ultrasound.

There was no difference between the pre- and post-pubertal cohorts in terms of presence of hydrocele ($p=0.9$), symptoms ($p=0.9$), ordering service ($p=0.61$), annual rate of resolution (4.2% vs. 8.2%; $p=0.68$), or length of followup (4 vs. 4.5 years; $p=0.44$). Overall, six cysts completely involuted in the post-pubertal (25%) group compared with 38 in the pre-pubertal group (45%) ($p=0.1$). Pre-pubertal cysts were significantly smaller in size (mean 3.35 vs. 14.52 mm; range 1–27; $p=0.025$) and more likely to trigger repeat scanning, with a mean of three followup scans per patient in the pre-pubertal group vs. one followup scan in the post-pubertal group ($n=67$ vs. $n=10$; $p=0.008$). Post-pubertal cysts were significantly more likely to be bilateral compared with the pre-pubertal cohort (33% vs. 9.4%; $p=0.012$). Surveillance US was ordered by urology in 16.2% ($n=17$) and non-urological physicians in 83.8% ($n=88$).

In patients with epididymal cysts, the most common reason for referral and scanning was for a scrotal swelling (35.7%), followed by investigations for a contralateral undescended testicle (20.1%). Only six (5.5%) US were performed for pain (torsion excluded), two cases in which the

cyst was reported on the contralateral side. During the time period of the study, six patients were referred for the specific reason of confirming an epididymal cyst, all of whom were seen by urology (Table 2). There were no operative interventions and no subsequent clinical deterioration occurred with observation, with no further findings requiring treatment. When comparing testicular volumes by age, there were no differences in volume in those with or without unilateral epididymal cysts. There were significantly higher testicular volumes in those with bilateral epididymal cysts compared to those with unilateral, or normal controls; however, when age-adjusted, these differences were no longer significant (Table 3). At a cost of \$71.10 CAD per US, \$15 002.10 CAD was expended on epididymal cyst surveillance in direct costs to the healthcare system.

Discussion

The etiology of epididymal cysts in childhood is unclear. They may arise congenitally as a result of an aberrant hormonal interplay during embryonic development and are almost certainly under-reported in the literature.¹⁴ The differential diagnosis of cystic extra-testicular masses in this cohort include varicocele, adenomatoid tumor of the epididymis, paratesticular abscess, and epididymal cystic lymphangioma. Therefore, ultrasonography should be considered part of the diagnostic armamentarium, in addition to careful physical examination, where there are concerns for solid or growing masses, as there have been reports where indirect inguinal hernia have been sonographically reported as epididymal cysts.^{12,15} There are a number of theories put forward towards pathogenesis, including the role of hormone dysregulators such as diethylstilbestrol, and epididymal duct stenosis with post-stenotic dilatation.¹⁶

Cyst size (1–27 mm) and laterality in this study are equivalent to those reported in the literature. The majority of cysts diagnosed measure 3–30 mm and there has been no predominance in laterality described.^{5,17} The main difference in presentation between this and other studies is the initial peak of the biphasic diagnostic curve picked up in the infant cohort (<2 years old). We postulate that, as this is not linked to an increase in undescended testis in this cohort, it may be a result of both an increase in sonographic screening in this age group, as well as a technological advancement in ultrasonographic software packages and multiplanar sonographic probes. Statistical differences in cyst size between pre-pubertal and pubertal groups (3.35 vs. 14.52 mm) are not unexpected and relate to the volume of the testis (2.59 vs. 14.81 mL). This is corroborated by other studies in the literature, which have demonstrated an increase in cyst size with age and a tendency towards bilaterality in older patients.^{13,18} As such, the differences seen in this cohort between unilateral and bilateral cysts disappear when age-adjustment is con-

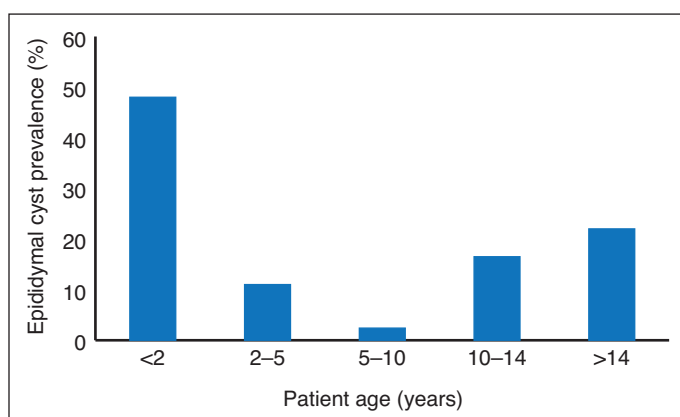
**Fig. 1.** Prevalence of epididymal cysts characterized by age groupings.

Table 2. Reasons for ultrasonography in patients seen by urology with possible epididymal cysts

Reason for ultrasonography	Total	Urology (%)	Non-urology hospital physician (%)	Primary care (%)
Testicular swelling/hydrocele	39	5 (12.8)	14 (35.9)	20 (51.3)
Epididymal cyst	6	6 (100)	0 (0)	0 (0)
Varicocele	10	4 (40)	2 (20)	4 (40)
Undescended testis	22	5 (22.7)	2 (9.1)	15 (68.2)
Inguinal hernia	6	0 (0)	0 (0)	6 (100)
Testicular atrophy	1	0 (0)	1 (100)	0 (0)
Blunt scrotal trauma	2	0 (0)	2 (100)	0 (0)
Painless testicular mass	11	0 (0)	2 (18.2)	9 (81.8)
TART screen	3	0 (0)	0 (0)	3 (100)
Testicular microlithiasis followup	2	2 (100)	0 (0)	0 (0)
Complex renal cyst followup	1	1 (100)	0 (0)	0 (0)
Testicular pain	5	1 (20)	4 (80)	0 (0)
Hyperbilirubinemia	1	0 (0)	1 (100)	0 (0)

TART: testicular adrenal rest tumor.

sidered. This study does not, however, corroborate findings by Posey et al, in which authors demonstrated an increase in testicular size and volume in boys with epididymal cysts on US irrespective of age or laterality, and also demonstrated up to 35% boys still harboring epididymal cysts by the age of 15 years, which they postulated to be a result of maternal endocrine disruptors.⁶ Their study, however, failed to verify the accuracy of their ultrasonography, or provide data on epididymal cyst size and number. There may be confounders between the two sets of data, thus reiterating the need for prospective research.

The mode of referral and etiology for performing US in this cohort demonstrate that the most common reasons for undertaking this modality are a painless scrotal swelling and a possible undescended testis (on the contralateral side). Twenty-three percent of the total number of US were ordered by urology, of which 24% were specifically to confirm the presence of epididymal cysts. These data confirm what is already known in the literature: that the majority of epididymal cysts are incidental and painless. Patients presenting with testicular pain in this cohort were managed in accordance with best practice guidelines on testicular pain, with the primary aim being to rule out torsion, which none of the patients in this cohort had. There have been a small number of reports in the literature on torsion of an epididymal cyst causing pain and swelling, however, this was not evident in this study.¹⁹⁻²¹

Arguably, one of the main controversies that surrounds the diagnosis of epididymal cysts is whether to manage them conservatively or to intervene with surgery or sclerosant injection (this is an uncommon option in contemporary management due to increased levels of pain and/or fibrosis). Furthermore, if opting to manage this cohort conservatively, what is the optimal period of observation? There is no current consensus on this.

One of the first papers on the precise operative management of epididymal cysts was by Lord in 1970, who described an elegant means in which to remove the cyst without injuring the underlying epididymis. There were, however, no reported outcome measures or - to long-term followup of these patients, and the procedure was performed in an older age group.²² Niedzielski et al suggested conservative management for patient in whom the epididymal

Table 3. Effect of epididymal cysts on testicular volumes

Age	Testicular volume mean ± SEM volume (cm ³)	p; F-value
0–2 years		
Control	0.72±0.04	
Unilateral EC	0.76±0.05	
Bilateral EC	0.77±0.08	0.73; 0.32
2–10 years		
Control	0.86±0.15	
Unilateral EC	0.87±0.08	
Bilateral EC	NA	0.95
10–14 years		
Control	9.33±2.42	
Unilateral EC	9.9±2.7	
Bilateral EC	9.47±1.62	0.98; 0.02
>14 years		
Control	16.24±1.19	
Unilateral EC	14.78±1.32	
Bilateral EC	13.76±1.76	0.44; 0.84
Pre-pubertal	2.59±0.4	
Post-pubertal	14.81±0.79	p<0.0001
Unilateral EC vs. control	4.46±0.74; 4.58±0.745	p=0.91
Bilateral EC vs. control	9.01±1.2; 4.58±0.75	p=0.0016
Unilateral vs. bilateral EC	4.46±0.74; 9.01±1.2	p=0.0011

Values are presented as mean ± standard error of the mean volume (cm³). EC: epididymal cysts.

cyst was less than 10 mm.⁷ Menon et al described that 32% patients in their cohort undergoing benign scrotal surgery experienced a complication, with a 4% readmission rate, and that operative intervention should be judiciously offered to patients.²³ These results echoed a previous publication by Heindorff et al who described a similar complication rate; however, not many of this cohort had a preoperative US.²⁴ In an effort to reduce the potential morbidity associated with surgery, sclerotherapy (ethanolamine oleate) was introduced as a means to eradicate the epididymal cyst in adults; however, 32% of patients required more than one injection and there was a 7% long-term failure rate, with more than half of patients experiencing pain after the procedure.^{25,26} This is not well-described in the pediatric/young adult literature and, therefore, we would not recommend it as a treatment option for this cohort. Further studies in post-pubertal patients undergoing operative epididymal cyst/spermatocele excisions demonstrated complication rates of 19–27%, treatment failure of 9.3%, and a prevalence of post-operative de novo chronic pain of 0.2–0.6%, which in a pre-pubertal patient could have drastic consequences for future sexual identity and function.^{27,28}

For those patients who are managed conservatively, there is currently no consensus on the optimal interval of scanning and length of followup. In this cohort, there was a mean of three followup scans in the pre-pubertal group vs. one followup scan in the post-pubertal group, with a concurrent resolution rate of 45% vs. 25%, respectively. No cysts increased in size and all of these patients were managed conservatively. If these patients were discharged following initial ultrasonography with education and advice given to parents, a total of 211 US slots could have been freed up for use elsewhere in the system. A followup US study for epididymal cysts for patients kept under surveillance at our institution, and which is generally current practice for this cohort, cost the Ontario provincial health insurance plan \$15 002.10 CAD during the time period of this study (not including the initial US). This may not be an optimal use of healthcare resources. Furthermore, this figure does not include the cost of a hospital clinic visit nor the expenses incurred by patients who attended for subsequent scans ordered by urology (16.2%), which was outside the scope of this study. These costs have not been previously demonstrated in the epididymal cyst literature and suggest a quality improvement argument to managing this condition conservatively. The only other study examining costs in relation to epididymal cysts was performed by Shah et al, who calculated potential savings of \$49 450 across a 14-year period of routinely sending hydrocele and spermatocele specimens for histopathological analysis and demonstrating no malignancies, with no identifiable benefit from 159 specimens.⁸ The routine referral of these patients to a urology service following the sonographic demonstration of epididymal cysts solely

for clinical evaluation is not necessary, nor do we feel there is any role for routine continued sonographic surveillance in childhood. Patients and parents should seek medical advice if the cyst increases substantially in size, becomes painful or hard, or if they notice a lump in the testis or hematuria.

There are a number of limitations to this study. The lack of a true normal control may be considered a limiting factor, as well as the retrospective design and relatively short median followup of less than five years in the pre-pubertal cohort, although it is likely that in the absence of symptoms, with time, these cysts may also regress and involute. Despite this, given the expected baseline incidence of 1.8%, the sample size required to power this cohort correctly and provide a beta value of 0.2 is 4026, which is lower than the sample size of our study. Further prospective studies with larger numbers and longer followup may provide more longitudinal information as to the natural history of these patients, and perhaps inviting these patients back for a further control US after an interval of a number of years may help elucidate this. There is some evidence that epididymal cysts, especially those in conjunction with undescended testes may play a role in testicular dysgenesis syndrome, in which male genitourinary anatomy and function are disrupted; however, the long-term effects of this are currently unknown.²⁹

Conclusions

This is the largest cohort of pediatric epididymal cysts to date. Epididymal cysts are comparable in both pre- and post-pubertal boys and can be safely managed non-operatively without the use of continued US surveillance or urological referral. The higher-than-expected rate of detection in the pre-toddler group may be as a result of the improved ultra-resolution of modern scanners. These children should not require continued followup with repeat surveillance imaging solely for epididymal cysts; given that there is no change in management or clinical course necessary, this cohort can be managed in the primary care setting as part of routine clinical examination

Competing interests: The authors report no competing personal or financial interests related to this work.

This paper has been peer-reviewed.

References

1. Bissada NK, Redman JF. Unusual masses in the spermatic cord: Report of six cases and review of the literature. *South Med J* 1976;69:1410-2. <https://doi.org/10.1097/00007611-197611000-00006>
2. Clarke BG, Bamford SB, Gherardi GJ. Spermatocele: Pathologic and surgical anatomy. *Arch Surg* 1963;86:351-5. <https://doi.org/10.1001/archsurg.1963.01310090001001>
3. Whitaker RH. Benign testicular swellings. *Practitioner* 1982;226:1851-9.

4. Finkelstein MS, Rosenberg HK, Snyder HM 3rd, et al. Ultrasound evaluation of scrotum in pediatrics. *Urology* 1986;27:1-9. [https://doi.org/10.1016/0090-4295\(86\)90196-2](https://doi.org/10.1016/0090-4295(86)90196-2)
5. Homayoon K, Suhre CD, Steinhardt GF. Epididymal cysts in children: Natural history. *J Urol* 2004;171:1274-6. <https://doi.org/10.1097/01.ju.0000110322.87053.99>
6. Posey ZQ, Ahn HJ, Junewick J, et al. Rate and associations of epididymal cysts on pediatric scrotal ultrasound. *J Urol* 2010;184:1739-42. <https://doi.org/10.1016/j.juro.2010.03.118>
7. Niedzielski J, Miodek M, Krakós M. Epididymal cysts in childhood – conservative or surgical approach? *Pol Przegl Chir* 2012;84:406-10. <https://doi.org/10.2478/v10035-012-0068-2>
8. Shah VS, Nepple KG, Lee DK. Routine pathology evaluation of hydrocele and spermatocele specimens is associated with significant costs and no identifiable benefit. *J Urol* 2014;192:1179-82. <https://doi.org/10.1016/j.juro.2014.04.085>
9. Ministry of Health and Long-Term Care. Schedule of benefits for physician services under the Health Insurance Act. Toronto: Government of Ontario, 2015.
10. Sorenson JR, Levy HL, Mangione TW, et al. Parental response to repeat testing of infants with 'false-positive' results in a newborn screening program. *Pediatrics* 1984;73:183-7.
11. Racine NM, Riddell RR, Khan M, et al. Systematic review: Predisposing, precipitating, perpetuating, and present factors predicting anticipatory distress to painful medical procedures in children. *J Pediatr Psychol* 2016;41:159-81. <https://doi.org/10.1093/jpepsy/jsv076>
12. Karaman A, Afşarlar CE, Arda N. Epididymal cyst: Not always a benign condition. *Int J Urol* 2013;20:457-8. <https://doi.org/10.1111/j.1442-2042.2012.03152.x>
13. Erikci V, Hoşgör M, Aksoy N, et al. Management of epididymal cysts in childhood. *J Pediatr Surg* 2013;48:2153-6. <https://doi.org/10.1016/j.jpedsurg.2013.01.058>
14. Jelloul L, Billerey C, Ait Ali Slimane M, et al. Epididymal cysts in adolescents. *Ann Urol* 1999;33:104-8.
15. Annam A, Munden MM, Mehollin-Ray AR, et al. Extratesticular masses in children: Taking ultrasound beyond paratesticular rhabdomyosarcoma. *Pediatr Radiol* 2015;45:1382-91. <https://doi.org/10.1007/s00247-015-3316-x>
16. Woodward PJ, Schwab CM, Sesterhenn IA. From the archives of the AFIP: Extratesticular scrotal masses: Radiologic-pathologic correlation. *Radiographics* 2003;23:215-40. <https://doi.org/10.1148/rgr.231025133>
17. Aragona F, Pescatori E, Talenti E, et al. Painless scrotal masses in the pediatric population: Prevalence and age distribution of different pathological conditions – a 10-year, retrospective, multicenter study. *J Urol* 1996;155:1424-6. [https://doi.org/10.1016/S0022-5347\(01\)66299-2](https://doi.org/10.1016/S0022-5347(01)66299-2)
18. Patoulas D, Kalogirou M, Patoulas I. Intraparenchymal epididymal cyst (IEC) 4 cm in diameter in a 15-year-old male patient: A case report and review of the literature. *Acta Medica (Hradec Kralove)* 2016;59:137-9. <https://doi.org/10.14712/18059694.2017.41>
19. Erikçi V, Hoşgör M, Yıldız M, et al. Torsion of an epididymal cyst: A case report and review of the literature. *Türk J Pediatr* 2013;55:659-61.
20. Yılmaz E, Batıslam E, Bozdoğan O, et al. Torsion of an epididymal cyst. *Int J Urol* 2004;11:182-3. <https://doi.org/10.1111/j.1442-2042.2003.00764.x>
21. Odabaş O, Aydın S, Yılmaz Y. Torsion of a spermatocele. *J Urol* 1995;154:2143. [https://doi.org/10.1016/S0022-5347\(01\)66717-X](https://doi.org/10.1016/S0022-5347(01)66717-X)
22. Lord PH. A bloodless operation for spermatocele or cyst of the epididymis. *Br J Surg* 1970;57:641-4. <https://doi.org/10.1002/bjs.1800570902>
23. Menon VS, Sheridan WG. Benign scrotal pathology: Should all patients undergo surgery? *BJU Int* 2001;88:251-4. <https://doi.org/10.1046/j.1464-410x.2001.02276.x>
24. Heindorff H, Johansen JR, Lausten GS. Spermatocele of the testis: A followup study of 42 surgically treated patients. *Ugeskr Laeger* 1983;145:1302-3.
25. Tammela TL, Hellström PA, Mattila SI, et al. Ethanolamine oleate sclerotherapy for hydroceles and spermatoceles: A survey of 158 patients with ultrasound followup. *J Urol* 1992;147:1551-3. [https://doi.org/10.1016/S0022-5347\(17\)37623-1](https://doi.org/10.1016/S0022-5347(17)37623-1)
26. Mattila SI, Tammela TL, Makarainen HP, et al. Ultrasound followup of ethanolamine oleate sclerotherapy for spermatoceles. *Eur Urol* 1993;23:361-5. <https://doi.org/10.1159/000474630>
27. Hicks N, Gupta S. Complications and risk factors in elective benign scrotal surgery. *Scand J Urol* 2016;50:468-71. <https://doi.org/10.1080/21681805.2016.1204622>
28. Kiddoo DA, Wollin TA, Mador DR. A population-based assessment of complications following outpatient hydrocelectomy and spermatocelectomy. *J Urol* 2004;171: 46-8. <https://doi.org/10.1097/01.ju.0000103636.61790.43>
29. Skakkebaek NE, Rajpert-DeMeyts E, Main KM. Testicular dysgenesis syndrome: An increasingly common developmental disorder with environmental aspects. *Hum Reprod* 2001;16:972-8. <https://doi.org/10.1093/humrep/16.5.972>

Correspondence: Dr. Fardod O'Kelly, Division of Pediatric Urology, Children's Hospital of Eastern Ontario, Ottawa, ON, Canada; fokelly@rcsi.ie