

DrillCut™ vs VersaCut™ prostate tissue morcellation devices after holmium laser enucleation: A prospective, randomized controlled trial

Ahmed Ibrahim, MD, MSc¹; Mostafa M. Elhilali, MD, PhD, FRCSC¹; Mohammed A. Elkoushy, MD, PhD^{1,2}; Sero Andonian, MD, MSc, FRCSC, FACS^{1*}; Serge Carrier, MD, FRCSC^{1*}

¹Department of Urology, McGill University Health Centre, Montreal, QC, Canada; ²Department of Urology, Suez Canal University, Egypt

*Co-senior authors

Acknowledgement: CUA-SIU International Scholarship to Dr Ahmed Ibrahim.

Cite as: *Can Urol Assoc J* 2018 December 3; Epub ahead of print.
<http://dx.doi.org/10.5489/cuaj.5626>

Published online December 3, 2018

Abstract

Introduction: We aimed to compare efficacy, safety, and cost of disposables of the DrillCut™ morcellator with the VersaCut™ morcellator after holmium laser enucleation of the prostate (HoLEP).

Methods: After obtaining ethical approval, consecutive patients undergoing HoLEP for symptomatic benign prostatic hyperplasia were randomized to have their enucleated prostates morcellated by either Karl Storz® DrillCut™ or Lumenis® VersaCut™ morcellators. All procedures were performed by two experienced urologists. Patients' demographics and perioperative data were recorded. Both morcellators were compared for their safety, efficacy, and cost-effectiveness.

Results: Eighty-two patients were included in the study (41 per each arm). Both groups were comparable in terms of age, preoperative prostate size (114 vs. 112 mL; $p>0.05$), enucleation time (95.3 vs. 91.7 minutes; $p>0.05$), and morcellation time (22.6 vs. 17.3 minutes; $p>0.05$). The DrillCut™ was associated with significantly lower morcellation rate when compared with the VersaCut™ (3.6 vs. 4.9 g/min; $p=0.03$). In terms of safety, there was no significant difference between both morcellators in complication rates (2.4% vs. 7.3 %; $p=0.1$). However, there was one case of bladder perforation requiring exploration with the VersaCut™. The DrillCut™ was associated with significantly higher cost of disposables when compared with the VersaCut™ (\$247.5 vs. \$160.9; $p<0.01$).

Conclusions: Despite the small sample size, the DrillCut™ was associated with lower morcellation rate when compared with the VersaCut™. However, this difference may not be clinically significant. Although both morcellators were comparable in their safety, the DrillCut™ was associated with higher cost of disposables when compared with the VersaCut™.

Introduction

Bothersome lower urinary tract symptoms (LUTS) secondary to benign prostatic hyperplasia (BPH) is a common problem, which impacts patients' quality of life. Transurethral resection of the prostate (TURP) was considered the surgical gold standard for treatment of bladder outlet obstruction (BOO) secondary to BPH for more than 2 decades. Currently, different types of laser procedures have been used as alternatives to TURP due to lower morbidity and higher efficiency.^{1,2}

Introduction of the Holmium laser represented a turning point in minimally-invasive laser therapy for BPH as it achieves size-independent prostatic cavity similar to simple open prostatectomy with significantly lower perioperative morbidity.³ It has successfully passed the steps of validation through a growing number of well-designed randomized controlled studies.^{4,5} Consequently, recent guidelines now incorporate holmium laser enucleation of the prostate (HoLEP) as an alternative option for treatment of symptomatic BPH with high level of evidence for safety and efficacy.⁶

HoLEP has been criticized for its long procedural time, which consists of two critical steps of transitional zone enucleation followed by tissue morcellation. All endoscopic enucleation techniques end by completely detaching the adenoma and depositing it in the bladder. Although several technical modifications have been made during the last several years to improve the efficacy of enucleation, the optimal morcellation device is still unknown.^{7,8}

Morcellation time depends mainly on the amount of enucleated prostatic tissue, visualization during morcellation and the device used for morcellation. Currently, there are three popular prostate tissue morcellators, which differ from each other by the type of movement of the cutting blades (guillotine vs. oscillation) and shape of the blade (non-toothed vs. toothed). While the DrillCut™ (Karl Storz Inc., Tuttlingen, Germany) morcellator has an oscillating toothed-blade and the Piranha™ morcellator (Richard Wolf Inc., Knittlingen, Germany) has a rotating toothed-blade, the VersaCut™ (Versapulse; Lumenis Inc., Santa Clara, CA) has a non-toothed guillotine blade. Piranha™ and VersaCut™ morcellators have been previously compared with mixed results.^{9,10} However, there are no randomized clinical trials comparing DrillCut™ and VersaCut™ morcellators. Therefore, the aim of present study was to compare efficacy, safety and cost of disposables of the new Karl Storz® DrillCut™ with the original Lumenis® VersaCut™ morcellator after HoLEP in a prospective randomized fashion.

Methods

This is a prospective randomized clinical study in which consecutive patients undergoing HoLEP for BPH were randomly assigned to have their enucleated prostate morcellated by either Karl Storz® DrillCut™ or Lumenis® VersaCut™ by two experienced urologists. Although one surgeon had more experience than the other, both surgeons had performed at least 500 HoLEP procedures each using the VersaCut™ morcellator prior to the trial. The study was approved by the local ethics committee. Inclusion criteria for the study were male subjects over 40 years of age presenting with BOO due to BPH and scheduled for HoLEP. Written informed consents were obtained prior to enrollment into the study. Patients with previous surgical treatment for BPH, uncorrected coagulopathy, in addition to patients with history of prostate cancer were excluded from the study.

Sample size calculation

At the time of sample size calculation, there was only one published randomized clinical study comparing the gold standard VersaCut™ to the newer Piranha™ morcellator.⁹ In that study, they had powered to detect a difference of 2.5 grams per minute in morcellation rate and their sample size was calculated to consist of 35 patients in each arm.⁹ At the end of their study, they found no statistically significant difference in the morcellation rates of Piranha™ and VersaCut™ (5.6 vs 4.8 grams per minute; $p=0.14$).⁹ There were no other published studies regarding the morcellation rate of the latest DrillCut™ morcellator. Therefore, this study was powered to detect a difference in morcellation rate of 2 grams per minute between DrillCut™ and VersaCut™ morcellators. We hypothesized that 2 grams per minute difference in morcellation rate would be clinically significant between the two morcellators (morcellation efficiency). Type I error (alpha) was set at 0.05 (two-tailed) and type II error (beta) was set at 0.2 (power of 80%). This yielded a projected overall sample size of 82 patients (41 per arm).

Randomization

Patients were randomly assigned into 2 groups using stratified block randomization depending on the initial prostate size (40-80ml and >80ml) measured by trans-rectal ultrasound (TRUS). Computer-generated random tables in a 1:1 ratio were used. Randomization occurred after performance of TRUS for measurement of prostate volume. Using an Excel sheet, the RAND function was used to give a random code. Either one of two strata was used based on the prostate size; small or large block of 5 or 8 cells, respectively. The random code is a figure ranging from 0.00000000 to 0.9999999999. A 0.5 cutoff code was used, below which the small blocks of 4 cells were used and above which the large blocks of 8 cells was used. The aim was to have balanced groups in terms of the prostate size.

Surgical technique

HoLEP procedure basically involves anatomical dissection of the prostatic adenoma off the surgical capsule via a retrograde approach, starting at the apex. A 120 W holmium laser generator (Lumenis Pulse™ P120H, Yokneam, Israel) was connected to a reusable 550-nm quartz end-firing fiber (SlimLine™ 550, Lumenis Inc.) and used through a modified continuous-flow 26 Fr resectoscope with a distal bridge and video system. An enucleation loop has been recently used as a laser guide with a retracting beak and a working element. Under general or regional anesthesia, using warm normal saline as an irrigant, urethral meatal calibration was performed using Van Buren sounds up to 30 French (Fr). Based on the prostate anatomy and the presence of a prominent median lobe, either a one, two or three-lobe technique was performed. Rigid indirect nephroscope, with a 5-mm working channel, was used to introduce the tissue morcellator at the end of the procedure using dual irrigation system. Both morcellators were present at our institution before starting randomization. Prior to starting our randomized study, we tested the new DrillCut™ morcellator at different morcellation speeds and we found that when using higher rpms than the recommended 1500rpm, there was a problem with the suction mechanism of the morcellator which affected the morcellation rate. Therefore, the DrillCut™ morcellator was set at the manufacturer's recommended setting of 1,500 rpm to achieve maximum efficiency. For the Lumenis VersaCut™, the foot switch was used to control the speed of morcellation based on the subjective feel of the quality of morcellated tissues and the need for suction. It was not possible to track the morcellation speed of the VersaCut™ morcellator since there are no log files that could be analyzed. For the purposes of standardization, every blade was used for a maximum of 4 times for both morcellators. Following morcellation of the prostate tissue, a standard 22Fr two-way or three-way catheter was inserted with intermittent or continuous bladder irrigation, respectively. The urethral catheter was removed on post-operative day 1 and the patient was discharged home.

The following morcellator parameters were collected: morcellation time defined as the time from introduction of the morcellator blade into the bladder until extraction of the last piece of the prostatic adenoma; morcellation rate (efficiency) as calculated by dividing the weight of the prostate specimen by the time needed for retrieval (g/min); incidence of difficult morcellation due to tissue consistency (beach balls or snow balls); device-related complications; device malfunction; and cost of disposable instruments. All subjects were followed-up to assess perioperative and postoperative adverse events related to the procedure.

Statistical analyses

Data was collected and tabulated using the commercially available SPSS software version 21 (SPSS Inc., Chicago, IL, USA). Descriptive statistics were provided for the efficacy outcome results and were presented in terms of percentages, frequencies, means, and medians. Differences between both groups were compared with the Fisher's exact test for categorical variables and Student's t-test or Mann Whitney-U test was performed to compare normally and abnormally

distributed continuous variables, respectively. Two-tailed p-values of less than 0.05 were set for statistical significance.

Results

A total of 82 patients were included in the final analysis in this open-label randomized controlled trial (41 patients in each arm) between June 2016 and October 2017 (Figure 1). There were no significant differences between both groups in terms of age, pre-HoLEP PSA and prostate size as assessed by trans-rectal ultrasound. Baseline and pre-operative characteristics are presented in (Table 1). Each surgeon performed comparable number of morcellations using DrillCut™ and VersaCut™ morcellators.

Intra-operatively, there was a significant difference between the two morcellators in terms of morcellation rate. The mean morcellation rate of the DrillCut™ was significantly lower than the mean morcellation rate of the VersaCut™ morcellator (3.6 vs. 4.9 g/min, $p=0.03$). However, there were no significant differences in terms of enucleation time, morcellation time, beach-ball identification and pathological specimen after morcellation ($p>0.05$) (Table 2). Similarly, there was no significant difference in the incidence of difficult morcellation (difficult engagement of the tissue to the morcellator blade) (Table 2). The difference in morcellation rate, however, did not reach our clinically significant difference in morcellation efficiency of 2 grams per minute between both devices as we defined it.

In terms of complications, there was no significant difference in the rate of device-related complications between the DrillCut™ and VersaCut™ morcellators, respectively (2.4 vs. 7.3%, $p>0.05$) (Table 2). There was only one patient (2.4%) who had small mucosal injury with the DrillCut™ morcellator which did not require prolonged catheterization (Table 2). There were 3 intra-operative complications (7.3%) with the VersaCut™ morcellator with 2 (4.8%) cases of small mucosal injury, which did not require prolonged catheterization and one (2.4%) case of bladder perforation requiring open exploration. This was a 68-year-old patient with 127g prostate undergoing HoLEP for urinary retention. During prostate enucleation, the bladder neck was slightly undermined, and the surgical capsule was thin. When morcellation with the VersaCut™ morcellator started, visibility was suboptimal. After 15 minutes of morcellation, the bladder could not be adequately distended. In addition, the patient's abdomen was distended. Bladder perforation was suspected, and the morcellation was aborted. A retrograde cystogram was performed and showed extra-peritoneal extravasation of contrast. As a precaution, an open cystostomy was performed with retrieval of prostatic lobes and the wound was closed in layers. The patient's urine was clear the next day without continuous bladder irrigation. He was discharged home with an indwelling urethral catheter and a successful trial of void a week later.

The cost of disposable instruments per case was significantly higher with the DrillCut™ morcellator (247.50\$) when compared with the VersaCut™ morcellator (160.90\$) ($p < 0.001$) (Table 2).

Discussion

HoLEP has proved itself as the only endoscopic procedure with superior efficacy compared with the traditional transurethral resection of the prostate (TURP).¹¹ Meta-analyses have confirmed how well established HoLEP has now become the new gold standard for management of symptomatic BPH, with a low long-term re-treatment rate in addition to greater improvement in prostate symptom scores and flow rates when compared with TURP.¹²⁻¹⁵ However, the HoLEP technique is hindered by longer learning curve and operative time, consisting of enucleation time and morcellation time. The DrillCut™ morcellator has been recently introduced by Karl Storz. However, there are no randomized trials comparing DrillCut™ and VersaCut™ morcellators. Therefore, in the present study, we compared the DrillCut™ morcellator to the VersaCut™ morcellator in terms of efficacy, safety, and cost-effectiveness in a prospective randomized fashion.

Both groups were comparable in terms of pre-operative TRUS volume, enucleation time, and morcellation time (Table 2). However, there was a significant difference between both morcellators in terms of morcellation rate (efficiency). The mean morcellation rate of the DrillCut™ morcellator was significantly lower than that of the VersaCut™ morcellator (3.6 vs. 4.9 g/min, $p=0.03$). However, the difference in morcellation efficiency of 1.3g/min did not reach our target difference in morcellation rate of 2 grams per minute and may not be clinically significant.

There was no statistically significant difference between both morcellators in terms of device malfunction (9.7% vs. 4.8%; $p>0.05$). During two cases randomized to the DrillCut™ morcellator, the blades of the morcellator were changed due to inappropriate suction or difficulty in engaging tissues. In addition, during two cases randomized to the VersaCut™ morcellator, there were temporary device malfunctions, which did not require changing the blades of the VersaCut™ morcellator. One case of DrillCut™ morcellator malfunction required switching to the VersaCut™ morcellator due to suction pump failure of the DrillCut™ morcellator. These troubleshooting problems may have increased the overall operative and morcellation times.

Although device-related complications of the DrillCut™ morcellator was less than the VersaCut™ morcellator, it did not reach statistical difference (2.4 vs 7.3 %; $p>0.05$). The lack of the difference may have been due to small sample size. In the present study, there was 4.8% bladder mucosal injury with the VersaCut™ morcellator and 2.4% with DrillCut™ morcellator. In addition, there was one case (2.4%) of bladder perforation with the VersaCut™ morcellator requiring open repair. In the literature, bladder mucosal injuries during HOLEP are reported at a rate of 0.7- 5.7% and bladder perforation during HOLEP are reported at a rate of 0.1-1.5%.^{9,15,16} Small mucosal injuries result from poor vision during morcellation or from large adenomas morcellated in small bladders. Therefore, with suboptimal vision, care must be taken during morcellation, especially when using the VersaCut™ morcellator. The two attending urologists

preferred to use the DrillCut™ morcellator due to its subjective feeling of safety in avoiding bladder perforations.

With regards to the cost of disposable instruments per case, it was found that the new DrillCut™ morcellator was more expensive than the VersaCut™ morcellator (247.50 vs. 160.90\$; $p < 0.01$). The price difference could be explained by the expensive disposable double tubing (suction and irrigation) and blades of the DrillCut™ morcellator when compared with the VersaCut™ morcellator.

The study is not without limitations including non-blinding of surgeons due to difference in the shape and setup of both morcellators. In addition, the small sample size may have led to type II error in determining statistically significant difference in safety of both morcellators. Other confounders might have affected the morcellation time such as the quality of the prostatic tissue and presence of bleeding from the enucleation bed that may have led to poor vision during morcellation leading to increased time needed for morcellation. However, these confounders were present in both arms and randomization would have decreased the bias. Since the Lumenis VersaCut™ was the original morcellator and the Storz DrillCut™ morcellator recently came on the market, both surgeons had more experience with the Lumenis VersaCut™ morcellator. While both surgeons and operating room personnel were trained on the new DrillCut™ morcellator prior to its use in the trial, it is possible that the differences seen in the morcellation rates are related to both surgeons being more familiar with the VersaCut™ morcellator. Yet, at the end of the trial, both surgeons preferred the use of the newer DrillCut™ morcellator due to its safety profile subjectively. Despite these limitations, this is the first randomized clinical study comparing the new DrillCut™ to the original VersaCut™ prostate tissue morcellators during HoLEP.

Conclusion

While the DrillCut™ was associated with lower morcellation rate when compared with the VersaCut™, this was not clinically significant. Although both DrillCut™ and VersaCut™ morcellators were comparable in their safety, the DrillCut™ was associated with higher cost of disposables when compared with the VersaCut™.

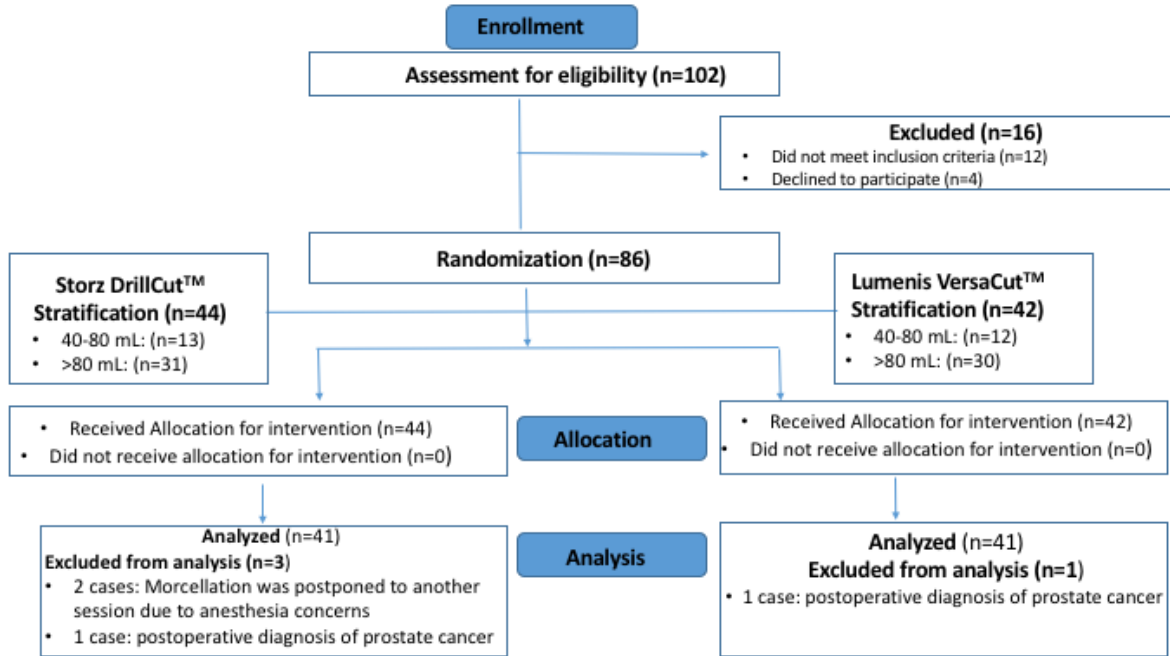
References

1. Neill MG, Gilling PJ, Kennett KM, et al. Randomized trial comparing holmium laser enucleation of prostate with plasmakinetic enucleation of prostate for treatment of benign prostatic hyperplasia. *Urology* 2006; 68(5):1020-1024.
2. Kuntz RM. Current role of lasers in the treatment of benign prostatic hyperplasia (BPH). *Eur Urol* 2006; 49(6):961–969.
3. Elzayat EA, Elhilali MM: Holmium laser enucleation of the prostate (HoLEP): the endourologic alternative to open prostatectomy. *Eur Urol* 2006; 49(1):87-91.
4. Toohar R, Sutherland P, Costello A, et al: A systematic review of holmium laser prostatectomy for benign prostatic hyperplasia. *J Urol* 2004; 171(5):1773-1781.
5. Kuntz RM, Lehrich K, Ahyai SA: Holmium laser enucleation of the prostate versus open prostatectomy for prostates greater than 100 grams: 5-year follow-up results of a randomized clinical trial. *Eur Urol* 2008; 53(1):160-166.
6. Van Rij S, Gilling PJ. In 2013, Holmium Laser Enucleation of the Prostate (HoLEP) May Be the New ‘Gold Standard’. *Curr Urol Rep* 2012; 13(6):427–432.
7. Ahyai SA, Gilling P, Kaplan SA et al: Meta-analysis of functional outcomes and complications following transurethral procedures for lower urinary tract symptoms resulting from benign prostatic enlargement. *Eur Urol* 2010; 58: 384-397.
8. Dusing MW, Krambeck AE, Terry C et al: Holmium laser enucleation of the prostate: efficiency gained by experience and operative technique. *J Urol* 2010; 184: 635-640.
9. El Tayeb MM, Borofsky MS, Paonessa JE et al: Wolf Piranha Versus Lumenis VersaCut Prostate Morcellation Devices: A Prospective Randomized Trial. *J Urol.* 2016; 195(2):413-417.
10. Nickel JC, Aaron L, Barkin J, et al: Canadian urological association guideline on male lower urinary tract symptoms/benign prostatic hyperplasia (MLUTS/BPH): 2018 update. *Can Urol Assoc J.* 2018;12(10):303-12.
11. McAdams S, Nunez-Nateras R, Martin CJ et al: Morcellation Efficiency in Holmium Laser Enucleation of the Prostate: Oscillating Morcellator Outperforms Reciprocating Morcellator with No Apparent Learning Curve. *Urology* 2017; 106:173-177.
12. Tan A, Liao C, Mo Z et al: Meta-analysis of holmium laser enucleation versus transurethral resection of the prostate for symptomatic prostatic obstruction. *Br J Surg* 2007; 94: 1201-1208.
13. Elmansy HM, Kotb A and Elhilali MM: Holmium laser enucleation of the prostate: long-term durability of clinical outcomes and complication rates during 10 years of follow-up. *J Urol* 2011; 186: 1972-1976.
14. Toohar R, Sutherland P, Costello A, et al: A systematic review of holmium laser prostatectomy for benign prostatic hyperplasia. *J Urol* 2004; 171(5):1773-1781.
15. Elkoushy MA, Elshal AM, Elhilali MM. Reoperation after Holmium Laser Enucleation of the Prostate for Management of Benign Prostatic Hyperplasia: Assessment of Risk Factors with Time to Event Analysis. *J Endourol.* 2015; 29(7):797-804.
16. Elshal AM, Mekkawy R, Laymon M, et al: Towards optimizing prostate tissue retrieval following holmium laser enucleation of the prostate (HoLEP): Assessment of two morcellators and review of literature. *Can Urol Assoc J.* 2015; 9(9-10): E618-E625.

17. Peacock J, Mahesan T, Frymann R. Morcellator efficiency of the Wolf Piranha, Lumenis VersaCut and Storz Drillcut-X II morcellators: A retrospective trial and review of the literature. *Int J Surg.* 2018; 55(Suppl 1): S122.

DRAFT

Figures and Tables

Fig. 1. CONSORT (Consolidated Standards of Reporting Trials) flowchart for study participants.**Table 1. Baseline and preoperative data**

Parameter	Storz DrillCut™ n=41	Lumenis VersaCut™ n=41	p
Age (years) (mean±SD)	70.7±9.6	71.4±7.9	0.22
ASA score (mean±SD)	1.39±0.69	1.42±0.73	0.13
Prostate volume (mL) (mean±SD)	114±48.3	112±44.9	0.121
Mean serum PSA (ng/mL) (mean±SD)	6.2±3.2	5.9±4.9	0.42
IPSS (mean±SD)	13.8±5.1	12.7±4.9	0.29
Quality of life score (mean±SD)	3.66±1.35	3.52±1.44	0.18
Max flow rate (mL/s) (mean±SD)	7.57±3.63	8.20±3.35	0.09
Post-void residual urine (mL) (mean±SD)	189.2±166.5	187.6±182.1	0.39

ASA: American Society of Anesthesiologists; IPSS: International Prostate Symptom Score;
PSA: prostate-specific antigen; SD: standard deviation.

Table 2. Intraoperative and post-operative data

Parameter	Storz DrillCut™	Lumenis VersaCut™	P
Enucleation time (mean±SD)	95.3±30.4	91.7±25.7	0.639
Morcellation time (mean±SD)	22.6±11.7	17.3±12.1	0.236
Morcellated tissue weight (g) (mean±SD)	79.9±38.2	76.6±45.1	0.709
Morcellation efficiency (g/min) (mean±SD)	3.6±0.9	4.9±1.1	0.03
Total operation time (min) (mean±SD)	129±40.5	122.1±38.7	0.792
Total lasing energy (kJ) (mean±SD)	192.8±139.6	189.1±131.2	0.24
No. complications, n (%)	1 (2.4%)	3 (7.3%)	1.0
Bladder mucosal injury, n (%)	1 (2.4%)	2 (4.8 %)	1.0
Bladder perforation, n (%)	0 (0%)	1 (2.4%)	1.0
Difficult visualization, n (%)	3 (7.3%)	4 (9.7%)	1.0
Difficult morcellation, n (%)	5 (12.2%)	3 (7.3%)	1.0
Device malfunction, n (%)	4 (9.7%)	2 (4.8 %)	1.0
Failure of morcellation, n (%)	1 (2.4%)	0 (0%)	1.0
Presence of beach balls, n (%)	4 (9.7%)	2 (4.8%)	1.0
Mean hospital stay (hours)	28±2.7	30±6.1	0.670
Cost of disposables (CAD\$/pt)	247.5	160.9	< 0.001

SD: standard deviation.