

Techniques – Orthotopic kidney transplantation in patients with diseased inferior vena cava

Ernest Chan, MD¹; Alp Sener, MD^{1,2}; Vivian C. McAlister, MD^{1,2}, Patrick P. Luke, MD^{1,2}

¹Western University Schulich School of Medicine and Dentistry, Western University, London, ON, Canada; ²Department of Surgery, London Health Sciences Centre, Western University, London, ON, Canada; ³Multi-Organ Transplant Program, London Health Sciences Centre, Western University, London, ON, Canada

Cite as: *Can Urol Assoc J* 2019;13(5):E154-6. <http://dx.doi.org/10.5489/cuaj.5515>

Published online October 15, 2018

Introduction

Heterotopic renal transplantation is the treatment of choice for patients with end-stage renal disease (ESRD). ESRD may be associated with inferior vena cava (IVC) thrombosis as a consequence of femoral dialysis catheter placement, IVC filter or stent, or hypercoagulable states,¹ precluding renal transplantation into the iliac fossa. In such patients, orthotopic kidney transplantation (OKT) has been described with acceptable rates of complications and reasonable long-term graft outcomes.²⁻⁵

We review the results of three OKTs performed primarily as a strategy to avoid the lower IVC and iliac vessels. The goal of this report is to describe technical variations in kidney transplantation that can be used to approach the diseased IVC and describe their associated functional outcomes.

Methods

Between 2009 and 2014, 370 deceased donor and 109 living donor kidney transplants were performed at London Health Sciences Centre. Three cases of OKT were performed. Clinical data, surgical reports, and complications were collected retrospectively. Patient characteristics, cause of ESRD, indications for OKT, renal graft characteristics, surgical technique, complications, graft function, and patient survival were included in our analysis.

Results

Patient characteristics, renal disease, and indications for OKT are outlined in Table 1. Mean patient age was 51 years and the mean followup was 4.45 years. All were first kidney transplants. Mean age of donor was 43 years; all were standard criteria donors. Technical aspects of OKTs are listed in Table

2. Diagrams of arterial, venous, and urinary anastomoses are found in Fig. 1. No patients experienced graft rejection.

Case reports

Case 1

A 54-year-old female presented with short gut syndrome secondary to multiple bowel resections related to Crohn's disease. She received a small bowel transplant but developed ESRD secondary to calcineurin inhibitor toxicity. This was complicated by thrombosis of the IVC and superior vena cava (SVC). Translumbar dialysis catheter was the last available access point for hemodialysis. She underwent OKT through a retroperitoneal flank incision to avoid the peritoneal cavity. Estimated blood loss was 400 ml. Her postoperative course was complicated by a left flank incisional wound infection (Clavien II).

Case 2

A 44-year-old paraplegic male presented with ESRD secondary to neurogenic bladder and obstructive uropathy. A femoral dialysis catheter was placed due to loss of hemodialysis access from thrombosis, which led to IVC stenosis requiring placement of IVC stent. He had previous cystoprostatectomy with ileal conduit. Vascular reconstruction was performed with a donor carotid artery extension and donor caval extension. Ureteral anastomosis was performed to a stenotic ileal conduit that required reconstruction. The operation was eight hours in duration with three units of blood transfused. The postoperative course was complicated by wound dehiscence (Clavien IIIa). He died five years later from cardiovascular disease with functioning allograft.

Case 3

A 69-year-old male developed ESRD secondary to obstructive uropathy from idiopathic retroperitoneal fibrosis. He also

Table 1. Patient demographics, indications for orthotopic kidney transplantation, and followup result

	Case 1	Case 2	Case 3
Recipient age	54	44	69
Recipient sex	F	M	M
Recipient renal disease	Drug nephrotoxicity	Obstructive uropathy	Obstructive uropathy
Indication for OKT	IVC thrombosis	IVC stenosis/stent	IVC thrombosis
Donor type	SCD/NDD	SCD/NDD	SCD/DCD
Donor age	41	36.6	51.4
Side transplanted	Left	Right	Right
Serum creatinine, 1 year ($\mu\text{mol/L}$)	136	62	154
Serum creatinine, 3 years ($\mu\text{mol/L}$)	130	65	238
Followup duration (years)	2.89	5.39	5.08
Death	No	Yes	No

DCD: donation after cardiac death; IVC: inferior vena cava; NDD: neurologic determination of death; SCD: standard criteria donor.

had IVC thrombosis from an IVC filter. Intraoperatively, the lower aspect of the great vessels was found to be encased in retroperitoneal fibrosis, particularly around the IVC filter. A donor iliac artery jump graft was used to lengthen the donor kidney artery approximately 10 cm and was anastomosed to the right common iliac artery (Fig. 2.). The donor renal vein with caval extension was anastomosed to the right renal vein. The long vascular conduits allowed the donor ureter to be anastomosed to the bladder. The estimated blood loss was 500–700 ml. Postoperatively, this patient had delayed graft function and developed abdominal hematomas requiring transfusion of four units of blood (Clavien II).

Discussion

OKT for IVC thrombosis was first described in 1976 by Mozes et al.⁶ Since the introduction of this approach, there have been reports of stable graft function up to six months.⁷ However, there has been limited reports of OKT in adults with IVC disease with long-term followup.⁸ To our knowledge, this is the largest case series of OKT indicated for the diseased IVC with long-term followup. We present three cases of OKT with different surgical approaches for vascular and urinary tract reconstruction.

Arterial reconstruction during OKT can be achieved through anastomosis of the donor renal artery to the native

splenic, renal, or hepatic artery, as well as the aorta.⁹ In our series, we used donor carotid artery extension and iliac artery extension for anastomosis to the right common iliac artery in separate cases. In one case, a donor kidney had three separate vessels conjoined as a single unit for anastomosis. Although the splenic artery and aorta were not used in this series, we were prepared to use these vessels.

Venous reconstruction was achieved through anastomosis of the donor renal vein, with or without donor IVC extension, to the native renal vein. In the setting of OKT for IVC thrombosis, venous anastomosis to the splenic vein, inferior mesenteric vein, superior mesenteric vein, and native renal vein have been described.^{7,8,10} It is possible that a portion of the external iliac vein that was free of thrombus could have been used in these cases, but this was avoided due to limited ability to exclude venous thrombus, high venous resistance (despite collaterals), or vascular injury.

Options for urinary drainage during OKT include pyelo-ureterostomy and ureteroureterostomy.² In this series, reconstruction was performed by anastomosis of the donor renal pelvis or ureter to the recipient ureter, bladder, and ileal conduit, respectively. Donor ureteral anastomosis was performed to the native bladder in Case 3 due to history of retroperitoneal fibrosis. Adequate ureteral length was obtained while avoiding the risks of stenosis and devascularization related to anastomosis to an encased native ureter.

Table 2. Technical aspects of orthotopic kidney transplantation and graft function

Case	Incision	Arterial reconstruction	Venous reconstruction	Urinary tract reconstruction	Additional procedures
1	Left flank retroperitoneal incision	Three renal artery branches reconstructed for anastomosis end-to-end with recipient left renal artery	Left donor renal vein anastomosed to native renal vein	Donor renal pelvis anastomosed to the native ureter	Retroperitoneal strip mesh reinforcement
2	Chevron incision	Donor carotid artery extension graft for anastomosis between donor renal artery and right common iliac artery	Caval extension of donor renal vein anastomosed to native renal vein	Donor ureter anastomosed to reconstructed ileal conduit	Nephropexy
3	Midline incision	Donor iliac artery extension anastomosed to right common iliac artery	Caval extension of donor renal vein anastomosed to native renal vein	Donor ureter anastomosed to native bladder	Nephropexy and ventral hernia repair

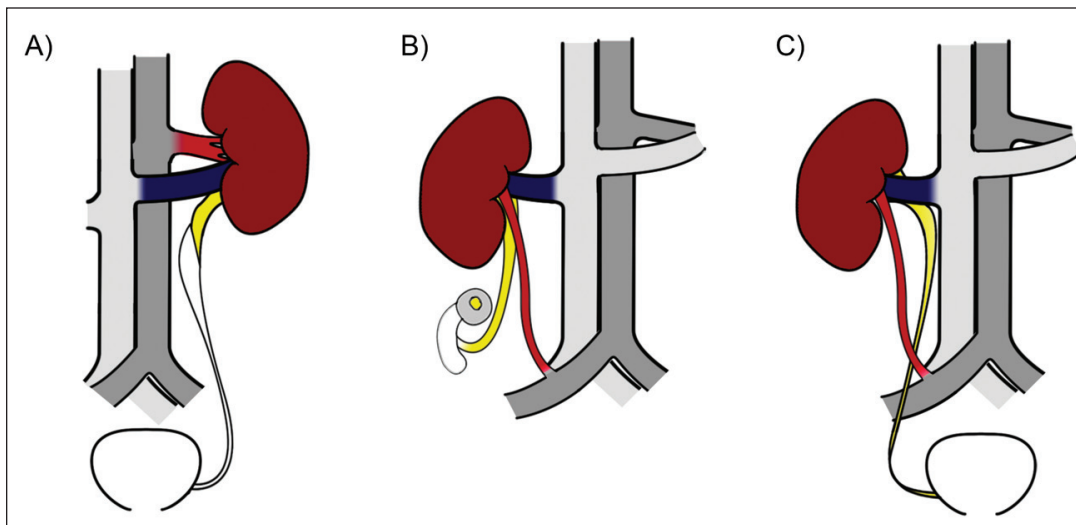


Fig. 1. Diagrams for orthotopic kidney transplants (OKT) performed in current series. **(A)** Case 1 OKT with left donor kidney. **(B)** Case 2 OKT with right donor kidney; ureteral anastomoses to ileal conduit. **(C)** Case 3 OKT with right donor kidney.

Complication rates in our series and others have been significant. Reported complications from OKT include arterial stenosis, urinary fistulas, urolithiasis, arterial and venous thrombosis, and reflux nephropathy.²

Conclusion

OKT is a viable approach for patients with ESRD who cannot undergo heterotopic kidney transplantation due to thrombosis, stenosis, or stenting of the IVC with acceptable long-term functional outcomes. Different approaches to arterial, venous, and urinary tract reconstruction are viable for patients with anatomical complexities such as multiple arteries, short veins, retroperitoneal fibrosis, or urinary diversions.

Competing interests: The authors report no competing personal or financial interests related to this work.

This paper has been peer-reviewed.

References

- Alkhouli M, Morad M, Narins CR, et al. Inferior vena cava thrombosis. *JACC* 2016;9:629-43. <https://doi.org/10.1016/j.jcin.2015.12.268>
- Hevia V, Gomez V, Alvarez S, et al. Orthotopic kidney transplant: A valid surgical alternative for complex patients. *Curr Urol Rep* 2015;16:470. <https://doi.org/10.1007/s11934-014-0470-x>
- Paduch DA, Barry JM, Arsanjani A, et al. Indication, surgical technique and outcome of orthotopic renal transplantation. *J Urol* 2001;166:1647-50. [https://doi.org/10.1016/S0022-5347\(05\)65645-5](https://doi.org/10.1016/S0022-5347(05)65645-5)
- Musquera M, Peri LL, Alvarez-Vijande R, Oppenheimer F, et al. Orthotopic kidney transplantation: An alternative surgical technique in selected patients. *Eur Urol* 2010;58:927-33. <https://doi.org/10.1016/j.euro.2010.09.023>
- Cornejo F, Arango O, Talbot-Wright R, et al. Ileal conduit and orthotopic renal transplantation. An alternative in pathology of the nonviable lower urinary tract. *Eur Urol* 1988;14:77-9. <https://doi.org/10.1159/000472903>
- Mozes MF, Kjellstrand CM, Simmons RL, et al. Orthotopic renal homotransplantation in a patient with thrombosis of the inferior vena cava. *Am J Surg* 1976;131:633-6. [https://doi.org/10.1016/0002-9610\(76\)90032-5](https://doi.org/10.1016/0002-9610(76)90032-5)
- Patel P, Krishnamurthi V. Successful use of the inferior mesenteric vein for renal transplantation. *Am J Transplant* 2003;3:1040-2. <https://doi.org/10.1034/j.1600-6143.2003.00177.x>
- Aguirrezabalaga J, Novas S, Veiga F, et al. Renal transplantation with venous drainage through the superior mesenteric vein in cases of thrombosis of the inferior vena cava. *Transplantation* 2002;74:413-5. <https://doi.org/10.1097/00007890-200208150-00022>
- Novick AC, Banowsky LH, Stewart BH, et al. Renal revascularization in patients with severe atherosclerosis of the abdominal aorta or a previous operation on the abdominal aorta. *Surg Gynecol Obstet* 1977;144:211-8.
- Rizzello A, Smyth O, Patel N, et al. Successful splenic venous drainage for kidney transplant in case of inferior vena cava thrombosis. *Transplantation* 2011;92:e59-e60. <https://doi.org/10.1097/TP.0b013e3182352d86>

Correspondence: Dr. Patrick P. Luke Department of Surgery, London Health Sciences Centre, Western University, London, ON, Canada; patrick.luke@lhsc.on.ca

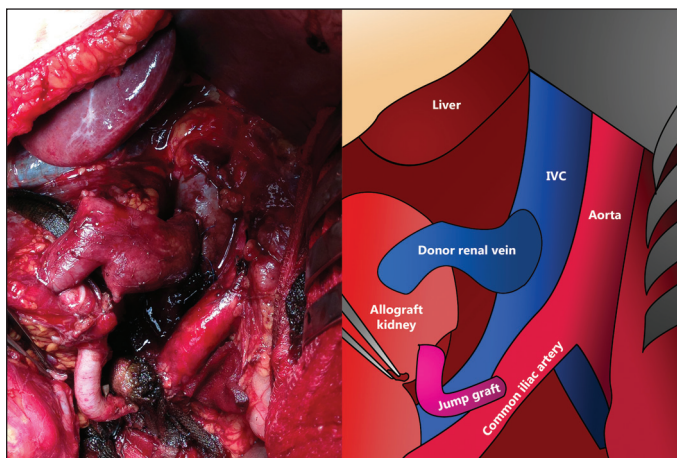


Fig. 2. Intraoperative photograph of Case 3 showing the arterial anastomosis of donor iliac artery jump graft to right common iliac artery, and venous anastomosis of renal allograft to native right renal vein (left) with labelled anatomical diagram (right).