

## Speculum-assisted approach for efficient open laparoscopic port access in the morbidly obese

Ryan McLarty; Andrew Rasmussen; Michael Hobart; Howard Evans

Division of Urology, University of Alberta, Edmonton, AB, Canada

**Cite as:** *Can Urol Assoc J* 2018 August 30; Epub ahead of print.

<http://dx.doi.org/10.5489/cuaj.5443>

**Published online August 30, 2018**

\*\*\*

### Introduction

Transperitoneal laparoscopic and robotic minimally invasive techniques for the management of renal cell carcinoma (RCC) are widely utilized. Despite familiarity with entry techniques, intraoperative adverse events attributed to the initial entry into the abdomen do occur. Open entry methods (Hasson technique) remain commonly used in community and academic settings owing to the confidence of avoiding and recognizing major adverse events (2). Obesity, defined as a body mass index of greater than 30 kg/m<sup>2</sup>, provides a technical challenge to gaining efficient open entry. Laparoscopic nephrectomy has been shown to be safe in obese populations with an acceptable complication profile but longer operative times (3). It is not uncommon at our center to operate on patients with a BMI of 40 kg/m<sup>2</sup> or greater. We describe the use of a traditional vaginal speculum to aid in gaining efficient initial open access in the obese patient that can be done by a single operator.

### Methods

Materials used for open access in the obese include electrocautery, pediatric vaginal speculum (Fig. 1), Kochers, Vicryl stay suture, and 12mm laparoscopic port. A skin incision is made down through subcutaneous fat, down to anterior rectus sheath and further bluntly dissected with a vaginal speculum which is positioned and locked into place to provide exposure (Figs.1, 2). The fascia can be easily excised, grasped with Kochers, and a Vicryl stay suture placed at the level of fascia for standard port placement. Alternatively, a balloon access port can be applied with ease as well (picture not shown). The speculum can then be used to spread muscle, expose the posterior layer of fascia and gain entry for initial port placement. This can be done without the use of an assistant and manipulation of handheld retractors.

**Discussion**

This technique can be utilized in obese patients undergoing laparoscopic or robotic radical or partial nephrectomy using an open-entry method of initial port placement. While we primarily utilize this on patients in the flank position, this can be applied to initial port placement in any transperitoneal or extraperitoneal laparoscopic case. The pediatric vaginal speculum is widely available, low cost, easily manipulated and locked with one hand, and can be utilized by a single practitioner. Furthermore it aids in the dissection of significant subcutaneous fat aiding exposure of both anterior and posterior rectus sheath layers without the use of separate retractors.

Alternatively, for obese patients, Veress needle entry may prove to be an efficient method of entry to avoid tedious dissection. A recent Cochrane systematic review of randomized controlled trials comparing different access techniques found the use of a Veress Needle was associated with an increased incidence of failed entry, extraperitoneal insufflation but a lack of significant difference in terms of major vascular and visceral injury (4). The choice of approach is based both upon experience with initial training and preference, and many surgeons may continue with an open-access approach for the aforementioned benefits.

The only other report of an assisting speculum device was by Adshead and colleagues in 2007. They published a method of using a Killian nasal speculum for all of their initial port entries describing quick entry with a single surgeon and useful in obese populations (5). In our experience, the pediatric vaginal speculum provides more visualization of the fascia layers due to its wider blades and better retraction of subcutaneous fat in the obese population.

**Conclusion**

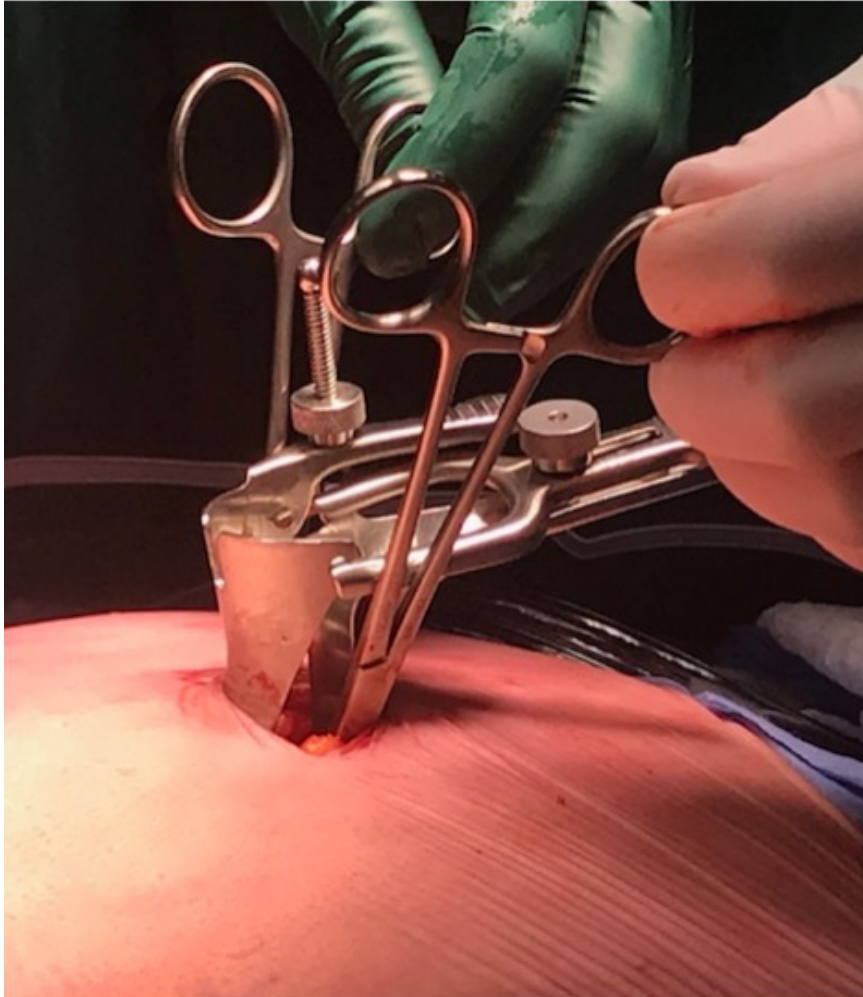
We describe a pediatric vaginal speculum assisted method of initial laparoscopic port placement using an open Hasson entry method in obese patients. This technique has been used 10 times to place the initial camera port in our obese (BMI range 40-51 kg/m<sup>2</sup>) laparoscopic radical and robot-assisted partial nephrectomy population with no complications related to port placement. Our initial experience is that this technique provides quick, safe access accomplished by one surgeon compared to standard open-access techniques.

## References

1. Ordon M, Eichel L, Landman J. Chapter 10: Fundamentals of and Robotic Urologic Surgery. *Campbell-Walsh Urology 11e* 2016, 195-224.
2. Hasson, HM. Open laparoscopy. *Biomed Bull* 1984;5: 1-6.
3. Nicolas Arfi, Arnaud Baldini, Myriam Decaussin-Petrucci, et al. Impact of Obesity on Complications of Laparoscopic Simple or Radical Nephrectomy. *Curr Urol* 2015 Sep; 8(3): 149–155.
4. Ahmad G, Gent D, Henderson D, et al. Laparoscopic entry techniques. *Cochrane Database Syst Rev* 2015;8: CD006583.
5. Adshead J, Hanbury DH, Boustead GB, et al. Novel method for Open-Access laparoscopic port insertion using the Killian nasal speculum: The lister technique. *J Endourol* 2007;22(2): 317-19.

**Figures and Tables**

*Fig. 1.* Pediatric vaginal speculum retracting subcutaneous fat. Kochers placed on anterior fascia prior to suture placement from outside the speculum.



*Fig. 2.* Superior view of speculum and working channel.

