

Case — Azoospermia with bilateral varicocele and normal follicle-stimulating hormone

John Michael Masterson, MD; Ranjith Ramasamy, MD

Department of Urology, University of Miami Miller School of Medicine, Miami, FL, United States

Cite as: *Can Urol Assoc J* 2018;12(11):E486-8. <http://dx.doi.org/10.5489/cuaj.5298>

Published online June 8, 2018

Introduction

Azoospermia affects approximately 15% of infertile men and can be caused by obstructive azoospermia (OA) or non-obstructive azoospermia (NOA).¹ Azoospermia can also be caused by ejaculatory dysfunction, such as retrograde ejaculation or anejaculation, which fall outside the realm of OA or NOA. OA accounts for approximately 40% of cases of azoospermia and is caused by anatomical obstruction of the extratesticular ductal system anywhere between the rete testis and the ejaculatory ducts.² Physical blockages resulting in OA are most commonly due to prior vasectomy, but may also be caused by epididymal, vasal, or ejaculatory duct pathology secondary to genitourinary infection, iatrogenic injury during scrotal or inguinal surgical procedures, and congenital anomalies, such as congenital bilateral absence of the vas deferens (CBAVD).³ NOA on the other hand accounts for 60% of cases of azoospermia and is caused by either primary or secondary testicular failure and subsequent defective spermatogenesis.⁴ Varicocele is considered a correctable cause of NOA.⁵

Management of OA typically involves surgical treatment with the goal of returning sperm to the ejaculate. Microsurgical reconstruction techniques for OA include vasovasostomy (VV), vasoepididymostomy (VE), and transurethral resection of the ejaculatory duct (TURED).⁶ VV is 57%-96% successful depending on the type of procedure while VE is 78% successful.⁶ If reconstruction is not possible, as in the case of CBAVD, microsurgical aspiration of epididymal sperm for assisted reproductive techniques (ART) is an option. Approximately 10% of men with NOA will have sperm in the ejaculate upon subsequent testing, however, for the remaining 90%, management of NOA almost always involves ART in the form of microdissection testicular sperm

extraction (mTESE) in combination with in vitro fertilization/ intracytoplasmic sperm injection (IVF/ICSI), as return of sperm to the ejaculate is less likely overall in NOA.⁴ mTESE carries an overall success rate of 52%.⁷ For men with NOA and varicocele, varicocele repair is a possible solution, with reported success rates of 39% for return of sperm to the ejaculate and 11.3–54.5% for mTESE sperm retrieval depending on underlying histology.⁸ Given the considerable differences in etiology and management strategies between OA and NOA, accurate diagnosis of these conditions is important.

Per current American Urological Association (AUA) and Canadian Urological Association (CUA) guidelines, the initial evaluation of an azoospermic patient should include a full medical history, physical examination, and measurement of serum testosterone and follicle-stimulating hormone (FSH) levels.^{5,9} Relevant historical factors in the evaluation of azoospermia are listed in Table 1.⁵ Positive physical exam findings for men with OA include large testis (the normal adult testicle should be approximately 15–20 cc), enlarged or indurated epididymis, epididymal cysts, abnormal digital rectal exam (DRE), or absence of the vas deferens.¹⁰ Positive physical exam findings suggestive of NOA include small testis (less than 15 ml), flat epididymis, or varicocele without evidence of obstruction.¹¹ Unfortunately, there can be overlap in physical exam findings among men with azoospermia.

Measurement of FSH and testis volume is extremely useful in the evaluation of azoospermia. In 2002, Schoor et al found that 96% of cases of OA and 89% of cases of NOA could be diagnosed based on these parameters alone, with OA having normal FSH and testis volume and NOA having elevated FSH and low testis volume.¹² These findings are reflected in current guidelines on the evaluation of azoospermia and have greatly reduced the need for testicular biopsy in the evaluation of azoospermia.^{5,9} The purpose of this case report is to discuss a diagnostically challenging presentation of azoospermia in the context of current recommendations and to propose a situation-specific treatment algorithm to aid in the management of azoospermia and varicocele.

Table 1. Relevant medical history in the evaluation of azoospermia

Prior fertility
Childhood illnesses, such as viral orchitis or cryptorchidism
Genital trauma or prior pelvic or inguinal surgery
Infections, such as epididymitis or urethritis
Gonadotoxin exposures, such as prior radiation therapy/chemotherapy
Recent fever or heat exposure
Current medications
Family history of birth defects
Mental retardation
Reproductive failure
Cystic fibrosis

Case report

We present the case of a 43-year-old male who presented to a tertiary academic urology clinic for evaluation of primary infertility. Semen analysis demonstrated azoospermia with normal ejaculate volume and pH, laboratory studies showed FSH 7.7 mIU/mL (normal 1.6–8.0), luteinizing hormone (LH) 5.3 mIU/mL (reference range 1.5–9.3), T 616 ng/dL (reference range 150–1100). History revealed no prior fertility and no risk factors for azoospermia listed in Table 1. Physical exam revealed 12 cc testicles (normal 15–20), palpable vasa deferentia bilaterally, flat epididymis bilaterally, and bilateral grade II varicoceles. Genetic testing showed karyotype 46XY. Assessment favoured NOA secondary to bilateral varicoceles, given azoospermia in the presence of low testis volume and varicocele. However, the presence of a high-normal serum FSH made the diagnosis less certain. The plan was to repair both varicoceles and perform

simultaneous intraoperative testis biopsy via open excision for prognostic purposes. The bilateral varicoceles were successfully repaired, however, biopsy specimen ultimately revealed normal spermatogenesis (100% of tubules with mature sperm), favouring OA (Fig. 1).

Repeat semen analysis at three months re-demonstrated normal ejaculate volume, pH, and azoospermia. Upon reassessment, it was determined that the best course of action was to perform surgical reconstruction six months after varicocele repair. No sperm was visualized in the vas fluid on intraoperative microscopy and scarred, flat epididymal tubules without sperm were encountered on one side, ultimately leading to a crossed VE in which the vas deferens was anastomosed to the head of the contralateral epididymis. One-year followup after crossed VE showed persistent azoospermia with plan for sperm retrieval.

Discussion

FSH and testis volume are of tremendous diagnostic value in cases of azoospermia and can correctly diagnose 96% of cases of OA without the need for testicular biopsy.¹² However, we believe that our case falls within the 4% of cases of OA for which FSH and testis volume alone were insufficient to make an accurate diagnosis. Testis volume below 15 cc in our patient favoured NOA, while normal range FSH favoured neither OA nor NOA. Our case was further complicated by the presence of bilateral varicoceles, favouring a diagnosis of NOA. Current guidelines in both the U.S. and Canada call for diagnostic testicular biopsy for patients with normal testicular size, at least one palpable vas deferens, and a normal serum FSH level.^{5,9} Our patient fit only one of these criteria, normal FSH, and lacked any obvious source of obstruction on history and physical exam. Varicocele is a known cause of NOA and varicocele repair has been shown to return sperm to the ejaculate or improve sperm retrieval outcomes in men with NOA and varicocele.⁸ Given the low suspicion of obstruction in our patient and the combined findings of low testis volume, bilateral varicoceles, and normal FSH, varicocele repair was a reasonable therapeutic step for presumed NOA. However, once obstruction was confirmed via biopsy taken at the time of varicocele repair, management of OA in a patient status-post bilateral varicocele repair became more challenging. In a 2013 paper, Herrel et al detail the challenges presented by varicocele when planning for surgical repair of OA.¹³ The authors state that performing both procedures simultaneously could result in poor venous return and testis atrophy or loss, as varicolectomy ligates all venous return from the testis with the exception of the vasal veins. When a vasectomy is performed, preservation of some venous return must be maintained during varicolectomy, such as the cremasteric veins. Ideally, the vasectomy reversal is completed approximately six months or more prior to varicolectomy.¹³ It should

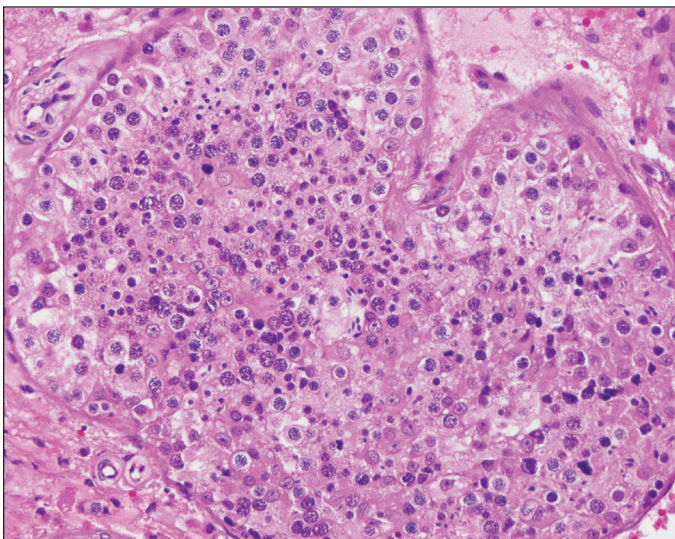


Fig. 1. Normal spermatogenesis found on intraoperative testis biopsy during bilateral varicocele repair.

be noted that in a case series of 10 patients, vasal reconstruction and microsurgical varicocele repair were performed simultaneously. None of these 10 patients showed postoperative testicular atrophy, however, the authors endorsed this combined procedure only for the most experienced microsurgeons.¹⁴ Ultimately, the decision to perform crossed VE six months after varicocele repair in our patient was reached due to persistent azoospermia and to allow the formation of collateral venous drainage from the testes.

Conclusion

We believe that this case is important to discuss because it represents a diagnostically challenging presentation of azoospermia. We also present a management algorithm designed specifically for cases of azoospermia and varicocele with particular attention paid to cases with normal FSH (Fig. 2). Our hope is that practitioners will approach these cases with caution and err towards histological diagnosis of NOA prior to proceeding with varicocele repair in order to avoid a more complicated surgical repair of OA.

Competing interests: The authors report no competing personal or financial interests.

This paper has been peer-reviewed.

References

1. Jarow JP, Espeland MA, Lipshultz LI. Evaluation of the azoospermic patient. *J Urol* 1989;142:62-5. [https://doi.org/10.1016/S0022-5347\(17\)38662-7](https://doi.org/10.1016/S0022-5347(17)38662-7)
2. Jow W. Motile sperm in human testis biopsy specimens. *J Androl* 1993;14:194-8.
3. Practice Committee of the American Society for Reproductive Medicine in collaboration with the Society for Male Reproduction and Urology. The management of infertility due to obstructive azoospermia. *Fertil Steril* 2008;90:121-4. <https://doi.org/10.1016/j.fertnstert.2008.08.096>
4. Wosnitzer M, Goldstein M, Hardy MP. Review of azoospermia. *Spermatogenesis* 2014;4:e28218. <https://doi.org/10.4161/spmg.28218>
5. Jarow J, Sigman M, Kolettis PN, et al. The optimal evaluation of the infertile male: AUA best practice statement. *AUA Best Pract Statement* 2011:39.

6. Schrepferman CG, Carson MR, Sparks AET, et al. Need for sperm retrieval and cryopreservation at vasectomy reversal. *J Urol* 2001;166:1787-9. [https://doi.org/10.1016/S0022-5347\(05\)65676-5](https://doi.org/10.1016/S0022-5347(05)65676-5)
7. Bernie AM, Mata DA, Ramasamy R, et al. Comparison of microdissection testicular sperm extraction, conventional testicular sperm extraction, and testicular sperm aspiration for non-obstructive azoospermia: A systematic review and meta-analysis. *Fertil Steril* 2015;104:1099-103.e1-3. <https://doi.org/10.1016/j.fertnstert.2015.07.1136>
8. Weedin JW, Khara M, Lipshultz LI. Varicocele repair in patients with non-obstructive azoospermia: A meta-analysis. *J Urol* 2010;183:2309-15. <https://doi.org/10.1016/j.juro.2010.02.012>
9. Jarvi K, Lo K, Grober E, et al. CUA guideline: The workup and management of azoospermic males. *Can Urol Assoc J* 2015;9:229-35. <https://doi.org/10.5489/cuaj.3209>
10. Gudeloglu A, Parekattil SJ. Update in the evaluation of the azoospermic male. *Clinics (Sao Paulo)* 2013;68Suppl 1:27-34. [https://doi.org/10.6061/clinics/2013\(Sup01\)04](https://doi.org/10.6061/clinics/2013(Sup01)04)
11. Chiba K, Enatsu N, Fujisawa M. Management of non-obstructive azoospermia. *Reprod Med Biol* 2016;15:165-73. <https://doi.org/10.1007/s12522-016-0234-z>
12. Schoor RA, Elhanbly S, Niederberger CS, et al. The role of testicular biopsy in the modern management of male infertility. *J Urol* 2002;167:197-200. [https://doi.org/10.1016/S0022-5347\(05\)65411-0](https://doi.org/10.1016/S0022-5347(05)65411-0)
13. Herrel L, Hsiao W. Microsurgical vasovasostomy. *Asian J Androl* 2013;15:44-8. <https://doi.org/10.1038/oja.2012.79>
14. Mulhall JP, Stokes S, Andrawis R, et al. Simultaneous microsurgical vasal reconstruction and varicocele ligation: Safety profile and outcomes. *Urology* 1997;50:438-42. [https://doi.org/10.1016/S0090-4295\(97\)00290-2](https://doi.org/10.1016/S0090-4295(97)00290-2)

Correspondence: Dr. John Michael Masterson, Department of Urology, University of Miami Miller School of Medicine, Miami, FL, United States; jmm557@med.miami.edu

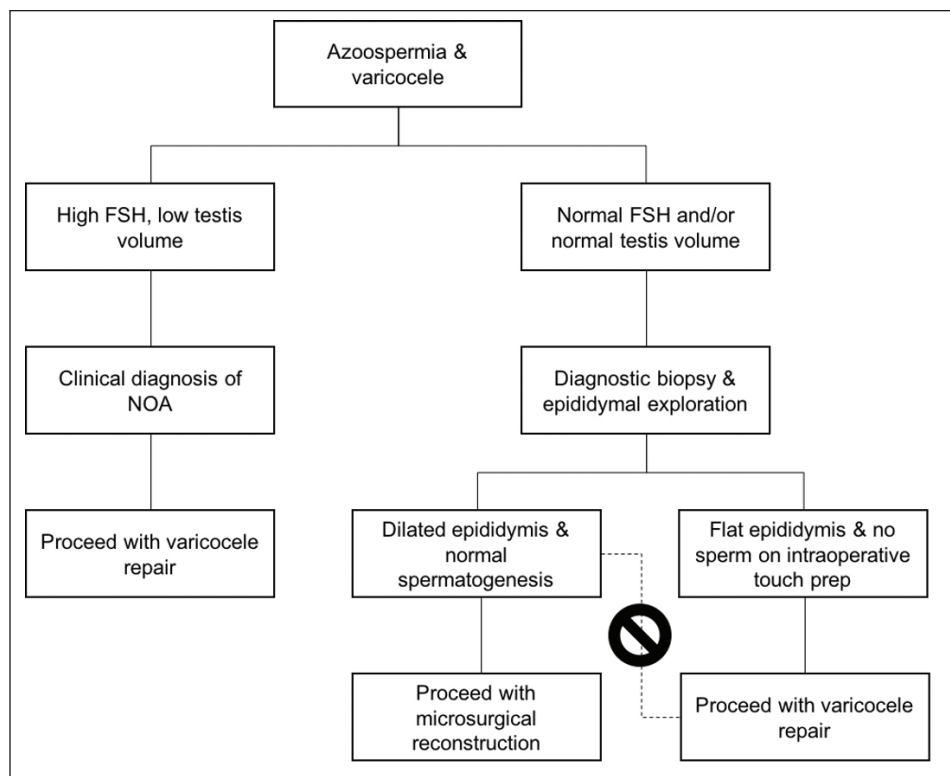


Fig. 2. Non-obstructive etiology of etiology should be confirmed via diagnostic biopsy in patients with azoospermia, varicocele, and normal follicle-stimulating hormone (FSH) and testis volume prior to varicocele repair. Varicocele repair should not be performed in patients with histological evidence of obstructive azoospermia (OA) found on diagnostic biopsy.