

Testosterone deficiency syndrome and prostate cancer: illustrative annotations for a debate

Alvaro Morales, MD; Angela Black, RN, CCRP

See related article on page 43

CUAJ 2008;2(1):52-4

As illustrated in this issue of the *CUAJ*,¹ the use of testosterone in elderly men diagnosed with testosterone deficiency syndrome (TDS), or hypogonadism, remains controversial. Perhaps the most contentious point refers to the effect of supplemental testosterone on prostate health. In the last few years, small studies appear to indicate that in men treated successfully for prostate cancer and TDS, testosterone treatment is warranted, usually successful and largely free of serious adverse effects.^{2,3} To complement some of the points raised, we present a case that typifies the situation and strengthens some of the opinions expressed in the Point / Counterpoint section of this issue.¹

Illustrative report

A 71-year-old man was referred for "management of impotence." He was diagnosed with a T2a, Gleason score 6, prostate specific antigen (PSA) 28 ng/mL, adenocarcinoma of the prostate 4 years earlier. He was treated with 4500 cGy in 25 fractions to the pelvis, followed by 2000 cGy in 10 fractions to the prostate alone. He also received quarterly treatments with goserelin for 3 years. At our initial assessment, 14 months after discontinuation of the goserelin, in addition to erectile dysfunction he complained of poor sexual desire, decreased energy and muscle strength, and hot flashes. His testicles were very small. A hormonal screen showed a total serum testosterone of 1.1 nmol/L (normal 10–28 nmol/L). His bio-available testosterone was 0.73 nmol/L (normal 2–8.6 nmol/L) and there was marked elevation of gonadotropins. His PSA was < 0.01 ng/mL. The option of receiving testosterone treatment was explained in detail to the patient and his wife; we emphasized the potential risks in light of his past history of adenocarcinoma of the prostate. His symptoms were sufficiently disabling that he opted to be treated and chose oral testosterone undecanoate and committed to strict monitoring. On his first return visit he reported feeling much more energetic, no more hot flashes and an improvement in his sex life, including 1 episode of priapism. However, he remained mildly hypogonadal (testosterone treatment 8.6) and his PSA had increased to 0.1 ng/mL. The couple wished to continue the testosterone treatment. Six months later, the patient's PSA had increased to 0.47 ng/mL and he was advised to discontinue further testosterone treatment. This resulted in a decrease in PSA level, a recurrence of his symptoms and the couple's wish to reinstitute testosterone therapy. The changes in the patient's testosterone and PSA levels are illustrated in Figure 1. The

patient remained well. Forty-eight months after the initiation of testosterone treatment, the patient noticed right neck and shoulder pain. A few weeks later, he developed right lateral forearm numbness, right-sided body weakness and gait disturbance, saddle anesthesia, urinary incontinence and diminished rectal tone. An MRI showed a hemorrhagic epidural mass lesion at levels C6-T5, L2-S1 and multiple lung nodules. Debulking laminectomy was performed and the histology confirmed carcinoma of unknown origin. The patient passed away 2 weeks later. An autopsy revealed a poorly differentiated carcinoma in his lung with extensive bronchovascular and plural spread, and lymphangitic spread with involvement of the hilar lymph nodes. His prostate was small and had no evidence of residual tumour. The pathologist concluded that despite the patient's history of prostate cancer, the distribution of tumour load predominantly in the upper spine and the lungs while sparing the prostate is not consistent with prostatic carcinoma. In addition, the histological features of the tumour match those of the recently debulked tumour in the spine, which also did not support a primary prostatic cancer as the source of metastatic disease. Death was attributed to respiratory failure secondary to pulmonary involvement by disseminated metastatic carcinoma, most likely from a lung primary.

Discussion

This unique case exemplifies what might be observed clinically but is usually overlooked among the generalities and statistics reported in the increasing number of small studies documenting the safety of using

testosterone treatment in men with a remote history of adenocarcinoma of the prostate.²⁻⁴

The first lesson, that what appeared to be the rare but alarming situation of a prostate adenocarcinoma progressing out of control under the powerful influence of supplemental testosterone in the absence of alterations of the gland on rectal examination or increasing PSA levels, proved to be erroneous. It also gives reassurance and restates the consensus recommendations on testosterone treatment with regard to prostate safety, which read:

Men successfully treated for adenocarcinoma of the prostate and suffering from symptomatic hypogonadism may become candidates for androgen therapy ... if there is no evidence of residual cancer. The risks and benefits must be clearly understood by the patient and the follow-up must be particularly careful. No reliable evidence exists in favor or against this recommendation. The clinician must exercise good clinical judgment together with adequate knowledge of the advantages and drawbacks of androgen therapy in this situation.⁵

Evidently, the recommendation was followed to the letter in this patient. The PSA values were a good indicator of prostate health and the mild increases following testosterone treatment were presumed to simply be related to stimulation of residual benign rather than malignant prostate tissue; a view supported by the lack of changes in the prostate as determined by digital rectal examination and the histological findings of the necropsy. The importance of close follow-up to determine a detrimental effect is paramount since the safety of testosterone treatment in these patients remains unproven. The few papers mentioned above²⁻⁴ are underpowered and have short follow-up. Although the available evidence is reassuring, a great deal of prudence should be exercised and the literature interpreted with caution.⁶

Our experience raises additional issues. How soon after definitive treatment for prostate adenocarcinoma can testosterone treatment be initiated in hypogonadal men? It is our view that in patients who undergo radical prostatectomy, testosterone treatment can be considered as soon as the PSA is no longer detectable. For those treated with external beam radiation, brachytherapy or cryotherapy, the situation is somewhat more complicated since the PSA may remain detectable. It seems to us that testosterone treatment in these

men can be considered once the PSA nadir has been reached.

In this respect, a frequently neglected finding, documented by less than a handful of studies, is that the prostate does not appear to be exclusively a target organ within the endocrine system. Our own observations and those of a few investigators⁷ (G.W. Yu, hormonal levels following brachytherapy for prostate cancer, unpublished data, October 2007) have documented significant changes, including an increase in gonadotropins and androgen levels following definitive treatment for prostate adenocarcinoma. If this is so, what is the basis on which to refuse those with TDS supplemental treatment to bring serum testosterone levels within the normal range? In the same vein, there are early but convincing studies showing that serum testosterone levels after testosterone treatment are a poor reflection of testosterone and testosterone-reduced intraprostatic values.⁸ They also show that about 30% of intraprostatic testosterone and dehydrotestosterone are maintained following castration.⁹

Is it appropriate to wait for a potential recovery of testicular function in men who were treated with androgen deprivation and radiotherapy? The evidence is that for those in whom a recovery occurs, it takes a long time (median 2.3 yr).¹⁰ It should be noted that in Wilke and colleagues' study the "normal" testosterone levels were defined as > 8 nmol/L and the majority of men

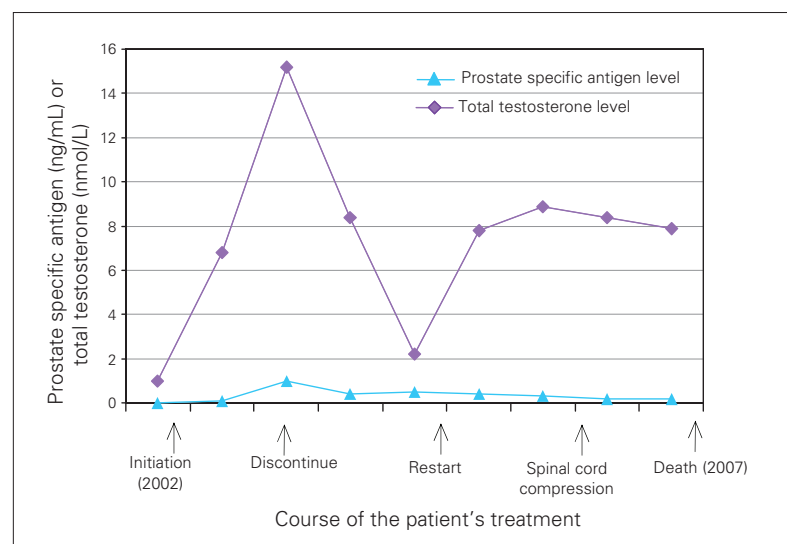


Fig. 1: Changes in the levels of serum prostate specific antigen and testosterone following the onset of testosterone treatment.

did not reach this value, which is widely considered a marker of significant hypogonadism. And if the hope is that serum testosterone will eventually reach an acceptable level, is the delay justified?

Although a rare occurrence, it is known that poorly differentiated prostate adenocarcinoma may produce misleading small amounts of PSA. Based on this experience, we have modified our follow-up plan of this population by introducing mandatory yearly bone scans, regardless of PSA readings. We have no other reason for this other than the scare that this particular case brought on. Nevertheless, the bone scan adds a sense of increased security for early detection of tumour recurrence in the event that the PSA values are inaccurate.

It should be reiterated in the strongest terms that testosterone treatment for patients successfully treated for prostate adenocarcinoma must be reserved for those instances in which both the clinical and laboratory diagnoses have been made and in which the testosterone deficiency brings upon a significant diminution in the patient's quality of life. In addition, a failure to experience a symptomatic improvement after 3 months of adequate testosterone treatment demands careful reassessment not only to rule out comorbidities but also to assess whether therapy should be discontinued. The role of the testosterone and androgen receptors in prostate health is a relevant but incomplete story. It would be simplistic to postulate that specific levels of testosterone alone need to be considered when treating men with testosterone deficiency after definitive treatment for prostate cancer. There are large interindividual differences in these levels¹¹ as well as in the tissue sensitivities to androgens. The differences are in part owing to laboratory techniques, but true serum and tissue differences have been clearly recognized. A recent report has documented that these differences exist with a contributory role of the polymorphic glutamine tract in the androgen receptor encoded by the CAG repeat polymorphism in exon 1 of the

androgen receptor gene.¹² Despite the role of hormones in prostate health, we are all aware that factors related to lifestyle and diet as well as inherited susceptibility genes all participate in the development of prostate cancer. What role they play in men already treated for the condition remains to be determined.

From the Centre for Applied Urological Research and the Department of Urology, Queen's University and General Hospital, Kingston, Ont.

This article has been peer reviewed.

Competing interests: None declared.

References

- Morales A. The use of hormonal therapy in "andropause": the pro side. *CUAJ* 2008; 2:43-6.
- Kaufman JM, Graydon RJ. Androgen replacement after curative radical prostatectomy for prostate cancer in hypogonadal men. *J Urol* 2004;172:920-2.
- Sarosdy MF. Testosterone replacement for hypogonadism after treatment of early prostate cancer with brachytherapy. *Cancer* 2007;109:536-41.
- Agarwal PK, Oefelin MG. Testosterone replacement therapy after primary treatment for prostate cancer. *J Urol* 2005;173:533-6.
- Morales A, Morley J, Heaton JPW. Androgen deficiency in the aging male. In: Wein AJ, L'Cavoussy LR, editors. *Campbell-Walsh urology*. 9th ed. Philadelphia (PA): Saunders Elsevier; 2007. p 850-62.
- Morgentaler A. Testosterone and prostate cancer: an historical perspective on a modern myth. *Eur Urol* 2006;50:935-9.
- Miller LR, Partin AW, Chan DW, et al. Influence of radical prostatectomy on serum hormone levels. *J Urol* 1998;160:449-53.
- Marks LS, Mazer NA, Mostaghel E, et al. Effect of testosterone replacement therapy on prostate tissue in men with late onset hypogonadism. *JAMA* 2006;296:2351-61.
- Page ST, Lin DW, Mostaghel E, et al. Persistent intraprostatic androgen concentrations after medical castration in healthy men. *J Clin Endocrinol Metab* 2006;91:3850-6.
- Wilke DR, Parker C, Adonowski D, et al. Testosterone and erectile function recovery after radiotherapy and long-term androgen deprivation with LH-RH antagonists. *BJU Int* 2006;97:963-8.
- Morley JE, Kaiser FE, Perry HM III, et al. Longitudinal changes in testosterone, luteinizing hormone and follicle stimulating hormone in healthy old men. *Metabolism* 1997; 46:410-3.
- Crabbe P, Bogaert V, De Becquer D, et al. Part of the interindividual variation in serum testosterone levels in healthy men reflects differences in androgen sensitivity and feedback set point: contribution of the androgen receptor polyglutamine tract polymorphism. *J Clin Endocrinol Metab* 2007;92:3604-10.

Correspondence: Dr. A. Morales, Centre for Applied Urological Research, 62 Barrie St., Kingston ON K7L 3J7; moralesa@queensu.ca