

Utility of magnetic resonance urography in pediatric urinary incontinence: Radiological considerations

Ahmad Mousa, BSc^{1,2}; Jessica Ming, MD^{1,2}; Michelle Lightfoot, MD^{3,4}; Andrew Kirsch, MD^{3,4}; Walid Farhat, MD^{1,2}

¹Hospital for Sick Children, Toronto, ON, Canada; ²University of Toronto, Toronto, ON, Canada; ³Children's Healthcare of Atlanta, Atlanta, GA, United States; Emory University, Atlanta, GA, United States

Cite as: *Can Urol Assoc J* 2018 March 19; Epub ahead of print.

<http://dx.doi.org/10.5489/cuaj.4936>

Published online March 19, 2018

Introduction

A study of children in the United States revealed that the incidence of enuresis at age 11 was approximately 7%¹. Primary enuresis can be caused by various diseases including developmental delay and congenital structural abnormalities. One congenital cause is the ectopic ureter, which is 2-12 times more common in females than males². In females, the ureter abnormally inserting distal to the bladder neck causes continuous urinary incontinence. Insertion sites may include, but are not limited to: the urethra, vagina, uterus or rectum.

The evaluation of urogenital conditions (including incontinence) in the pediatric population has traditionally included imaging techniques such as ultrasonography (US), intravenous urography (IVU), voiding cystourethrography (VCUG) and radionuclide scintigraphy (DMSA)³. The anatomical details provided by these techniques individually are insufficient for the formation of an accurate clinical diagnosis⁴. Magnetic resonance urography (MRU) provides more accurate anatomic and functional assessment of the urinary tract⁵. In the following case report, we discuss the delayed diagnosis and treatment of both ectopic kidney and ureter in a young female patient.

Case report

Case 1

A 12-year-old female with history of right renal agenesis and primary mixed enuresis was referred to our clinic. She was seen previously by urology years before at another institution and had multiple investigations including uroflowmetry, renal US and VCUGs, all of which revealed a normal left and dysplastic right kidney. At time of re-presentation, the patient described round-the-clock low-volume incontinence that never resolved after toilet training. She is otherwise healthy, meeting all developmental milestones. Physical exam was unremarkable.

Case 2

A 9-year-old female with history of left renal agenesis and primary mixed enuresis was referred to pediatric urology clinic. At time of presentation, the patient described continuous low-volume urinary incontinence. She is otherwise healthy, meeting all developmental milestones. Physical exam was unremarkable. MRI spine and renal/bladder ultrasound revealed absent left kidney, normal right kidney.

After clinical evaluation, both patients underwent MRU for accurate exploration of urinary tract anatomy. T1- and T2- weighted images were obtained in the coronal, sagittal, and axial planes.

Results*Case 1*

MRU revealed a right ectopic, renal remnant located in the right lower abdominal quadrant (5 cm in length) [Fig. 1A]. A single ectopic ureter draining the right kidney inserted into the vagina [Fig. 1B]. The left kidney (12 cm in length) had compensatory hypertrophy with normal function on MRU. The patient underwent a robotic right nephroureterectomy and was completely continent the next day.

Case 2

MRU revealed a left ectopic, renal remnant (2cm in length) [Fig. 2A] located in the lower left abdominal quadrant near the left internal iliac artery. A single ectopic ureter draining the renal remnant inserted into the vagina [Fig. 2B]. The right kidney (13cm in length) appeared normal on MRU. The patient underwent robotic left nephroureterectomy and achieved complete continence. Rapid frozen section confirmed renal tissue.

Discussion

Continuous day and nighttime wetting is a condition caused by a spectrum of abnormalities in the urogenital tract. The work-up of patients presenting with enuresis involves careful history taking, physical examination, laboratory testing, and imaging. Currently, the radiographic evaluation of the urinary tract in enuresis can involve ultrasonography, intravenous urography, cystourethography, and CT urography. Neurologic imaging (commonly MRI spine) is reserved in children with suspected and/or observed neurological abnormalities in the lower lumbosacral spine⁶.

Despite some limitations, the expanded use of MRU in urology and nephrology has gained acceptance as a valuable diagnostic tool^{7,8,9,10}. Considerations when utilizing MRU include the potential requirements for sedation and contrast medium. Intravenous contrast-enhanced T1-weighted images are usually applied in an integrative fashion to complement the non-enhanced T2-weighted sequences. However, recent studies suggest that non-contrast T2-weighted MR urography alone is sufficient to diagnose an ectopic ureter and help direct clinical management¹¹. The utilization of sedation is entirely dependent on child maturity and

compliance. Generally, children under the age of seven are most likely to require sedation. With improvements in technology, the cost and examination time (currently about one hour) associated with MRU continue to decrease.

As exemplified in these cases, MRU provides advantages in the accurate identification of anatomic abnormalities in the urinary tract, particularly ectopic ureters. Intravenous urography (IVU) is not utilized as often in present day practice as three-dimensional imaging modalities have improved. Although CT urography may provide comparable anatomic accuracy and resolution to MRU with a shorter scanning time, it guarantees radiation exposure which is unfavourable in pediatric populations. MRU allows for three dimensional, non-invasive, and radiation-free imaging of the urinary tract with high accuracy and resolution, highlighting why it should be the imaging modality of choice for pediatric anatomical urinary tract abnormalities^{7,11}.

Conclusions

The presented cases confirm the utility of MRU in the evaluation and subsequent surgical management of ectopic kidneys and ureters in incontinent, toilet-trained girls. More specifically, when the ectopic ureter does not insert into the urinary tract, the abnormalities may not be detected if MRU is not utilized. With technological advancements and increased availability, we anticipate that MRU may become the primary imaging modality for the anatomical assessment of the urinary tract.

References

1. Byrd RS, Wietzman M, Lanphear NE et al (1996) Bed-wetting in US children: epidemiology and related behaviour problems. *Pediatrics* 98: 414-419
2. Avni EF, Matos C, Rypens F, Schulman CC. Ectopic vaginal insertion of an upper pole ureter: demonstration by special sequences of magnetic resonance imaging. *J Urol*. 1997;158:1931–1932.
3. Ehammer T, Riccabona M, Maier E (2011) High resolution of MR for evaluation of lower urogenital tract malformations in infants and children: feasibility and preliminary experiences. *Eur J Radiol* 78: 388–393
4. Tekgül S, Nijman JM, Hoebeke P et al (2015) EAU guidelines on paediatric urology 2015: dilatation of the upper urinary tract. European Society for Paediatric Urology. <http://uroweb.org/guideline/paediatric-urology/>. Accessed 30 March 2015
5. Baughman SM, Richardson RR, Podberesky DJ et al (2007) 3- dimensional magnetic resonance genitography: a different look at cloacal malformations. *J Urol* 178:1675–1679
6. Pippi Salle JL, Capolichhio G, Housle AM et al (1998) Magnetic resonance imaging in children with voiding dysfunction: is it indicated? *J Urol* 160:1080-1083
7. Wille S, von Knobloch R, Klose KJ et al (2003) Magnetic resonance urography in pediatric urology. *Scand J Urol Nephrol* 37:16– 21
8. Cerwinka WH, Grattan-Smith JD, Kirsh AJ (2008) Magnetic resonance urography in pediatric urology. *J Pediatr Urol* 4:74–83
9. Dickerson EC, Dillman JR, Smith EA et al (2015) Pediatric MR urography: indications, techniques, and approach to review. *Radiographics* 35:1208–1230
10. Darge K, Anupindi SA, Jaramillo D (2011) MR imaging of the abdomen and pelvis in infants, children and adolescents. *Radiology* 261:12–29
11. Figueroa VH, Chavhan GB, Oudjhane K et al (2013) Utility of MR urography in children suspected of having ectopic ureter. *Pediatr Radiol* 44:956–962

Figures and Tables

Fig. 1. (A) Magnetic resonance urography (MRU) in coronal plane revealing right renal remnant; (B) MRU in sagittal plane revealing right ectopic ureter inserting into vaginal wall.

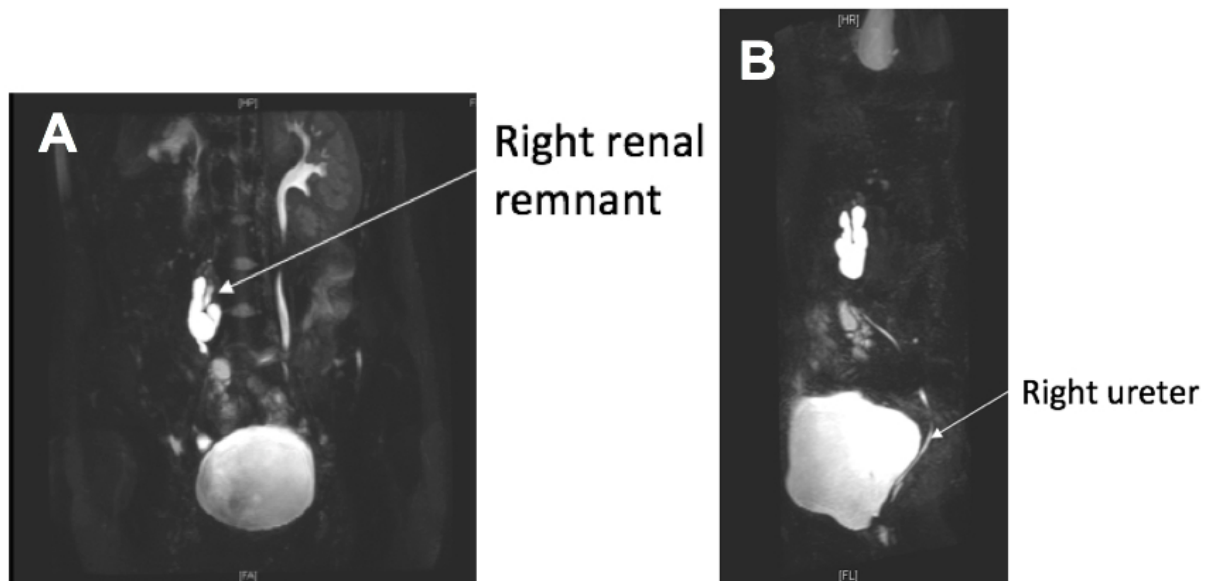


Fig. 2. (A) Magnetic resonance urography (MRU) in coronal plane revealing left renal remnant; (B) MRU in coronal plane revealing left ectopic ureter inserting into vaginal wall.

