

Do retroperitoneal extragonadal germ cell tumours exist?

Nahid Punjani, MD,* Eric Winqvist, MD, MSc, FRCPC, FACP;† Nicholas Power, MD, FRCSC*

*Division of Urology, London Health Sciences Centre, Western University, London, ON; †Division of Medical Oncology, London Health Sciences Centre, Western University, London, ON

See related article on page 385.

Cite as: *Can Urol Assoc J* 2015;9(11-12):381-4. <http://dx.doi.org/10.5489/cuaj.3024>
Published online December 14, 2015.

Abstract

Introduction: Extragenadal germ cell tumours (GCTs) have been described arising in midline structures. Although primary retroperitoneal extragonadal GCTs (RPGCTs) comprise 30% to 40% of these, their existence as a genuine disease has been questioned. Our study evaluated clinicopathological findings to examine this question in RPGCT patients at our centre.

Methods: Data from 414 men between 1980 and 2014 treated at London Health Sciences Centre with chemotherapy for testicular GCTs were reviewed retrospectively. Primary RPGCT was defined as pathologically diagnosed GCT with no evidence of GCT in the testes by physical exam or ultrasound. Patients thought to have primary RPGCT at the time of initial diagnosis were identified from an electronic database and data were extracted.

Results: In total, 18 men with a diagnosis of metastatic RPGCT were identified. Four were excluded due to ultrasound reports that were incomplete or suggested malignancy. The remaining 14 patients had negative or non-specific ultrasounds, and all received platinum-based combination chemotherapy. Ten patients (71%) underwent post-chemotherapy RP lymph node dissections; of those 8 (57%) who underwent orchiectomy, none had corresponding pathologically normal testicular tissue.

Conclusion: RPGCT patients present with more advanced disease stage. Our study sample size is limited, but the findings are consistent with existing literature suggesting that primary RPGCTs may not exist as a unique disease, but instead may represent metastatic disease from a clinically occult testicular primary. By corollary, viable malignant germ cells may be present in testes of patients with presumed primary RPGCT, and may persist as a site of residual malignant disease after chemotherapy.

Introduction

Extragenadal germ cell tumours (GCTs) are uncommon and typically arise from the pineal gland, mediastinum, sacrococcyx, or retroperitoneum, and rarely in the vagina, prostate, liver, gastrointestinal tract and orbits.¹⁻³ Primary retroperitoneal extragonadal GCTs (RPGCTs) account for 30% to 40% of extragonadal GCTs.⁴ The only cohort study investigating RPGCTs suggests that these may not represent a distinct clinical entity, but rather metastases from a clinically occult primary testicular tumour.^{1,5}

Some studies have suggested that RPGCTs and primary testicular tumours with retroperitoneal metastases are 2 entirely different diseases.⁶ However, treatment of presumed RPGCT is identical to that of testicular GCT, with the exception of the use of orchidectomy.^{4,7} If there remains uncertainty about the origin of RPGCTs and doubt regarding residual disease in the testicle, missed disease might remain in the testicle and serve as a source for recurrence and metastases.⁵

Based on the uncertainty and limited evidence available in the literature, we reviewed all presumed RPGCTs at our centre to investigate the evidence supporting RPGCT as a unique diagnostic entity. A clear understanding of this concept is important to optimize management and testicular preservation.

Methods

Men treated at London Health Sciences Centre between 1980 and 2014 for metastatic GCTs were identified from an electronic database and screened for a diagnosis of RPGCT. The site of origin for the primary tumour was recorded for all patients in the database, and patients with retroperitoneal primary tumour were identified with an electronic filter. To be eligible, patients had to have pathologically diagnosed GCT with metastatic disease and no evidence of tumour in the testes by physical exam or on ultrasonography. Patients were excluded if there was incomplete data or if their treat-

ing physician did not give them a diagnosis of RPGCT.

Demographic and clinical data, including IGCCCG (International Germ Cell Classification Collaborative Group) classification, treatment details, and clinical outcomes, were extracted from the database and original medical records as necessary. Individual pathology from orchiectomy and retroperitoneal lymph node dissection procedures were recorded. Orchiectomies were completed in patients with negative ultrasound findings at the discretion of the surgeon for concern of the remaining testicles acting as a sanctuary for disease. The orchiectomy side was chosen based on the presumed primary landing zone. Additionally, ultrasound findings completed upon initial workup were recorded. Results that were reported as non-specific reflect no concerning findings for malignancy.

Descriptive statistics were used to analyze the data. This study was approved by the Western University Research Ethics Board.

Results

Of the 414 men treated between 1980 and 2014 for metastatic GCTs, 18 with RPGCTs were identified. Four of these were excluded due to incomplete imaging reports or reports suggestive of malignancy. The 14 remaining included patients were considered to have RPGCT at the time of initial diagnosis (Fig. 1).

We tallied patient demographics and baseline characteristics (Table 1). The median age was 33 (range: 24–45). Pre-

chemotherapeutic tumour markers were elevated in about half of included patients, and serum lactate dehydrogenase was elevated in almost all included patients. IGCCCG prognostic stages were as follows: good in 3 patients (21%); intermediate in 6 patients (43%); and poor in 5 patients (36%). Four of the poor prognosis patients were classified as such due to elevated tumour markers, 3 received BEP (bleomycin, etoposide, cisplatin) chemotherapy, and only 1 in 5 patients had salvage therapy. Overall, all patients received systemic cisplatin-based chemotherapy, with most receiving BEP (71%).

We tallied the clinical details of all 14 patients (Table 2). Eight patients had orchiectomy and pathology described viable malignancy in 3 patients (21%), and testicular fibrosis or scarring following chemotherapy in 5 patients (35%). Of the 14 patients, 10 had post-chemotherapy retroperitoneal lymph node dissection (RPLND), and corresponding testicular pathology was available in 8 of these cases. None of these 8 patients had corresponding normal testicular pathology in the context of abnormal RPLND pathology. In the 2 cases without corresponding testicular pathology, the RPLND pathology was consistent with scarring or fibrosis secondary to chemotherapy. Overall survival data were incomplete due to patients lost to follow-up.

Discussion

Extragenadal GCTs remain controversial with respect to their origin, natural history, and treatment.^{4,8} The existence of primary RPGCTs, which account for about one-third of these tumours, has been previously questioned.^{1,5} The accepted theory is that these tumours originate from displaced germ cells during embryonic development in the fetus.^{1,8}

Table 1. Patient characteristics (n = 14)

Characteristic		Patients, n (%)
Demographics		
Median age (range), years		33 (24–45)
Mean BMI (range)		26.7 (22.9–34.7)
IGCCCG prognostic stage		
Good		3 (21%)
Intermediate		6 (43%)
Poor		5 (36%)
Pre-chemotherapy tumour markers		
AFP	Normal	8 (57%)
	Abnormal	6 (43%)
B-HCG	Normal	6 (43%)
	Abnormal	8 (57%)
LDH	Normal	2 (17%)
	Abnormal	10 (83%)

BMI: body mass index; IGCCCG: International Germ Cell Classification Collaborative Group; AFP: alpha-fetoprotein; B-HCG: human chorionic gonadotropin; LDH: lactate dehydrogenase.

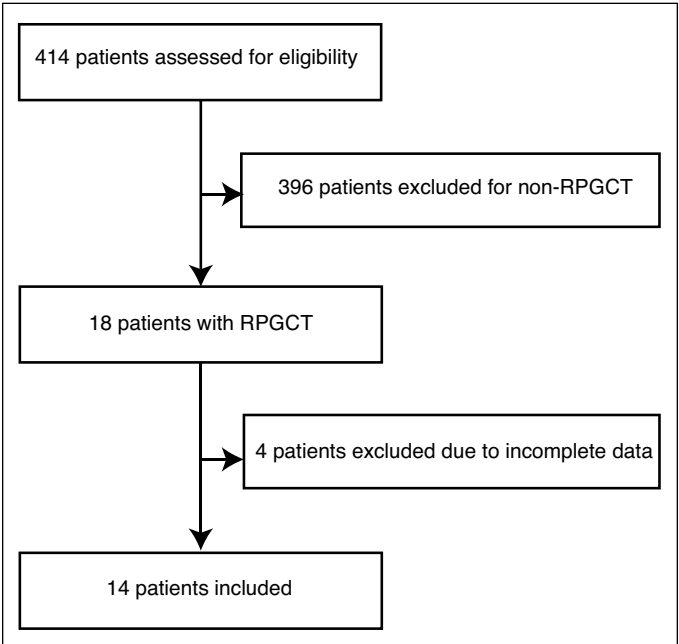


Fig. 1. Patient identification. RPGCT: retroperitoneal extragonadal germ cell tumours.

Table 2. Individual patient clinical data

Patient	Chemotherapy	Ultrasound findings	Orchiectomy	Testicular pathology	RPLND	Final RPLND pathology
1	BEP	Negative for malignancy	Yes	Post-chemotherapy Scar	Yes	Necrosis
2	PVB/PE	Negative for malignancy	No	N/A	No	N/A
3	BEP	Non-specific	Yes	Seminoma	Yes	Necrosis
4	PVB	Negative for malignancy	No	N/A	Yes	Fibrosis
5	BEP	Non-specific	Yes	Embryonal carcinoma	Yes	Viable GCT (embryonal, teratoma, seminoma)
6	VIP	Non-specific	No	N/A	Yes	Necrosis
7	BEP	Negative for malignancy	No	N/A	No	N/A
8	PIE	Non-specific	Yes	Post-chemotherapy scar	Yes	Metastatic carcinoma
9	BEP	Negative for malignancy	Yes	Post-chemotherapy scar	Yes	Metastatic seminoma
10	BEP	Negative for malignancy	Yes	Post-chemotherapy scar	Yes	Fibrosis and necrosis
11	BEP	Non-specific	Yes	Post-chemotherapy scar	Yes	<5% mature teratoma
12	BEP	Non-specific	No	N/A	No	N/A
13	BEP	Negative for malignancy	Yes	Rare intratubular germ cell neoplasia	Yes	Necrosis
14	BEP	Negative for malignancy	No	N/A	No	N/A

RPLND: retroperitoneal lymph node dissection; BEP: bleomycin, etoposide, cisplatin; PVB: cisplatin, vinblastine, and bleomycin; PE: cisplatin, etoposide; PIE: cisplatin, ifosfamide, and oral etoposide; N/A: not available; GCT: germ cell tumour.

Patients with primary RPGCT had more advanced disease stage. Less than one-quarter of the patients in our study presented with IGCCCG good prognosis disease, whereas typically this is 60% to 70% in most series.⁹ Most patients presented with intermediate or poor prognosis IGCCCG disease, and the incidence of the latter was doubled. This should not be surprising with the lack of an enlarging testicular mass to serve as a clinical “trigger” for the patient seeking medical attention.

Our study was unable to identify patients with abnormal pathology in their retroperitoneal mass and corresponding normal testicular pathology. Many of these patients had testicular fibrosis and scarring suggestive of “burnt-out” malignant disease, suggesting primary tumour regression.¹⁰⁻¹² This supports the assertion that primary retroperitoneal GCTs may not exist as a distinct disease entity, but rather that this clinicopathological syndrome may be representative of metastatic disease originating from a clinically occult testicular primary tumour.^{1,5}

This distinction has clinical importance in the management of the testes in men with the metastatic RPGCT syndrome. If correct, there should be concern about the presence of viable germ cell malignancy in the testes of these patients, which could serve as a potential source for recurrence.¹⁰ More rigorous evaluation using physical exam, radiographic imaging and laboratory investigations must be completed to further elucidate any trends or characteristics to help further guide management.^{1,5} For example, subtle ultrasonographic findings that are often considered negative may represent disease.^{2,5} Some studies have questioned the role of testicular biopsy and suggest that it is not routinely justified.² Routine management with orchiectomy would overtreat patients without viable GCT.¹⁰ So the optimal approach remains unclear.

The conclusions of our study are limited by its small sample size. We identified patients over a long time period at a tertiary academic centre and the incidence of primary RPGCT was relatively low. Our study was retrospective, and variability would be increased by multiple physicians completing pathologic and radiographic reports over the time period reviewed due to the inherent subjectivity in the initial diagnosis of a RPGCT. We could not comment on the role of physical examination of the testes based on limited data reporting, but this is considered a standard procedure in the investigation of a GCT.⁵

Conclusion

Although an uncommon presentation at our centre, further information from large multicentre databases could provide enhanced information about patients presenting with a primary retroperitoneal GCT to optimize management.

Competing interests: Dr. Punjani declares no competing financial or personal interests. Dr. Winquist is currently participating in clinical trials with AstraZeneca, Exelixis, Janssen, Roche, and Medivation. Dr. Power is currently participating in clinical trials with Argos Therapeutics.

This paper has been peer-reviewed.

References

- Scholz M, Zehender M, Thalmann GN, et al. Extragonadal retroperitoneal germ cell tumor: Evidence of origin in the testis. *Ann Oncol* 2002;13:121-4. <http://dx.doi.org/10.1093/annonc/mdf003>
- Schmoll HJ. Extragonadal germ cell tumors. *Ann Oncol* 2002;13(Suppl4):265-72. <http://dx.doi.org/10.1093/annonc/mdf669>

3. Riggs SB, Burgess EF, Gaston KE, et al. Postchemotherapy surgery for germ cell tumors—what have we learned in 35 years? *Oncologist* 2014;19:498-506. <http://dx.doi.org/10.1634/theoncologist.2013-0379>
4. Albany C, Einhorn LH. Extragonadal germ cell tumors: Clinical presentation and management. *Curr Opin Oncol* 2013;25:261-5. <http://dx.doi.org/10.1097/cco.0b013e32835f085d>
5. Parada D, Pena KB, Moreira O, et al. Extragonadal retroperitoneal germ cell tumor: Primary versus metastases? *Arch Esp Urol* 2007;60:713-9. <http://dx.doi.org/10.4321/S0004-06142007000600020>
6. Goss PE, Schwertfeger L, Blackstein ME, et al. Extragonadal germ cell tumors. A 14-year Toronto experience. *Cancer* 1994;73:1971-9. [http://dx.doi.org/10.1002/1097-0142\(19940401\)73:7<1971::AID-CNCR2820730731>3.0.CO;2-A](http://dx.doi.org/10.1002/1097-0142(19940401)73:7<1971::AID-CNCR2820730731>3.0.CO;2-A)
7. Bokemeyer C, Hartmann JT, Fossa SD, et al. Extragonadal germ cell tumors: Relation to testicular neoplasia and management options. *APMIS* 2003;111:49-59; discussion 63.
8. Bokemeyer C, Nichols CR, Droz JP, et al. Extragonadal germ cell tumors of the mediastinum and retroperitoneum: Results from an international analysis. *J Clin Oncol* 2002;20:1864-73. <http://dx.doi.org/10.1200/JCO.2002.07.062>
9. Srikanthan A, Tran B, Beausoleil M, et al. Large retroperitoneal lymphadenopathy as a predictor of venous thromboembolism in patients with disseminated germ cell tumors treated with chemotherapy. *J Clin Oncol* 2015;33:582-7. <http://dx.doi.org/10.1200/JCO.2014.58.6537>
10. Gonzalez R, Montoto Santome P, Iglesias Porto E, et al. Extragonadal germ cell tumour with the «burned out» phenomenon mimicking a retroperitoneal tumour of neurogenic origin. *Arch Esp Urol* 2012;65:900-2.
11. Lopez JJ, Angulo JC. Burned-out tumour of the testis presenting as retroperitoneal choriocarcinoma. *Int Urol Nephrol* 1994;26:549-53. <http://dx.doi.org/10.1007/BF02767657>
12. Sidhu PS, Muir GH. Extragonadal tumor and testicular microlithiasis: “burned-out” tumors are represented by macrocalcification. *J Ultrasound Med* 2011;30:1604-5.

Correspondence: Dr. Nahid Punjani, Division of Urology, London Health Sciences Centre, Western University, London, ON; nahidpunjani@gmail.com