

A report on the clinical efficacy of a new Bougie-internal urethrectomy

Choe Sung Hyn, MD,* Kim Han Jong, MD;† Choe Un Chol, MD‡

*Director of Urology Research Center, Kim Man You Hospital, Pyongyang, Democratic People's Republic of Korea; †Director of Kim Man You Hospital, Pyongyang, Democratic People's Republic of Korea; ‡Urologist of Kim Man You Hospital, Pyongyang, Democratic People's Republic of Korea

Cite as: *Can Urol Assoc J* 2015;9(7-8):E447-52. <http://dx.doi.org/10.5489/cuaj.2751>
Published online July 17, 2015.

Abstract

Introduction: We compare the clinical efficacy of the new bougie-internal urethrectomy (BIU) with internal urethrotomy and urethroplasty to treat urethral stricture disease.

Methods: We prospectively studied 186 people with urethral stricture disease. Of these, 84 were identified for urethroplasty and 102 for internal urethrotomy (endoscopic urethrotomy). Among the 84 identified for urethroplasty, 52 received BIU (Group 1) and the remaining 32 received urethroplasty. Among the 102 identified for internal urethrotomy, 58 received BIU (Group 2) and the remaining 44 received the internal urethrotomy. After surgery, we evaluated the clinical efficacy of the BIU (operative invasions, voiding flow rates, complications, sequelae) compared with the endoscopic treatment and urethroplasty.

Results: Patient age ranged from 20 to 70 years. The follow-up period was 2 years. In the BIU Group 1, the BIU Group 2, and the internal urethrotomy (endoscopic treatment), the length of strictures were 2.9 ± 1.5 , 2.8 ± 1.3 , 1.6 ± 0.7 , and 1.5 ± 0.6 , respectively. In the BIU Group 1, the urethroplasty, the BIU Group 2, and the internal urethrotomy (endoscopic treatment), the amount of bleeding was 34.1 ± 17.1 , 172.2 ± 29.8 , 28.5 ± 9.8 , and 49.7 ± 13.6 mL, respectively. In the BIU Group 1, the urethroplasty, the BIU Group 2, and the internal urethrotomy, the recurrence rates were 5.8%, 86%, 6.8% and 25%, and the average flow rates were 18.1 ± 4.8 , 13.1 ± 3.9 , 18.2 ± 3.6 , 10.1 ± 3.1 mL/s, respectively. There was no sequelae (sexual dysfunction, penile change) in both BIU groups.

Conclusions: The new BIU could be considered first-line treatment in all patients with indications for visual internal urethrotomy and urethroplasty.

Introduction

There are various therapies to treat urethral stricture, including transurethral internal urethrotomy (TUR) and urethroplasty.¹ TUR has a high recurrence rate and narrow indi-

cation; urethroplasty has a high operative invasion and a high incidence of sexual dysfunction and penile change.^{2,3} In the endoscopic urethrotomy, strictures with a length <1 cm had a recurrence rate of 27% compared with 50% for those ≥ 1 cm in length.⁴ The endoscopic treatment of urethral stricture is associated with high recurrence rates ranging from 30% to 80%.⁵ Due to high recurrence rates, some clinicians argue that an initial urethrotomy is not cost-effective or beneficial in the long-term care of these patients. Given the high rate of recurrence with minimally-invasive techniques and the overall superior outcomes of surgical reconstruction, we attempted endoscopic urethrotomy only once, and if unsuccessful, we progressed directly to surgical reconstruction (urethroplasty) in appropriately selected men, rather than multiple, repeated endoscopic procedures. For strictures measuring 2 to 4 cm, we used an excisional augmented anastomotic urethroplasty.⁶ The urethroplasty is highly invasive and has a high incidence of sexual dysfunction and penile changes.

We have developed new equipment for TUR, the bougie-internal urethrectomy (BIU) to overcome the defects of endoscopic treatment and urethroplasty. We are evaluating its clinical efficacy compared to other treatments.

Methods

We prospectively studied 186 people with urethral stricture disease. Of these, 84 were identified for urethroplasty and 102 for internal urethrotomy (endoscopic urethrotomy). Among the 84 identified for urethroplasty, 52 received BIU (Group 1) and the remaining 32 received urethroplasty. Among the 102 identified for internal urethrotomy, 58 received BIU (Group 2) and the remaining 44 received the internal urethrotomy. After surgery, we evaluated the clinical efficacy of the BIU (operative invasions, voiding flow rates, complications, sequelae) compared with the endoscopic treatment and urethroplasty. Patient ages ranged from 20 to 70 years (Table 1).

Table 1. Materials used

Material	No. patients	Position (%)		Length of stricture (cm)	Urethral lumen (%)	
		Anterior	Posterior		-	+
BIU (Group 1)	52	18 (34.6)	36 (65.4)	2.9 ± 1.5	49 (94.2)	3 (5.8)
Urethroplasty	32	12 (37.4)	20 (62.5)	2.8 ± 1.3	30 (93.7)	2 (6.3)
BIU (Group 2)	58	19 (32.8)	39 (67.2)	1.6 ± 0.7	8 (13.8)	50 (86.2)
Endoscopic urethrectomy	44	16 (36.4)	28 (63.6)	1.5 ± 0.6	6 (13.6)	38 (86.4)

BIU: Bougie-internal urethrectomy.

Operation apparatus

The equipment for BIU includes Bougie, apparatus for urethrectomy, and guidance wire.

The bougie consists of two independent tubular bougies and disk-like devices to measure stricture length behind every bougie. Two assembled disk-like devices become a way to measure stricture length and to connect two independent tubular bougies. The apparatus for urethrectomy consists of outer tube, guide and handle (Fig. 1a, 1b, 1c, 1d).

The outer tube is stainless steel 5 to 10 mm (15–30 French) in diameter according to the urethra bore and 22 cm in length. The anterior end is knife-edge to excise the urethral stricture.

The guidewire adheres to and enters the lumen of the outer tube. The head of the guidewire protects the urethral mucous membrane from the anterior knife edge of the outer tube. The guidewire allows the anterior knife edge of the outer tube to excise the stricture and to reach the opposite bougie. There is an external immobilizer at the posterior end of the guide. The handle is on the outer tube and is used to excise the stricture. The guidewire is a stainless steel wire, which is 1 mm in diameter and 60 cm in length. The anterior end is sharp needle-like and there is the needle-hole behind it.

Operative method

Our newly developed BIU is a minimally-invasive intervention which is the same size as a meatoscope (15, 18, 21, 24, 27, 30 French). The indications for BIU use include: patients

with anterior, bulbar and posterior urethral stricture with or without a preserved lumen; and a stricture ≤ 4 cm in length. General anesthesia or epidural analgesia is used.

The BIU technique includes a lower abdominal and vesical incision. It is used in cases in which patients have a natural vesical fistula. The incision is 2 to 3 cm in the lower part of abdominal midline and 1 to 2 cm of the bladder.

To measure the urethral stricture length, we inserted a separate bougie into the external and internal urethra, and assembled a disk-like measurer as an attachment to both bougies. To measure the stricture length using a disk-like measurer, we used the guidewire-indwelling method. We also inserted the guidewire into the posterior lumen of the bougie of the internal urethra under the squeezed stricture site.

To incise the stricture site, we separated the measurer and pulled out the bougie towards the external urethra. We then inserted the assembled apparatus for urethrectomy into the external urethra along the guidewire to reach the stricture site, squeeze and fix it. To loosen the outer tube immobilizer, we took the outer tube handle, rotated, advanced and excised the stricture site with the anterior knife-edge of the outer tube until it reached the opposite end of the bougie.

When the excision was completed, we pulled out the apparatus for urethrectomy and connected the guidewire hole to the balloon and indwelling catheter. We pulled out the guidewire and the bougie of the internal urethra; it was ligated with catgut and silk; to treat the vesical and cutaneous incision wound, we performed a fistula curettage and then covered it with gauze (Fig. 2a, Fig. 2b, Fig. 2c, Fig. 2d). To stop the flow of blood, we washed the compres-

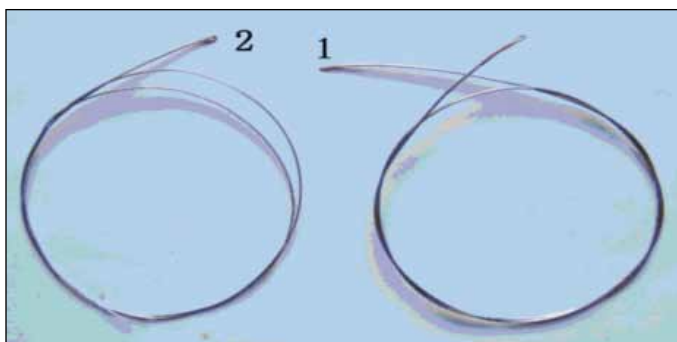


Fig. 1a. Guidewire. 1: Sharp needle tip; 2: Hole of the needle.




Fig. 1b. 1: The outer tube; 2: Guide.




Fig. 1c. The entome. 1: Outer tube immobilizer; 2: Handle; 3: Outer tube; 4: Head of guide.

sion bandage on the perineal region and lightly tracted the external urethra with a balloon catheter for compression of the ostium urethrae internum. The indwelling catheter was used for 3 weeks, and we performed a urethral dilation using the bougie if necessary. The BIU does not require vesicosotomy. Surgery should be carried out using radiography (Fig. 3a, Fig. 3b).

Results

In the BIU Group 1, the urethroplasty, the BIU Group 2 and the endoscopic urethrotomy groups, the operative times were 35.3 ± 13.2 , 103.7 ± 45.7 , 29.5 ± 3.7 , and 55.7 ± 18.6 minutes, respectively. The amount of bleeding was 34.1 ± 17.1 , 172.2 ± 29.8 , 28.5 ± 9.8 , and 49.7 ± 13.6 mL, respectively.

In terms of voiding flow rates, in the BIU Group 1, the urethroplasty, the BIU Group 2 and the endoscopic urethrotomy groups, the maximum flow rates were 23.9 ± 4.3 , 18.1 ± 5.2 , 23.7 ± 3.7 , and 12.6 ± 3.9 mL/s, respectively; the average flow rates were 18.1 ± 4.8 , 13.1 ± 3.9 , 18.2 ± 3.6 , and 10.1 ± 3.1 mL/s, respectively.

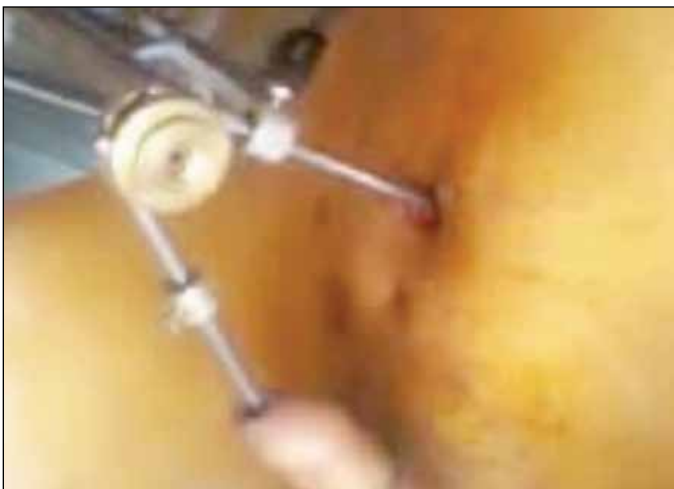

Fig. 2a. Disk-like measurer, which is an attachment of both bougies and indwelling of guidewire.




Fig. 1d. 1: The bougie; 2 and 3: Stricture length measurer.

The recurrence rates were 5.8% in the BIU Group 1, 86% in the urethroplasty group, 6.8% in the BIU Group 2, and 25% in the endoscopic urethrotomy group. The bougie treatment times in the BIU Group 1, the urethroplasty, the BIU Group 2 and the endoscopic urethrotomy groups were 2.9 ± 1.5 , 8.6 ± 3.7 , 2.7 ± 1.3 , and 10.9 ± 1.7 months, respectively. There was no sequelae in both BIU groups (Table 2).

Discussion

Urethral strictures in men are common and are most often iatrogenic. Other frequent causes include injury (pelvic fracture) and infection. The treatment approach depends on the location, etiology, and length of the stricture.

Treatment options include several minimally-invasive therapies (dilation, endoscopic urethrotomy) and surgical reconstruction of the urethra using flaps or grafts.⁷⁻⁹ No single procedure is appropriate to manage all strictures and multiple techniques may be used in the same patient during the

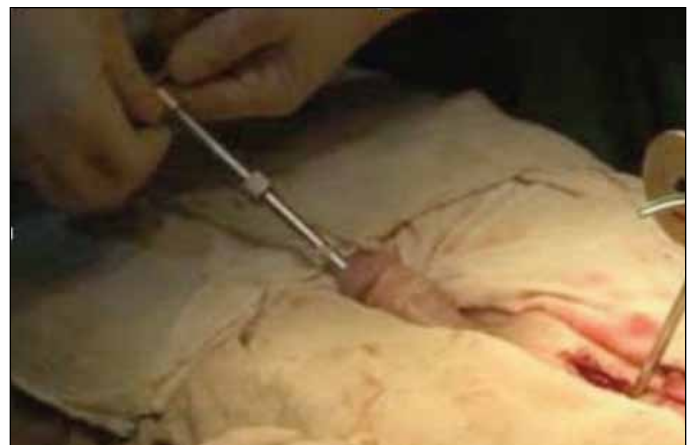

Fig. 2b. Entome inserted into the external urethra along guidewire.

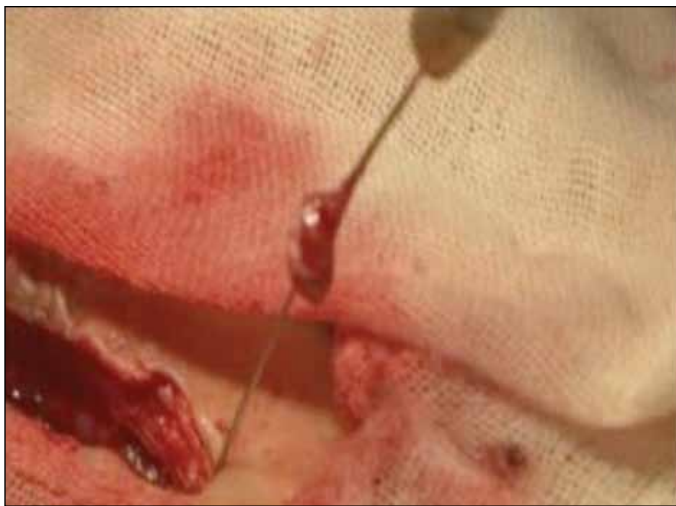

Fig. 2c. The excised stricture scar.

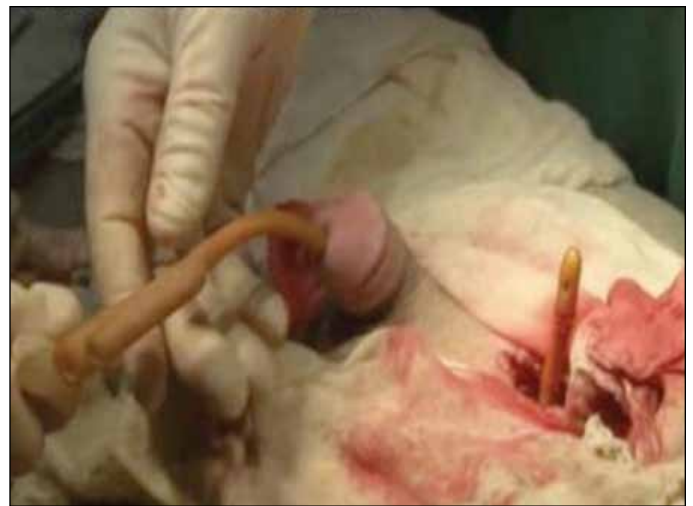

Fig. 2d. The indwelling catheter.

course of treatment to manage recurrence. An endoscopic urethrotomy is quick, widely available and safe. However, transurethral internal urethrotomy has a high recurrence rate and narrow indication. Strictures <1 cm in length respond well to minimally-invasive therapies.^{10,11}

In one study, strictures with a length <1 cm had a recurrence rate of 27% compared with 50% for those ≥ 1 cm.¹⁰ Bulbar strictures with a preserved luminal diameter >15 French (5 mm) had the best overall outcomes in a retrospective review of 224 patients who underwent internal urethrotomy.¹² The endoscopic treatment of urethral stricture is associated with high recurrence rates (30%–80%).⁵ Due to these high recurrence rates, some clinicians argue that an initial urethrotomy is not beneficial in the long-term care of these patients.^{13,14} It has also been suggested that multiple

endoscopic treatments can lead to difficult definitive open repairs and reduced overall success rates.^{15–17} The long-term success rates are overall poor.

The urethrotomy incision is made at the 12, o'clock, or at the 3 and 9 o'clock positions with a cold-knife urethrotome. Given the high rate of recurrence rates with minimally-invasive techniques and the overall superior outcomes of surgical reconstruction, we attempted an endoscopic urethrotomy only once, and if unsuccessful, we progressed directly to surgical reconstruction (urethroplasty) in appropriately selected men, rather than multiple, repeated endoscopic procedures. For strictures measuring 2 to 4 cm, we used an excisional augmented anastomotic urethroplasty.⁶

Prior to the development of this technique, we used flap-based repairs (using pedicled islands of penile skin or even

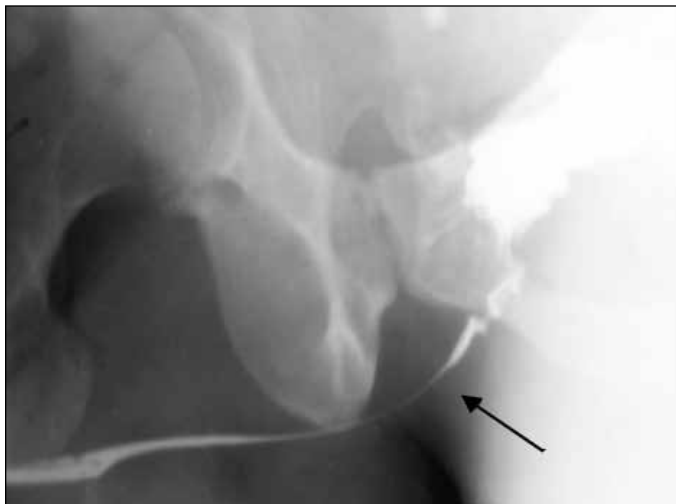


Fig. 3a. This shows the preoperative retrograde urography with posterior urethral stricture without lumen. The stricture is 3.6 cm in length. The arrow indicates the urethrorectal fistula.

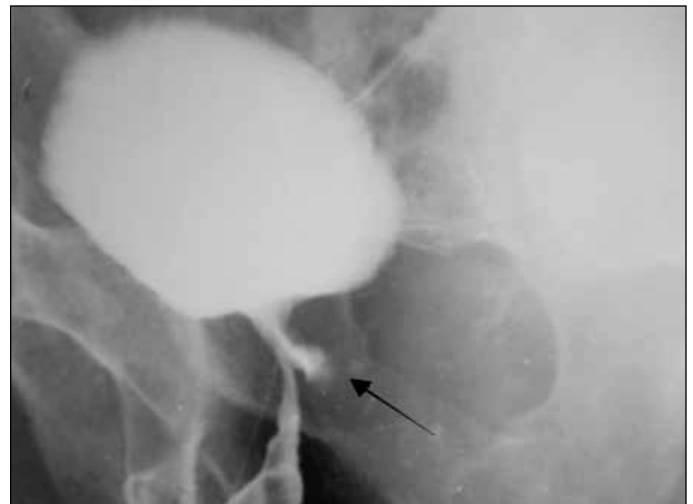

Fig. 3b. Six months after surgery. The arrow indicates a trace of the urethrorectal fistula.

Table 2. Clinical efficacy of a new BIU

	BIU (Group 1) n = 52	Urethroplasty n = 32	BIU (Group 2) n = 58	Endoscopic urethrectomy n = 44
Operative invasion				
Operative time (min)	35.3 ± 13.2*	103.7 ± 45.7	29.5 ± 3.7**	55.7 ± 18.6
Amount of bleeding (mL)	34.1 ± 17.1*	172.2 ± 29.8	28.5 ± 9.8**	49.7 ± 13.6
Voiding flow rate				
MRF (mL/s)	23.9 ± 4.3*	18.1 ± 5.2	23.7 ± 3.7**	12.6 ± 3.9
AFR (mL/s)	18.1 ± 4.8*	13.1 ± 3.9	18.2 ± 3.6**	10.1 ± 3.1
Complication				
Recurrent rate (%)	3 (5.8)*	8 (25.0)	4 (6.8)	38 (86.0)
Bougie treatment (month)	2.9 ± 1.5*	8.6 ± 3.7	2.7 ± 1.3**	10.9 ± 1.7
Sequelae				
Sexual dysfunction (%)	–	31.2	–	–
Penile change (%)	–	18.8	–	–

BIU: Bougie-internal urethrectomy; MRF: maximum flow rate; AFR: average flow rate. * $p < 0.01$ vs. urethroplasty; ** $p < 0.01$ vs. urethrotomy.

scrotal skin) and tubularized graft urethroplasties to repair bulbar urethral strictures; however, these repairs failed in up to 56% of patients.¹⁸ Techniques for urethroplasty include excision with primary anastomosis (anastomotic urethroplasty), incision with onlay graft or flap repair, and stricture excision with an anastomosis that is augmented with a graft (excisional augmented anastomotic urethroplasty).¹⁹ Repairs can be staged, if needed. Urethroplasty in adult patients can be a challenging and difficult despite its apparent simplicity. The overall failure rate was 15% in a study involving 252 males (median follow-up 37 months).²⁰ Urethroplasty is highly invasive and has a high incidence of sexual dysfunction and penile changes.²¹⁻²³

To counter these issues, we developed new equipment for BIU and we evaluated its clinical efficacy. We found that the BIU was quick, widely available, and safe. The new BIU is highly effective in patients with the indications of urethroplasty and internal urethrotomy (endoscopic urethrotomy). Our newly developed BIU is a minimally-invasive intervention which is the same size as a meatscope (15, 18, 21, 24, 27, 30 French). With the BIU, patients experienced less bleeding and a shorter operative time. BIU patients experienced high voiding flow rates, shorter treatment time and less recurrence than patients treated with endoscopically and with urethroplasty. There was no sequelae in the BIU groups.

Conclusion

The BIU treatment is quick, widely available and safe. It is the superior minimally-invasive therapeutic intervention to treat urethral stricture. It can be considered first-line treatment in patients with the indications of visual internal urethrotomy and urethroplasty.

Competing interests: The authors declare no competing financial or personal interests.

This paper has been peer-reviewed.

References

- Lumen N, Hoebeke P, Willemsen P, et al. Etiology of urethral stricture disease in the 21st century. *J Urol* 2009;182:983-7. <http://dx.doi.org/10.1016/j.juro.2009.05.023>
- Bullock TL, Brandes SB. Adult anterior urethral strictures: A national practice patterns survey of board certified urologists in the United States. *J Urol* 2007;177:685-90. <http://dx.doi.org/10.1016/j.juro.2006.09.052>
- Barbagli G, Palminteri E, Lazzeri M, et al. Long-term outcome of urethroplasty after failed urethrotomy versus primary repair. *J Urol* 2001;165:1918-9. [http://dx.doi.org/10.1016/S0022-5347\(05\)66242-8](http://dx.doi.org/10.1016/S0022-5347(05)66242-8)
- Stone AR, Randall JR, Shorrock K, et al. Optical urethrotomy—a 3-year experience. *Br J Urol* 1983;55:701-4. <http://dx.doi.org/10.1111/j.1464-410X.1983.tb03409.x>
- Albers P, Fichtner J, Brühl P, et al. Long-term results of internal urethrotomy. *J Urol* 1996;156:1611-4. [http://dx.doi.org/10.1016/S0022-5347\(01\)65461-2](http://dx.doi.org/10.1016/S0022-5347(01)65461-2)
- Rourke KF, Jordan GH. Primary urethral reconstruction: The cost minimized approach to the bulbous urethral stricture. *J Urol* 2005;173:1206-10. <http://dx.doi.org/10.1097/01.ju.0000154971.05286.81>
- Steenkamp JW, Heyns CF, de Kock ML. Outpatient treatment for male urethral strictures- dilatation versus internal urethrotomy. *S Afr J Surg* 1997; 35:125-30.
- Morey AF, McAninch JW. Sonographic staging of anterior urethral strictures. *J Urol* 2000;163:1070-5. [http://dx.doi.org/10.1016/S0022-5347\(05\)67696-3](http://dx.doi.org/10.1016/S0022-5347(05)67696-3)
- Ather MH, Zehri AA, Soomro K, et al. The safety and efficacy of optical urethrotomy using a spongiosum block with sedation: A comparative nonrandomized study. *J Urol* 2009;181:2134-8. <http://dx.doi.org/10.1016/j.juro.2009.01.017>
- Munks DG, Alli MO, Goad EH. Optical urethrotomy under local anaesthesia is a feasible option in urethral stricture disease. *Trop Doct* 2010;40:31-2. <http://dx.doi.org/10.1258/td.2009.090121>
- Anger JT, Buckley JC, Santucci RA, et al. Trends in stricture management among male Medicare beneficiaries: Underuse of urethroplasty? *Urology* 2011;77:481-5. <http://dx.doi.org/10.1016/j.urology.2010.05.055>
- Morey A. Urethral stricture is now an open surgical disease. *J Urol* 2009;181:953-4. <http://dx.doi.org/10.1016/j.juro.2008.12.026>
- Roehrborn CG, McConnell JD. Analysis of factors contributing to success or failure of 1-stage urethroplasty for urethral stricture disease. *J Urol* 1994;151:869-74.
- Singh BP, Andankar MG, Swain SK, et al. Impact of prior urethral manipulation on outcome of anastomotic urethroplasty for post-traumatic urethral stricture. *Urology* 2010;75:179-82. <http://dx.doi.org/10.1016/j.urology.2009.06.081>
- Breyer BN, McAninch JW, Whitson JM, et al. Multivariate analysis of risk factors for long-term urethroplasty outcome. *J Urol* 2010;183:613-7. <http://dx.doi.org/10.1016/j.juro.2009.10.018>
- Guralnick ML, Webster GD. The augmented anastomotic urethroplasty: Indications and outcome in 29 patients. *J Urol* 2001;165:1496-501. [http://dx.doi.org/10.1016/S0022-5347\(05\)66335-5](http://dx.doi.org/10.1016/S0022-5347(05)66335-5)

17. Morey AF, Lin HC, DeRosa CA, et al. Fossa navicularis reconstruction: impact of stricture length on outcomes and assessment of extended meatotomy (first stage Johanson) maneuver. *J Urol* 2007;177:184-7. <http://dx.doi.org/10.1016/j.juro.2006.08.062>
18. Pansadoro V, Emiliozzi P. Internal urethrotomy in the management of anterior urethral strictures: Long-term followup. *J Urol* 1996;156:73-5. [http://dx.doi.org/10.1016/S0022-5347\(01\)65942-1](http://dx.doi.org/10.1016/S0022-5347(01)65942-1)
19. Hussain M, Greenwell TJ, Shah J, et al. Long-term results of a self-expanding wallstent in the treatment of urethral stricture. *BJU Int* 2004;94:1037-9. <http://dx.doi.org/10.1111/j.1464-410X.2004.05100.x>
20. Chapple CR, Bhargava S. Management of the failure of a permanently implanted urethral stent-a therapeutic challenge. *Eur Urol* 2008;54:665-70. <http://dx.doi.org/10.1016/j.eururo.2007.11.024>
21. Elliott DS, Boone TB. Combined stent and artificial urinary sphincter for management of severe recurrent bladder neck contracture and stress incontinence after prostatectomy: A long-term evaluation. *J Urol* 2001;165:413-5. <http://dx.doi.org/10.1097/00005392-200102000-00014>
22. Mundy AR. The long-term results of skin inlay urethroplasty. *Br J Urol* 1995;75:59-61. <http://dx.doi.org/10.1111/j.1464-410X.1995.tb07233.x>
23. Lumen N, Hoebeke P, Oosterlinck W. Urethroplasty for urethral strictures: Quality assessment of an in-home algorithm. *Int J Urol* 2010;17:167-74. <http://dx.doi.org/10.1111/j.1442-2042.2009.02435.x>

Correspondence: Dr. Sung-hyn Choe, Director of Urology Research Center, Kim Man You Hospital, Pyongyang, D. P. R. of Korea; ryongnam10@yahoo.com