

Bladder agenesis and incomplete kidney duplication: Ileal reservoir with continent diversion as definitive treatment

Byron Alexis Pacheco-Mendoza, MD,* Fernando J. González-Ledón, MD,* Mario Díaz-Pardo, MD,* Juan L. Soto-Blanquel, MD,* Osvaldo Daniel Castelán-Martínez, PhD†

*Urology Department, Hospital Infantil de México Federico Gómez, Mexico City, Mexico; †Clinical Epidemiology Unit, Hospital Infantil de México Federico Gómez, Mexico City, Mexico

Cite as: *Can Urol Assoc J* 2015;9(3-4):e142-4. <http://dx.doi.org/10.5489/cuaj.2534>
Published online March 11, 2015.

Abstract

Bladder agenesis is an extremely rare entity. A 12-year-old female patient presented with urinary incontinence, recurrent urinary tract infections, visible vaginal introitus and urethra, and two holes at the vulvar vestibule. An investigation revealed bladder agenesis. Surgery confirmed the absence of bladder, and ileal reservoir in omega (Ω) was performed with continent diversion. At the 30-month follow-up, there was no complication in clean intermittent catheterization.

Introduction

Bladder agenesis is extremely rare; 90% of patients with bladder agenesis are women.¹ In these patients it is assumed that embryological division of the cloaca occurs in the fifth week in vitro into the urogenital sinus and that the anorectal canal proceeds normally (as the hindgut is usually normal in these patients). Bladder agenesis results from injury of the urogenital sinus during week 5 and 7 of embryogenesis.²

The treatment goal is to preserve renal function. Several surgical treatments can be performed, such as incontinent urinary diversion (ureterostomy), ileal conduit, and continent colonic reservoir.³ We report an ileal reservoir with Mitrofanoff continent diversion to preserve renal function.

Case report

A 12-year-old female patient, product of second gestation and vaginal delivery, with no significant prenatal history presented to hospital. She was examined by the nephrology department, which found urinary incontinence and recurrent urinary tract infections (UTI). She was then referred to the pediatric urology service. The physical examination

revealed female genitalia, vaginal introitus, and visible urethra, with two holes at the vulvar vestibule. Her laboratory test revealed serum creatinine at 0.9 mg/dL. Her imaging tests included voiding cystourethrography, computed tomography urography, and renal scintigraphy MAG-3 (Fig. 1). Upon examination under anesthesia (EUA) and urethrocscopy, we found that the ectopic ureters were in the vaginal anterior position, leading to the vestibule; we also found the urethral orifice blind, with no sight of the bladder (Fig. 2). The diagnosis of bladder agenesis was established and we decided to perform a bladder reservoir and continent diversion with appendix.

Surgery confirmed the absence of the bladder; the ureters drained into the vestibule; the uterus, Fallopian tubes, and ovaries were normal. The ureters of 1-cm diameter were dissected 8 cm from the distal to the proximal, then at 15 cm proximal to the ileocecal valve (VIC), 45 cm of the ileum were taken. End-to-end anastomosis with polyglycolic acid 4-0 was performed. Ileal reservoir in omega (Ω) was also performed (Fig. 2), making three submucosal tunnels in reservoir that created folds. The cecal appendix was isolated with vascular preservation to perform Mitrofanoff continent diversion that was placed in the right submucosal tunnel, with the right ureter in the medial submucosal tunnel and the left ureter in the left submucosal tunnel. The reservoir was closed with a running suture polyglycolic acid 3-0; ureteral and cystostomy Foley catheters were placed (Fig. 2).

Oral feeding started on postoperative day 5. On day 10, an iodine-contrast study was conducted, and no leaks were observed in the bladder neoreservoir. The patient was discharged on postoperative day 12. On postoperative day 28, ureteral catheters were removed and clean intermittent catheterization (CIC) started. On postoperative day 35, the Foley cystostomy was removed, leaving the Mitrofanoff open for 5 days to promote the closure of cystostomy, and CIC was restarted every 3 hours once the cystostomy closed.

At the 30-month follow-up, the patient does CIC every 3 hours, with no urine leak between CICs. She also under-

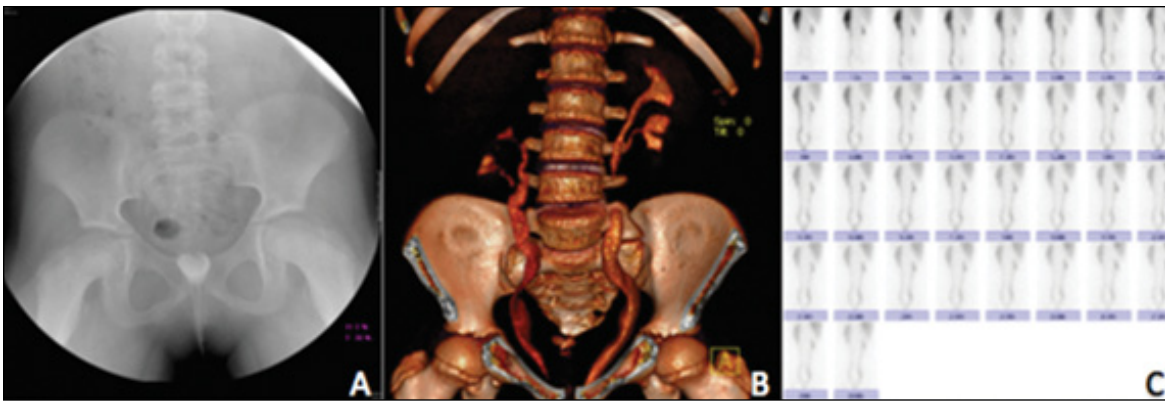


Fig. 1. A: Voiding cystourethrography, bladder absence. B: computed tomography urograph, bilateral incomplete kidney duplication, ectopic right kidney, bladder absence. C: renal scintigraphy MAG-3, bladder absence.

goes bladder irrigations 2 times per day to prevent calculi formation. The patient takes antibiotic prophylaxis, with appropriate increase of weight and height and has experienced no metabolic acidosis. Her serum creatinine was at 0.8 mg/dL, and the iodinated contrast study of the reservoir showed a capacity of 300 mL (Fig. 2).

Discussion

Children with bladder agenesis are divided in two groups. In the first group, children with urine drainage are maintained in uterus, are born alive and are frequently female. They are usually female probably because the female embryological development maintains drainage of urine so the renal function is preserved. In females with normal development of Müller structures, the ureters drain into the uterus, anterior vaginal wall, or vestibule. In males, the only way to achieve adequate urinary drainage is if there is persistent cloac, and if the ureters empty into the rectum or urachus – this rarely happens.² In the second group, patients are mostly male. They tend to lack urine drainage and renal function. These patients show oligohydramnios, are preterm or stillbirth, or die at early age.³⁻⁵ Worldwide, more than 60 cases of bladder

agenesis have been reported, but only 22 of these patients are still alive. Our current case represents the case 23.

Preserved renal function delays the diagnosis of bladder agenesis through childhood, adolescence, or even adulthood.⁶ Patients with bladder agenesis who preserve urine drainage are clinically manifested by urinary incontinence or UTI.^{3,6} Our patient was referred to the urology department with both features, and the diagnosis was established at the beginning of the study.

Bladder agenesis patients may have associated malformations, such as genitals ambiguity, agenesis penis, cystic kidneys, solitary kidneys, anorectal malformations, sacral anomalies, or multicystic dysplastic.^{1,4,5} Our patient has a bilateral incomplete kidney duplication, ectopic right kidney, and hypoplasia. To the best of our knowledge, this is the first case of bladder agenesis with bilateral incomplete kidney duplication.

In patients with bladder agenesis, renal function is compromised, probably due to associated hydronephrosis or multicystic dysplasia,² which may occur in the kidneys with ureteral obstruction, secondary to ectopic or due recurrent UTI. For this reason, in these patients it is essential to preserve renal function in the postnatal stage, in the form of

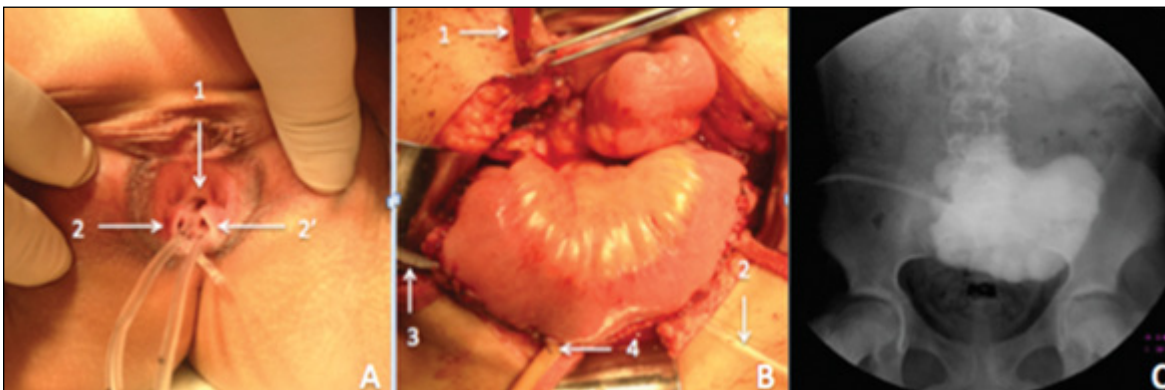


Fig. 2. A: Examination under anesthesia: urethra (1), right ureter (2) and left ureter (2'). B: ileal reservoir: Mitrofanoff's catheter (1), right ureteral catheter (2), left ureteral catheter (3) and cystostomy Foley catheter. C: iodinated contrast study.

noncontinent diversions, such as cutaneous ureterostomy and ileal conduit.^{7,8} There are three published bladder agenesis cases with continent urinary diversion. In the first case, the authors performed Penn pouch and Mitrofanoff with cecal appendix, but metabolic acidosis was reported in follow-up.⁹ In the other two cases, an ileal reservoir and Mitrofanoff with cecal appendix were performed.^{3,10}

In our case we performed an ileal reservoir (Ω) with Mitrofanoff continent diversion with cecal appendix; the procedures previously made have different details but all have two main goals: to preserve renal function and to improve the quality of life. Both goals can be achieved using any reservoir plus continent diversion.

Conclusion

This report contributes to the worldwide literature describing a case of a patient with bladder agenesis. This patient was born alive, with bilateral incomplete renal duplication and ectopic right kidney, and successfully underwent surgical treatment.

Competing interests: Authors declare no competing financial or personal interests.

This paper has been peer-reviewed.

References

1. García de León JM, Fariás-Cortés JD, Vanzzini-Guerrero MA. Penis and bladder agenesis in a newborn male: report of a case and review of the literature [in Spanish]. *Rev Mex Urol* 2013;73:26-32.
2. Patkowski D, Apoznariski W, Szydelko T, et al. Bladder agenesis in a male neonate. *J Pediatr Surg* 2008;43:e1-3. <http://dx.doi.org/10.1016/j.jpedsurg.2008.06.003>
3. Pfister, D, Sahi D, Heidenreich A, et al. A continent urinary diversion in a female with agenesis of the bladder: A 5-year follow-up. *Urology* 2012;80:437-9. <http://dx.doi.org/10.1016/j.urology.2011.12.010>
4. García de León JM, García-Pérez JA, Kantum-Jiménez EM. Bladder agenesis. Report of two cases [in Spanish]. *Rev Mex Urol* 1998;58:100-4.
5. Weight CJ, Chand D, Ross JH. Single system ectopic ureter to rectum subtending solitary kidney and bladder agenesis in newborn male. *Urology* 2006;68:1344. e1-3.
6. Pasaoglu E, Tokoglu F, Boyacigil S, et al. A case of bladder agenesis. *Australas Radiol* 1997;41:201-3.
7. Graham SD. Agenesis of bladder. *J Urol* 1972;107:660-1.
8. Glenn JF. Agenesis of the bladder. *J Am Med Assoc* 1959;169:2016-8. <http://dx.doi.org/10.1001/jama.1959.73000340001013>
9. Khemchandani SI. Triad of bladder agenesis with solitary kidney and ectopic ureter. *Indian J Urol* 2008;24:566-8. <http://dx.doi.org/10.4103/0970-1591.44271>
10. Nazim SM, Zaidi Z. Bilateral ectopic ureters with bladder agenesis. *J Pak Med Assoc* 2012;62:1086-9.

Correspondence: Dr. Osvaldo Daniel Castellán-Martínez, Clinical Epidemiology Unit, Hospital Infantil de México Federico Gómez, Mexico City, Mexico; danielcastellamtz@gmail.com