

## Zero ischemia robotic-assisted partial nephrectomy in Alberta: Initial results of a novel approach

Ellen Forbes, MD,\* Douglas Cheung, BMSc;† Adam Kinnaird, MD,\* Blair St. Martin, MD\*

\*Division of Urology, Department of Surgery, University of Alberta, Edmonton, AB; †Faculty of Medicine and Dentistry, University of Alberta, Edmonton, AB

Cite as: *Can Urol Assoc J* 2015;9(3-4):128-32. <http://dx.doi.org/10.5489/cuaj.2448>  
Published online April 13, 2015.

### Abstract

**Introduction:** Partial nephrectomy remains the standard of care in early stage, organ-confined renal tumours. Recent evidence suggests that minimally invasive surgery can proceed without segmental vessel clamping. In this study, we review our experience at a Canadian centre with zero ischemia robotic-assisted partial nephrectomy (RAPN).

**Methods:** A retrospective chart review of zero ischemia RAPN was performed. All surgeries were consecutive partial nephrectomies performed by the same surgeon at a tertiary care centre in Northern Alberta. The mean follow-up period was 28 months. These outcomes were compared against the current standards for zero ischemia (as outlined by the University of Southern California Institute of Urology [USC]).

**Results:** We included 21 patients who underwent zero ischemia RAPN between January 2012 and June 2013. Baseline data were similar to contemporary studies. Twelve (57.1%) required no vascular clamping, 7 (33.3%) required clamping of a single segmental artery, and 2 (9.5%) required clamping of two segmental arteries. We achieved an average estimated blood loss of 158 cc, with a 9.2% average increase in creatinine postoperatively. Operating time and duration of hospital stay were short at 153 minutes and 2.2 days, respectively.

**Conclusion:** Zero ischemia partial nephrectomy was a viable option at our institution with favourable results in terms of intra-operative blood loss and postoperative creatinine change compared to results from contemporary standard zero ischemia studies (USC). To our knowledge, this is the first study to review an initial experience with the zero ischemia protocol in robotic-assisted partial nephrectomies at a Canadian hospital.

### Introduction

Malignant renal neoplasms are a significant cause of morbidity and mortality worldwide.<sup>1,2</sup> Treatment remains largely surgical; open, laparoscopic, and robotic partial nephrec-

tomy are well-studied as the treatment of choice in early stage, organ-confined renal tumours to maximally preserve remaining renal function.<sup>3-6</sup> During the procedure, the renal hilar vessels are traditionally clamped to facilitate decreased blood loss and improve cancer control.<sup>7-10</sup>

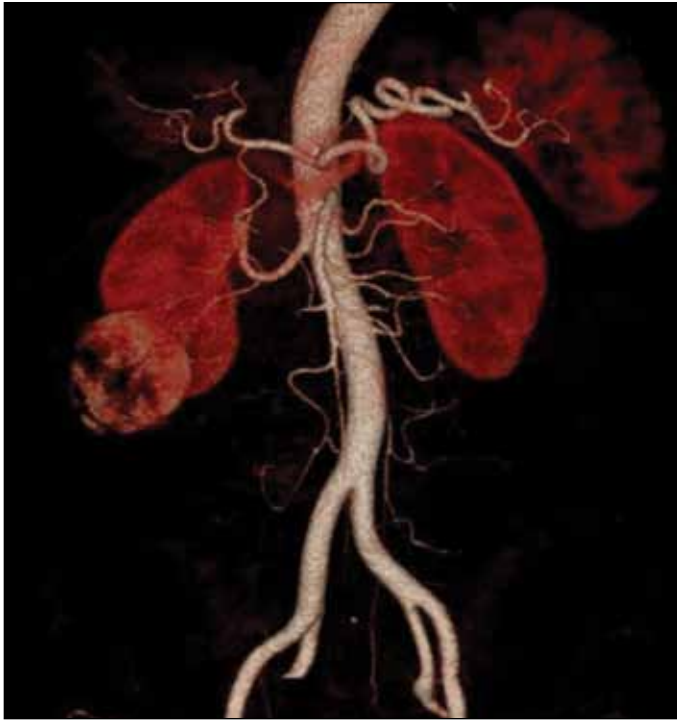
However, recent evidence suggests that minimally invasive surgery can proceed without segmental vessel clamping, described as the “zero ischemia” protocol.<sup>11-13</sup> This “zero ischemia” minimizes ischemic time and thus prevents associated nephron loss.<sup>14,15</sup> Unfortunately, the evidence and experience are currently limited, with only a few studies comparing and examining the outcomes of laparoscopic (LPN) and robotic-assisted partial nephrectomy (RAPN).<sup>15-20</sup>

At this time, no conclusive studies have been performed at a Canadian centre. In this study, we reviewed our clinical experience with the zero ischemia protocol in RAPN and compared it with the contemporary standard in zero ischemia technique.<sup>20</sup>

### Methods

This study has been approved by the institutional Health Research Ethics Board of the University of Alberta, Edmonton, Alberta. A retrospective chart review of zero ischemia RAPN was performed. Patients were recruited from January 2012 to June 2013. Each patient underwent preoperative computed tomography imaging to 3D reconstruct the renal artery branch anatomy for targeted anatomical dissection of tertiary or higher order renal arterial branches (Fig. 1). Precise vascular micro-dissection allows for the super-selective devascularization of the tumour, thereby restricting peri-tumour flow while maintaining “zero ischemia” to the remainder of the kidney. All surgeries were consecutive partial nephrectomies performed by the same surgeon at a tertiary care centre in Northern Alberta. The mean follow-up period was 28 months.

Our primary outcome measure was intra-operative blood loss and postoperative creatinine changes as a measure of renal function. A number of ancillary outcomes were also



**Fig. 1.** Preoperative computed tomography depicting renal vessel anatomy.

studied, including transfusion rate, operation (OR) time, length of hospital stay, 90-day complication rate, and hemoglobin concentration changes.

### Technical application of the zero ischemia protocol

We adopted a lateral camera port placement with the robotic camera port directly over the midpoint of the kidney. We used a 0° lens in the majority of cases; however, in some cases where further visualization over the upper pole was required, we added a 30° lens.

Complete mobilization of the kidney within Gerota's fascia was then performed in all cases except for small anterior exophytic lesions. This involved a longitudinal incision along the medial aspect of the anterior border of the kidney over Gerota's fascia and folding Gerota's fascia behind the kidney after fully mobilizing it. Posterior tumours were

approached with complete mobilization of the kidney, and then 180° renal mobilization such that the tumours were presented in an anterior fashion for dissection.

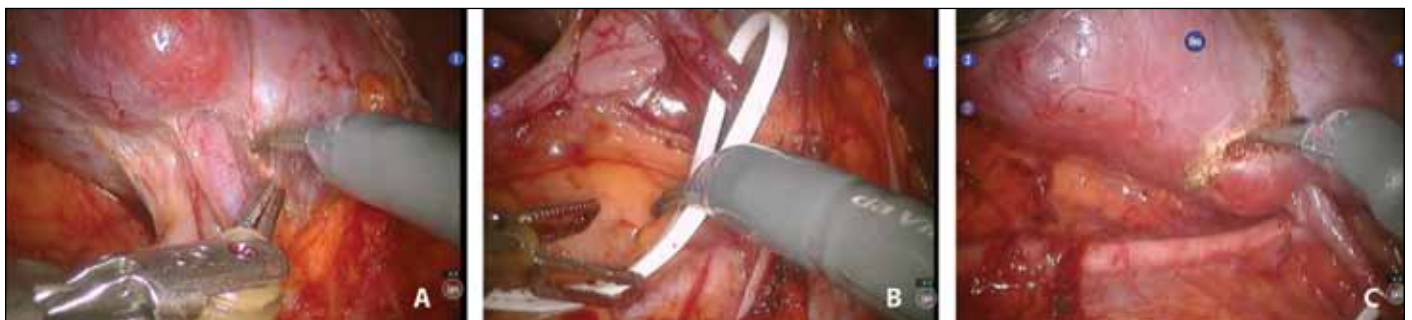At the time of tumour resection (Fig. 2), we used controlled hypotension with a target systolic blood pressure (sBP) between 80 and 100 mmHg. Adherence to this principle was uniformly adopted by our anesthetic team unless the patient had prior significant cardiopulmonary risk factors precluding this level of hypotension. In all 21 cases, this period of hypotension was less than 30 minutes. Secondly, at the time of tumour resection, we increased the pneumoperitoneum to 20 mmHg to control the venous ooze at the tumour bed. Aspiration of blood was also minimized as this decreased the pneumoperitoneum, leading to further venous ooze. Selective suctioning along the resection point of the tumour bed was utilized to facilitate dissection and resection. Any large blood vessel encountered was controlled with bipolar cautery through the fenestrated bipolar device. Additionally, the third robotic arm applied direct pressure on any significant bleeding vessels at the tumour bed.

Once the resection was complete, the individual bleeding points were selectively ligated with a 4-0 Vicryl on an SH needle. The remaining closure of the tumour bed was performed with running 3-0 PDS sutures controlled on either end with a 12 mm Hem-o-lok clip and tensioned until hemostasis was achieved. We did not utilize compressive buttress sutures to minimize damage to the normal parenchyma. In 9 cases, we used Surgicel (Ethicon Inc.) to facilitate hemostasis.

Finally, our initial longitudinal incision in Gerota's fascia was closed in a watertight fashion as a complement to the reconstruction, obviating the need for a peri-renal drain which was not routinely placed. Our outcomes were then compared against the current standard for zero ischemia by initial studies.<sup>20</sup>

### Results

Between January 2012 and June 2013, there were 21 patients who underwent zero ischemia RAPN and included in this study (n = 21). All baseline demographic data were similar



**Fig. 2.** A: Dissection of sub-segmental arterial supply to the tumour. B: Isolation of sub-segmental arterial supply to the tumour. C: Excision of the renal tumour.

**Table 1. Patient demographics**

Sample size	n = 21
Mean age (years)	56
Gender (male/female)	13/8
Body mass index >35	4 (19%)
Average Charlson comorbidity score	2.0

to that originally proposed by other RAPN studies. The mean age was 56, 62% of patients were male, 19% severely obese, and the average Charlson comorbidity score was 2 (Table 1).

Baseline information regarding tumour characteristics was also not significant, controlling for size, stage, and location. The average tumour size was 3.1 cm, and tumour staging of T1a was 76.2% (16/21) and T1b was 23.8% (5/21) (Table 2).

Of the 21 patients, 12 (57.1%) required no vascular clamping whatsoever, 7 (33.3%) required clamping of a single segmental artery and 2 (9.5%) required clamping of two segmental arteries. No patients required hilar clamping or were converted to open procedures. We achieved an average estimated blood loss of 158 cc, with a 9.2% average increase in creatinine postoperatively. Operating time and duration of hospital stay were short at 153 minutes and 2.2 days, respectively (Table 3).

We also examined pathological findings, including percentage clear cell renal cell carcinoma (RCC), papillary RCC, oncocytoma, angiomyolipoma, Furhman grading, and surgical margin status (Table 4).

## Discussion

Our findings suggest zero ischemia partial nephrectomy is a viable option at our institution with favourable results in terms of intra-operative blood loss and postoperative creatinine change compared to results from contemporary standard zero ischemia studies (University of Southern California Institute of Urology [USC]).<sup>20</sup> Furthermore, we observed a favourable trend towards decreased hospital stay and complication rates.

In applying the zero ischemia protocol, we found that 7/21 (33.3%) of our patients required clamping of one seg-

**Table 2. Tumour characteristics**

Sample size	n = 21
Tumour size (cm)	3.1
Tumour staging (T1a/T1b)	16/5
Side (left/right)	7/14
Location (upper/mid/lower)	8/4/9

mental artery and 2/21 (9.5%) required clamping of two segmental arteries. The remaining (12/21, 57.1%) required no vascular clamping. Compared to published results from USC Institute of Urology, we recorded favourable rates in all outcome measures of average estimated blood loss (158 vs. 206 cc), increases in creatinine (9.2% vs. 18%), OR time (153 vs. 264 minutes), and length of stay (2.2 vs. 3.9 days). This included zero operations requiring blood transfusion (at USC 21% of patients required blood transfusion), no intra-operative complications, 14% postoperative complications within 90 days (at USC 23%), and at the end of follow-up (mean 28 months), there was no evidence of cancer recurrence. Notably, there was no conversion to hilar clamping, no laparoscopic to open conversion, and no lost kidneys (Table 5).<sup>20</sup>

These results suggest very limited morbidity and subsequent mortality in applying the zero ischemia technique at our institution. Given that decreased blood loss is often cited as a reason to pursue hilar clamping, relatively small amounts of blood loss (mean 158 cc in our experience) is quite reassuring.<sup>21</sup>

Furthermore, there was a minimal increase in creatinine after surgery in our patients (mean 9.2%), indicating little effect on renal function postoperatively. Notably, postoperative renal function is multifactorial relative to preoperative function, preserved renal mass, and intra-operative renal ischemia.<sup>22</sup> Ischemia time, known to contribute to short-term acute renal failure and long-term end-stage renal disease, is the only surgically modifiable risk factor in patients presenting for partial nephrectomy.<sup>23</sup> Thus, limiting this ischemic time is imperative for preserving renal function and minimizing cellular damage to the kidneys.<sup>14,24</sup> Because of improved vascular micro-dissection techniques that allow for little to

**Table 3. Operative outcomes**

Sample size	n = 21
No vascular clamping	12 (57%)
Single segmental artery clamping (n)	7 (33%)
Double segmental artery clamping (n)	2 (10%)
Hilar clamping (n)	0
Laparoscopic to open conversion	0
Average estimated blood loss (cc)	158
Creatinine increase	9.2%
Operating room Time (minutes)	153
Length of stay (days)	2.2
Blood transfusions	0%
Postoperative complications within 90 days	14%

**Table 4. Pathological findings**

Sample size	n = 21
Clear cell RCC	15 (71%)
Papillary RCC	2 (9.5%)
Oncocytoma	2 (9.5%)
AML	2 (9.5%)
Furhman grade 1	2 (11.8%)
Furhman grade 2	13 (76.5%)
Furhman grade 3	2 (11.8%)
Positive surgical margin	2 (9.5%)
Cancer recurrence (mean follow-up 28 months)	0 (0%)

RCC: renal cell carcinoma; AML: angiomyolipoma.

**Table 5. Edmonton versus USC outcomes**

Outcome measure	Edmonton (RAPN only)	USC (LPN and RAPN)
Average estimated blood loss (cc)	158	206
Creatinine increase	9.2%	18%
Operating room time (minutes)	153	264
Length of stay (days)	2.2	3.9
Blood transfusions	0%	21%
Postoperative complications within 90 days	14%	23%

RAPN: robotic-assisted partial nephrectomy

no ischemia time, zero ischemia partial nephrectomies have demonstrated promising results in both our patient set and in contemporary studies with no intra-operative hilar clamping.<sup>15,18,25</sup>

At this point, our results suggest that we are achieving favourable outcomes compared to those proposed by contemporary landmark studies.<sup>18,20,25</sup> Consistently across renal function, blood loss and ancillary outcome measures, our results propose that our application of the zero ischemia technique may be a viable and effective alternative, if not an improvement, on the existing practice. In particular, we feel that a number of key points are crucial to improved perioperative blood loss, including the use of controlled hypotension. As well, careful attention to optimizing the pneumoperitoneum limited venous oozing at the tumour bed during the dissection and resection. Furthermore, ensuring a watertight closure of Gerota's fascia played a role in minimizing perioperative and postoperative blood loss, as well as controlling and preventing urine leak. In our experience, the robotic surgical system with 3 manipulating arms plus the camera port facilitates our technique by utilizing the third arm to control active hemostasis during surgical dissection and resection. Finally, individual patient factors should always be carefully assessed prior to proceeding with zero ischemia. For example, increased venous pressures in portal hypertension may overcome the pneumoperitoneum and increase blood loss, and should be a consideration for hilar clamping.

Notably, our experience represents an entirely RAPN series at a Canadian centre versus a combination LPN (74%) and RAPN (26%) series previously presented in the initial study.<sup>20</sup> Continued practice and research in this area will be necessary to demonstrate long-term outcomes in renal function and cancer control.<sup>19</sup>

Given that these are the preliminary findings at our institution, our conclusions are limited by a small sample size and relatively short-term follow-up with outcomes data. In the future, we will need to establish a database to assess long-term outcomes in the continued application of this technique compared against our laparoscopic, robotic, and open partial nephrectomy outcomes. Finally, other future research

on complex and hilar tumour management through vascular micro-dissection will also be important to study.<sup>26,27</sup>

## Conclusion

To our knowledge, we are the first study to review our initial experience with the zero ischemia protocol in robotic-assisted partial nephrectomies at a Canadian hospital. Our findings demonstrated favourable outcomes compared to those presented in contemporary studies. We also observed a trend towards decreased hospital stay, blood loss, and complication rates than previously described. Further long-term research will need to confirm our preliminary findings.

**Competing interests:** Authors declare no competing financial or personal interests.

This paper has been peer-reviewed.

## References

- Gill IS, Aron M, Gervais DA, et al. Clinical practice. Small renal mass. *N Engl J Med* 2010;362:624-34. <http://dx.doi.org/10.1056/NEJMc0910041>
- Cohen HT, McGovern FJ. Renal-cell carcinoma. *N Engl J Med* 2005;353:2477-90. <http://dx.doi.org/10.1056/NEJMra043172>
- Leslie S, Goh AC, Gill IS. Partial nephrectomy—contemporary indications, techniques and outcomes. *Nat Rev Urol* 2013;10:275-83.
- Choi JD, Park JW, Lee HW, et al. A comparison of surgical and functional outcomes of robot-assisted versus pure laparoscopic partial nephrectomy. *JSL* 2013;17:292-9.
- Van Poppel H. Efficacy and safety of nephron-sparing surgery. *Int J Urol* 2010;17:314-26. <http://dx.doi.org/10.1111/j.1442-2042.2010.02482.x>
- Patel C, Ahmed A, Ellsworth P. Renal cell carcinoma: A reappraisal. *Urol Nurs* 2012;32:182-90; quiz 191.
- Nadu A, Kitrey N, Mor Y, et al. Laparoscopic partial nephrectomy: Is it advantageous and safe to clamp the renal artery? *Urology* 2005;66:279-82. <http://dx.doi.org/10.1016/j.urology.2005.03.016>
- Mathieu R, Verhoest G, Droupy S, et al. Predictive factors of complications after robot-assisted laparoscopic partial nephrectomy: A retrospective multicentre study. *BJU Int* 2013;112:E283-9. <http://dx.doi.org/10.1111/bju.12222>
- Kobayashi Y, Saika T, Manabe D, et al. The benefits of clamping the renal artery in laparoscopic partial nephrectomy. *Acta Med Okayama* 2008;62:269-73.
- Bernardo NO, Gill IS. Laparoscopic partial nephrectomy: Current status. *Arch Esp Urol* 2002;55:868-80.
- Gill IS, Eisenberg MS, Aron M, et al. "Zero ischemia" partial nephrectomy: Novel laparoscopic and robotic technique. *Eur Urol* 2011;59:128-34. <http://dx.doi.org/10.1016/j.eururo.2010.10.002>
- Patil MB, Gill IS. Zero-ischaemia robotic and laparoscopic partial nephrectomy (PN). *BJU Int* 2011;108:780-92.
- Koo HJ, Lee DH, Kim IY. Renal hilar control during laparoscopic partial nephrectomy: To clamp or not to clamp. *J Endourol* 2010;24:1283-7. <http://dx.doi.org/10.1089/end.2009.0123>
- Thompson RH, Lane BR, Lohse CM, et al. Every minute counts when the renal hilum is clamped during partial nephrectomy. *Eur Urol* 2010;58:340-5. <http://dx.doi.org/10.1016/j.eururo.2010.05.047>
- Hung AJ, Cai J, Simmons MN, et al. «Trifecta» in partial nephrectomy. *J Urol* 2013;189:36-42. <http://dx.doi.org/10.1016/j.juro.2012.09.042>
- Tanagho YS, Bhayani SB, Sandhu GS, et al. Renal functional and perioperative outcomes of off-clamp versus clamped robot-assisted partial nephrectomy: Matched cohort study. *Urology* 2012;80:838-43. <http://dx.doi.org/10.1016/j.urology.2012.04.074>
- Simone G, Ferriero M, Papalia R, et al. Zero-ischemia minimally invasive partial nephrectomy. *Curr Urol Rep* 2013;14:465-70. <http://dx.doi.org/10.1007/s11934-013-0359-0>
- Rais-Bahrami S, George AK, Herati AS, et al. Off-clamp versus complete hilar control laparoscopic partial nephrectomy: Comparison by clinical stage. *BJU Int* 2012;109:1376-81. <http://dx.doi.org/10.1111/j.1464-410X.2011.10592.x>

19. Pena JA, Oliveira M, Ochoa DC, et al. The road to real zero ischemia for partial nephrectomy. *J Endourol* 2013;27:936-42. <http://dx.doi.org/10.1089/end.2012.0676>
20. Gill IS, Patil MB, Abreu AL, et al. Zero ischemia anatomical partial nephrectomy: A novel approach. *J Urol* 2012;187:807-14. <http://dx.doi.org/10.1016/j.juro.2011.10.146>
21. Guillonneau B, Bermudez H, Gholami S, et al. Laparoscopic partial nephrectomy for renal tumor: Single center experience comparing clamping and no clamping techniques of the renal vasculature. *J Urol* 2003;169:483-6. [http://dx.doi.org/10.1016/S0022-5347\(05\)63939-0](http://dx.doi.org/10.1016/S0022-5347(05)63939-0)
22. Schmid M, Abd-El-Barr AE, Gandaglia G, et al. Predictors of 30-day acute kidney injury following radical and partial nephrectomy for renal cell carcinoma. *Urol Oncol* 2014;32:1259-66. <http://dx.doi.org/10.1016/j.urolonc.2014.05.002>. Epub 2014 Aug 14.
23. Lane BR, Babineau DC, Poggio ED, et al. Factors predicting renal functional outcome after partial nephrectomy. *J Urol* 2008;180:2363-8; discussion 2368-9. <http://dx.doi.org/10.1016/j.juro.2008.08.036>
24. Becker F, Van Poppel H, Hakenberg OW, et al. Assessing the impact of ischaemia time during partial nephrectomy. *Eur Urol* 2009;56:625-34. <http://dx.doi.org/10.1016/j.eururo.2009.07.016>
25. Simone G, Papalia R, Guaglianone S, et al. Zero ischemia laparoscopic partial nephrectomy after super-selective transarterial tumor embolization for tumors with moderate nephrometry score: Long-term results of a single-center experience. *J Endourol* 2011;25:1443-6. <http://dx.doi.org/10.1089/end.2010.0684>
26. Borofsky MS, Gill IS, Hemal AK, et al. Near-infrared fluorescence imaging to facilitate super-selective arterial clamping during zero-ischaemia robotic partial nephrectomy. *BJU Int* 2013;111:604-10. <http://dx.doi.org/10.1111/j.1464-410X.2012.11490.x>
27. Desai MM, de Castro Abreu AL, Leslie S, et al. Robotic partial nephrectomy with superselective versus main artery clamping: A retrospective comparison. *Eur Urol* 2014;66:713-9. <http://dx.doi.org/10.1016/j.eururo.2014.01.017>. Epub 2014 Jan 25.

---

**Correspondence:** Dr. Blair St. Martin, Division of Urology, Department of Surgery, University of Alberta, Edmonton, AB; [smartin@ualberta.ca](mailto:smartin@ualberta.ca)