

# Diagnosis of testicular torsion using near infrared spectroscopy: A novel diagnostic approach

Babak Shadgan, MD, MSc, PhD;\* Mehdi Fareghi, MD;† Lynn Stothers, MD, FRCSC,\*  
Andrew Macnab, MD, FRCPC, FRCPC, FCAHS;‡ A.M. Kajbafzadeh, MD†

\*Department of Urologic Sciences, University of British Columbia, Vancouver, BC; †Pediatric Urology Research Center, Tehran University of Medical Sciences, Islamic Republic of Iran; ‡Department of Pediatrics, Department of Urologic Sciences, University of British Columbia, Vancouver, BC

Cite as: *Can Urol Assoc J* 2014;8(3-4):e249-52. <http://dx.doi.org/10.5489/auaj.1672>  
Published online April 14, 2014.

## Abstract

We report a case of testicular torsion in a 14-month old boy. Testicular ischemia was suspected based on history and clinical presentations. The patient was referred following 24 hours of left acute scrotum. Erythema, swelling and tenderness associated with nausea and emesis were present, but the patient was not febrile. We used a spatially resolved near-infrared spectroscopy (SR-NIRS) device to study and compare the tissue saturation index (TSI) on both right and left spermatic cords. The TSI was significantly reduced in the left side. Both testicles were surgically explored and the left testis was found non-viable with a 1080-degree intravaginal torsion. NIRS monitoring of spermatic cord oxygen saturation appears feasible as a non-invasive bedside optical method to identify testicular torsion.

## Introduction

Acute spermatic cord torsion or testicular torsion is a well-known acute scrotum in children and adolescents. It results in twisting of the spermatic vessels with subsequent reduction or interruption of testicular blood supply, a condition that requires prompt diagnosis and urgent surgical exploration.<sup>1</sup> The classic presentation of testicular torsion includes sudden, severe unilateral scrotal pain, which can start on activity or during sleep. Nausea and vomiting may occur, and delayed cases may develop severe scrotal edema. Physical examination findings include an abnormal testicular position and tenderness, and the cremasteric reflex is usually absent in patients over 2 years old.

This condition is considered a surgical emergency due to the risk of testicular loss. Surgical exploration of any acute scrotum has been recommended by some authors to prevent or confirm torsion.<sup>2</sup> Radionuclide imaging, although fairly

sensitive, is no longer recommended due to being time consuming and having low specificity.<sup>3</sup> Colour Doppler ultrasonography (CDU) has been shown to have high sensitivity and specificity for spermatic cord torsion;<sup>4</sup> however, intermittent torsion, spontaneous detorsion and atypical cases give false negative results, which significantly decrease reliability and clinical relevance of this method.<sup>5</sup> Furthermore the use of CDU in the diagnosis of acute scrotum is limited by its availability and the time required to perform this type of investigation as it requires specialized sonographers to operate and interpret the results. High-resolution ultrasonography (HRUS) of the spermatic cord to detect the twisted section has also been suggested and used in suspicious cases to prevent unnecessary surgeries.<sup>6</sup>

There have been reports of near-infrared spectroscopy (NIRS) application to study testicular hemodynamics in boars<sup>7</sup> and to detect testicular torsion in adults.<sup>8-11</sup> NIRS is a non-invasive optical technique that uses light in the near-infrared spectrum to monitor tissue oxygenation and hemodynamics by measuring local changes in the concentration of oxygenated (O<sub>2</sub>Hb), deoxygenated (HHb), total (tHb) hemoglobin and tissue oxygen saturation (TSI%).<sup>12</sup> Recent studies have used NIRS to investigate urologic conditions.<sup>13-26</sup>

## Case report

The patient was a 14-month old boy, referred to the pediatric urology clinic with left scrotal swelling, erythema and tenderness. He was irritable, had nausea and vomiting but was afebrile. Visited by a local physician a day before referral, he was prescribed antibiotics and analgesic agents, but was unresponsive to treatment. Physical examination of the genitalia revealed erythema and swelling of the left scrotal wall with left testicular tenderness and an intact cremasteric reflex. Body temperature was 37.2°C. Urinalysis showed white blood count as 1-2; red blood count as negative;

protein as 1+ and urine culture was ultimately negative. Urogenital ultrasonography reported a right undescended testis at the external inguinal ring with normal size and echogenicity. The left testis was enlarged with a normal echogenicity. Although direct evidence of testicular torsion was not observed, it did not rule the diagnosis out. CDU reported equivocal findings with a trend to epididymitis.

NIRS was used to compare the tissue saturation index (TSI%) of the right and left spermatic cords (Fig. 1).<sup>15</sup>

With the child supine, a miniature spatially resolved NRIS (SR-NIRS) device (PortaMon, Artinis, The Netherlands) was placed over each spermatic cord in turn with the near-infrared light emitter array and photodiode detector apposed to the skin over the cord. While the SR-NIRS was held in place for 1 minute, data were collected in real time from the spermatic cord and the TSI% was calculated. As a control measure, a similar comparison of tissue oxygen saturation was made between the vastus lateralis muscle of the right and left quadriceps. The left spermatic cord TSI% was significantly lower than the measurement from the right cord (75.6% vs. 68.8%), while the left and right quadriceps TSI% were comparable (75.5% vs. 75.2%) (Fig. 2).

The patient was transferred to the operation room. The surgical exploration of the scrotum revealed a non-viable left testis with 1080-degree intravaginal torsion (Fig. 3). Attempting to save the testis via detorsion was not feasible, we performed a left orchidectomy. The right testis was normal and secured via scrotal orchidopexy.

## Discussion

NIRS is an established non-invasive optical technique used to transcutaneously monitor changes in hemoglobin concentration in the microcirculation in real time in a variety of scientific and biomedical applications.<sup>16-21</sup>

The science of NIRS hinges on some of the fundamental principles of pulse oximetry as they relate to the transmission of light through living tissues and the absorption of light by tissue chromophores (naturally occurring compounds that absorb light [e.g., hemoglobin]). NIRS units use lasers or light-emitting diodes to transmit pulses of multiple wavelengths of light in the near infrared spectrum into tissues and optical sensors that detect returning photons after absorption by tissue chromophores. The changes in absorption at discrete wavelengths generate raw optical data that can be converted by mathematical software algorithms into real-time concentration changes for each chromophore using a modification of the Beer-Lambert law. Several investigators have reported the relevance of NIRS as a potential entity for monitoring the blood supply of the testis; however, none of them used a NIRS device with spatially resolved optical geometry.<sup>7-11</sup> SR-NIRS is an important evolution of NIRS as it enables an absolute measure of tissue oxygen saturation to

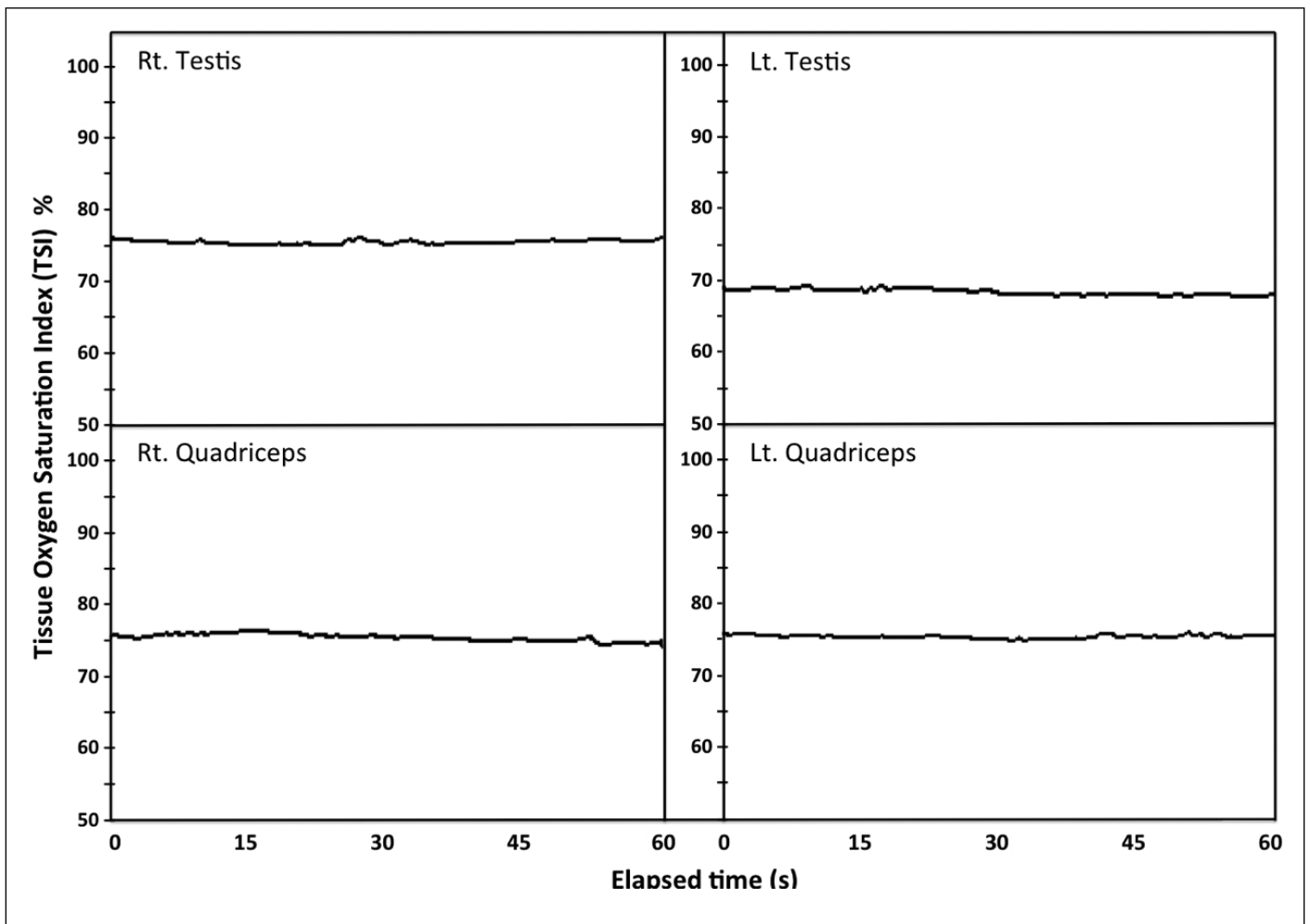


**Fig.1.** The wireless near-infrared spectroscopy device positioned over the right spermatic cord for direct measurement of local tissue saturation index %.

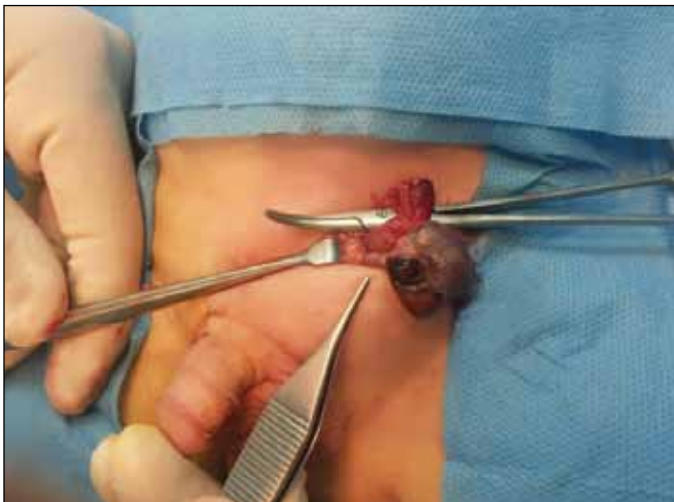be obtained. Spatially resolved devices are configured with 2 or more emitters positioned at different distances from the detector, which allow the measurement of light intensity as a function of distance. With appropriate algorithms, the ratio of oxygenated to total tissue hemoglobin can be calculated from which an absolute measurement of tissue oxygen saturation is made.<sup>24,25</sup>

We found that spermatic cord tissue oxygenation is reduced in the presence of demonstrated testicular torsion. Our case demonstrated this for the following reasons: the oxygenation was made in a young child; it used a newly available absolute measure of oxygenation; the data were available in real time; and the technique used a low-cost non-invasive optical technique with established relevance as a means of monitoring changes in hemodynamics and oxygenation. A number of NIRS devices have been used in the context of urology and for other biomedical applications; some are experimental, but a range of commercial devices exist, including the one used in this study.<sup>24,27</sup>

We recognize the limitation that this is a single case report. However, the reports of prior investigators of the potential for NIRS monitoring to contribute to the evalua-



**Fig. 2.** Tissue saturation index (TSI) % difference between the affected (left) versus the normal testis (right), while TSI% values of the right and left quadriceps muscles are comparable.



**Fig. 3.** Surgical exploration of the scrotum confirms a non-viable left testis with 1080-degree intravaginal torsion.

tion of testicular hemodynamics support our suggestion that SR-NIRS assessment of spermatic cord tissue oxygenation should be explored further.

### Conclusion

This observation demonstrates the feasibility of using SR-NIRS to compare an absolute measure of tissue oxygenation in the spermatic cord as an adjunct to diagnose testicular torsion and associated testicular hypoxia. With further studies, this technique may offer a reliable, sensitive, safe, non-invasive, non-expensive, real time and rapid diagnostic option at the bedside, and could also be considered for monitoring the evolution of this condition and response to treatment.

**Competing interests:** Dr. Shadgan, Dr. Fareghi, Dr. Stothers, Dr. Macnab, and Dr. Kajbafzadeh all declare no competing financial or personal interests.

This paper has been peer-reviewed.

## References

- Riaz-Ul-Haq M, Mahdi DE, Elhassan EU. Neonatal testicular torsion: A review article. *Iran J Pediatr* 2012;22:281-9.
- Sidler D, Brown RA. A 25 year review of the acute scrotum in children. *S Afr Med J* 1997;87:1696-8.
- Nussbaum Blask AR, Bulas D, Shalaby-Rana E, et al. Color Doppler sonography and scintigraphy of the testis: A prospective, comparative analysis in children with acute scrotal pain. *Pediatr Emerg Care* 2002;18:67. <http://dx.doi.org/10.1097/00006565-200204000-00001>
- Stehr M, Boehm R. Critical validation of colour Doppler ultrasound in diagnosis of acute scrotum in children. *Eur J Pediatr Surg* 2003;13:386-92. <http://dx.doi.org/10.1055/s-2003-44728>
- Dunne PJ, O'Loughlin BS. Testicular torsion: Time is the enemy. *Aust N Z J Surg* 2000;70:441-2. <http://dx.doi.org/10.1046/j.1440-1622.2000.01853.x>
- Kalfa N, Veyrac C, Baud C, et al. Ultrasonography of the spermatic cord in children with testicular torsion: Impact on the surgical strategy *J Urol* 2004;172:1692-5. <http://dx.doi.org/10.1097/01.ju.0000138477.85710.69>
- Colier WN, Froeling FM, de Vries JD, et al. Measurement of the blood supply to the abdominal testis by means of near infrared spectroscopy. *Eur Urol* 1995;27:160-6.
- Capraro GA, Mader TJ, Coughlin BF, et al. Feasibility of using near-infrared spectroscopy to diagnose testicular torsion: An experimental study in sheep. *Ann Emerg Med* 2007;49:520-5. <http://dx.doi.org/10.1016/j.annemergmed.2006.06.041>
- Hallacoglu B, Matulewicz RS, Paltiel HJ, et al. Noninvasive assessment of testicular torsion in rabbits using frequency-domain near-infrared spectroscopy: prospects for pediatric urology. *J Biomed Opt* 2009;14:054027. <http://dx.doi.org/10.1117/1.3253318>
- Aydogdu O, Burgu B, Gocun PU, et al. Near infrared spectroscopy to diagnose experimental testicular torsion: Comparison with Doppler ultrasound and immunohistochemical correlation of tissue oxygenation and viability. *J Urol* 2012;187:744-50. <http://dx.doi.org/10.1016/j.juro.2011.09.145>
- Burgu B, Aydogdu O, Huang R, et al. Pilot feasibility study of transscrotal near infrared spectroscopy in the evaluation of adult acute scrotum. *J Urol* 2013;190:124-9. <http://dx.doi.org/10.1016/j.juro.2013.01.080>
- Ferrari M, Mottola L, Quaresima V. Principles, techniques and limitations of near infrared spectroscopy. *Can J Appl Physiol* 2004;29:463-87. <http://dx.doi.org/10.1139/h04-031>
- Shadgan B, Afshar K, Stothers L, et al. Near-infrared spectroscopy of the bladder: A new technique for studying lower urinary tract function in health and disease. *Proc. SPIE 7548, Photonic Therapeutics and Diagnostics VI*, 75480U (March 02, 2010); <http://dx.doi.org/10.1117/12.841066>
- Macnab AJ, Shadgan B, Stothers L. The evolution of wireless near infrared spectroscopy applications in urology and rationale for clinical use. *J Near Infrared Spectroscopy* 2012;20:57-73. <http://dx.doi.org/10.1255/jnirs.963>
- Shadgan B, Reid WD, Gharakhanlou R, et al. Wireless near-infrared spectroscopy of skeletal muscle oxygenation and hemodynamics during exercise and ischemia. *Spectroscopy* 2009;23:233-41. <http://dx.doi.org/10.1155/2009/719604>
- Ferrari M, Binzoni T, Quaresima V. Oxidative metabolism in muscle. *Phil Trans R Soc Lond B* 1997;352:677-83. <http://dx.doi.org/10.1098/rstb.1997.0049>
- Van Beekvelt MC, Colier WN, Wevers RA, et al. Performance of near-infrared spectroscopy in measuring local oxygen consumption and blood flow in skeletal muscle. *J Appl Physiol* 2001;90:511-9.
- Wolf M, Ferrari M, Quaresima V. Progress of near-infrared spectroscopy and topography for brain and muscle clinical applications. *J Biomed Optics* 2007;12:062104. <http://dx.doi.org/10.1117/1.2804899>
- Hamaoka T, McCully KK, Quaresima V, et al. Near-infrared spectroscopy/imaging for monitoring muscle oxygenation and oxidative metabolism in healthy and diseased humans. *J Biomed Optics* 2007;12:062105. <http://dx.doi.org/10.1117/1.2805437>
- Contini D, Zucchelli I, Spinelli L, et al. Review: Brain and muscle near infrared spectroscopy/imaging techniques. *J NIRS* 2012;20:15-27.
- Boushel R, Langberg H, Olesen J, et al. Monitoring tissue oxygen availability with near infrared spectroscopy (NIRS) in health and disease. *Scand J Med Sci Sports* 2001;11:213-22. <http://dx.doi.org/10.1034/j.1600-0838.2001.1110404.x>
- Pannek J. Editorial Comment on: Classification of Male Lower Urinary Tract Symptoms Using Mathematical Modeling and a Regression Tree Algorithm of Noninvasive Near-Infrared Spectroscopy Parameters. *Eur Urol* 2010;57:332-3. <http://dx.doi.org/10.1016/j.eururo.2009.05.005>
- Macnab AJ, Shadgan B, Stothers L. The evolution of wireless near infrared spectroscopy: applications in urology and rationale for clinical use. *J NIRS* 2013;20:57-73.
- Macnab AJ, Shadgan B. Biomedical applications of wireless continuous wave near infrared spectroscopy. *Biomedical Spectroscopy and Imaging* 2012;1:205-22.
- Shadgan B, Macnab AJ, Stothers L. Optical diagnosis of interstitial cystitis/painful bladder syndrome. *Proc. SPIE 7548, Photonic Therapeutics and Diagnostics* 856510 (2013). <http://dx.doi.org/10.1117/12.1000235>
- Paltiel HJ, Rupich RC, Babcock DS. Maturational changes in arterial impedance of the normal testis in boys: Doppler sonographic study. *AJR Am J Roentgenol* 1994;163:1189-93. <http://dx.doi.org/10.2214/ajr.163.5.7976898>
- Stothers L, Shadgan B, Macnab AJ. Urologic applications of infrared spectroscopy (NIRS). *Can J Urol* 2008;15:4399-409.

**Correspondence:** Dr. Babak Shadgan, Department of Urologic Sciences, University of British Columbia, Vancouver, BC; [shadgan@gmail.com](mailto:shadgan@gmail.com)