

Fungus ball in the urinary tract: A rare entity

Valentin Praz, MD; Rodolfo Burruni, MD; Florian Meid, MD; Marc Wisard, MD; Patrice Jichlinski, MD; Thomas Tawadros, MD, PhD

Centre Hospitalier Universitaire Vaudois, Service of Urology, Lausanne, Switzerland

Cite as: *Can Urol Assoc J* 2014;8(1-2):e118-20. <http://dx.doi.org/10.5489/cuaj.1254>
Published online February 12, 2014.

Abstract

A fungal mass in the urinary tract (fungus ball), mainly occurring in compromised patients, is a rare and dangerous complication of candiduria. We report 2 cases of fungus ball associated with hydronephrosis and sepsis. As reported in the literature, we treated the first patient by prompt relief of obstruction by nephrostomy and local and systemic antifungal agent. The second patient failed to respond to this treatment due to a distal ureteral stenosis and required open surgery with fungus ball removal and ureteral reimplantation. Despite a large success in urinary tract drainage with antifungal treatments, some cases need a modified approach due to anatomical modification.

Case 1

The first patient was a 63-year-old man with a complicated hepatic transplantation. After a fungal peritonitis, he developed fever, back pain and acute renal failure. Radiological analysis highlighted bilateral hydronephrosis associated with hyperechogenic pyelic masses (Fig. 1). Urinary and blood cultures revealed the presence of *Candida tropicalis*. Bilateral percutaneous nephrostomy catheters were introduced, and the patient was successfully treated with intermittent local irrigation (fluconazol 300 mg in 500 mL NaCl 0.9% once per day for 12 hours) and continuous systemic antifungal agent (fluconazol 200 mg/day).

Case 2

The second patient was an 84-year-old man with severe uncontrolled diabetes mellitus, a neurogenic bladder with a permanent Foley catheter, and a bladder diverticulotomy for infected intravesical stones. He was hospitalized with

back pain (right side) associated with fever. An abdominal scan demonstrated a distal ureteral obstruction of unknown origin with a right uretero-pyelocalic dilatation. A percutaneous right nephrostomy was introduced. Urine and blood cultures demonstrated a *Candida albicans* infection. After introduction of a continuous systemic (fluconazol 200 mg/day) and local antifungal treatments (fluconazol 300 mg in 250 mL NaCl 0.9% once per day for 12 hours), we completed the morphological analysis. Opacification through nephrostomy confirmed the presence of a distal partial ureteral obstruction (Fig. 2) and cystoscopy showed a white soft tissue mass protruding from the right ureteral meatus. We performed irrigation at a low rate due to a partial obstruction of the right ureteral orifice. The clinical and biological evolution was unfavourable, even after 1 week of treatment. A new opacification was realized, at low pressure, demonstrating the persistence of the fungus ball without any significant size change. Finally, surgical cystotomy was performed with manual removal of the fungus ball (Fig. 2). A right ureteral reinsertion was carried out to avoid recurrence due to a putative stenotic right uretero-vesical junction (Fig. 2) following a psoas bladder hitch procedure. The prognosis was excellent and the patient is currently visiting our clinic for Foley catheter changing.

Discussion

Candiduria is a frequent observation in hospitalized patients.¹ It is most common in patients in intensive care units, patients with indwelling catheters or premature infants.² Fungal infection of the urinary tract was first reported by Lundquist in 1931 in a series of 17 patients.³ The common underlying diseases of candiduria include diabetes mellitus, urinary tract abnormalities, urinary catheter, prolonged antibiotic therapy, steroids, immunosuppressive therapy, malignancy and malnutrition.¹ Complex urinary tract fungal infections are often associated with systemic dissemination which induces a high mortality rate.¹

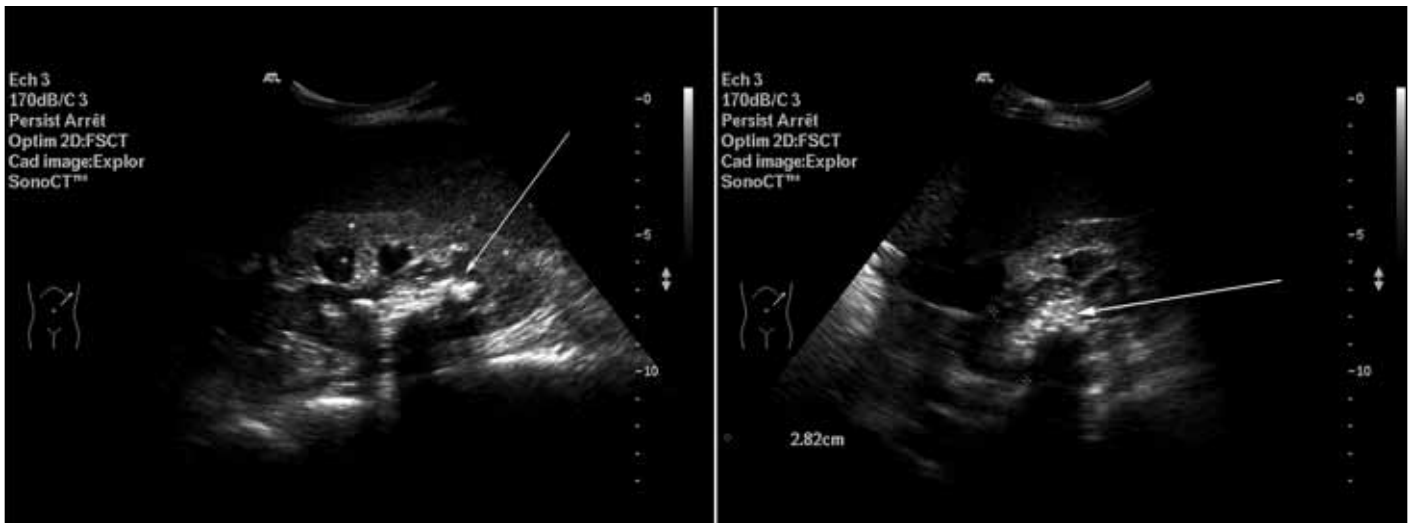


Fig. 1. Ultrasound analysis revealed bilateral hydronephrosis with pyelic hyperechogenic material.

A fungus ball can originate from agglutination of a necrotic tissue nucleus (papillary necrosis), mucous debris and foreign or lithiasic debris; this can then lead to a urinary tract obstruction and hydronephrosis, which is a very rare complication of candiduria. The most frequently observed pathogens are *C. albicans* and *C. tropicalis*,¹ but *Aspergillus flavus*,⁴ *Aspergillus nidulans*,⁴ *Rhizopus*⁵ and *C. parapsilosis*⁶ also are reported.

Urosepsis due to fungal mass should be evaluated in compromised patients with unspecific radiological findings; urine and blood cultures should be promptly carried out. In upper urinary obstructive cases, drainage (nephrostomy and/or ureteral stent) should provide a better access for the collection of material for microscopic study.¹ The most described therapeutic approach is urinary drainage by a nephrostomy and/or a ureteral catheter with systemic and local antifungal administration.^{1,7-9} Nephrostomy also provides access to percutaneously remove the fungus ball^{1,7-9} and manually drain it via ureteroscopy.⁴

The most commonly used antifungal agents are fluconazole and amphotericin B (AmpB) deoxycholate, because other drugs have extremely low urine concentrations.¹⁰ AmpB is considered the drug of choice to treat systemic fungal infections. However, nephrotoxicity is a major complication associated with the use of AmpB and patients do not always tolerate local irrigation of AmpB.¹⁰ We administered systemic and local (by irrigation) fluconazol, which was well-tolerated in both cases. We should also emphasize that local irrigation should not be performed at a high flow rate so as not to increase pressure in the urinary tract.

In the management of obstructive urosepsis, prompt drainage of the urinary tract should be performed.¹ Investigation for a fungal ball should be performed, especially in cases with an uncommon radiological finding. A precise characterization of the anatomical localization is absolutely necessary to undergo the most efficient management. As described in the second case, due to an obstruction located at the vesi-

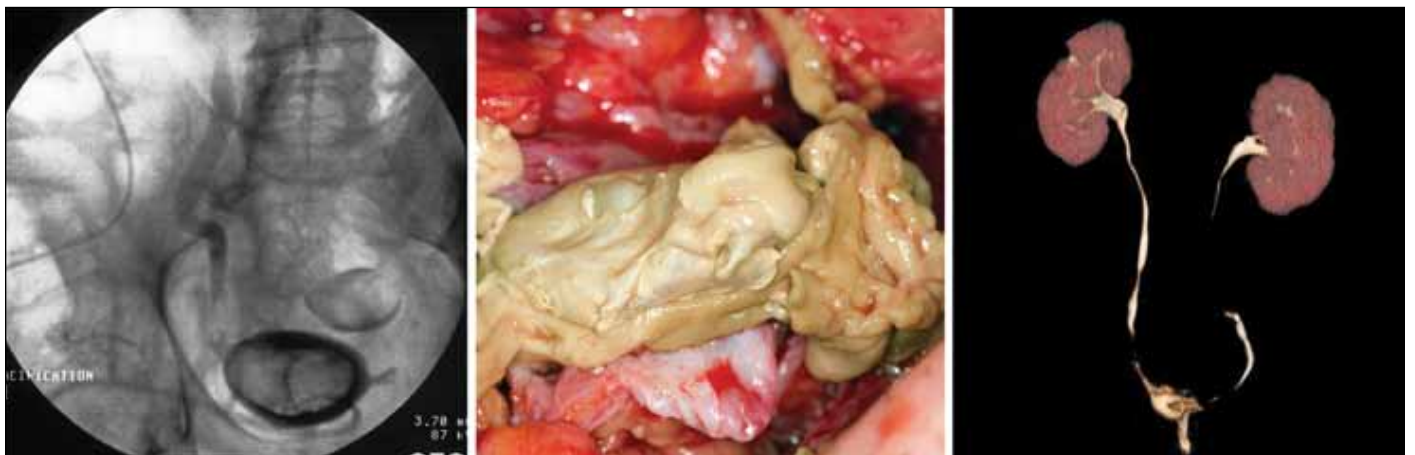

Fig. 2. A: Right nephrostogram showed a distal ureteral defect associated with a large defect in the bladder and a diverticulum B: Fungus ball relief demonstrated a white soft tissue. C: A computed tomography scan reconstruction 2 months after right reimplantation.

coureteral junction, a semi-conservative approach would not have been helpful. The obstruction could have been due to a chronic inflammation or an anatomical modification due to detrusor hypertrophy. The location of the fungus ball inside the urinary tract may also have been a contributing factor. The pyelic space is larger and more compliant than the ureter or the vesicoureteral junction. Therefore, masses in the renal pelvis are easier to access for urine flow and local irrigations. Recently, Davis and colleagues reported that in the same situation, with a fungus ball located at the vesico-ureteral junction, endoscopic management was successful with resection of the vesico-ureteral orifice.¹¹ We did not proceed in the same way to avoid putative removal of the insertion or early/late stenosis of the ureteral orifice in a patient with a neurogenic bladder and a hypertrophied detrusor with previous surgery for bladder diverticules. Davis and colleagues demonstrated that an endoscopical minimal invasive management is a valuable option and could have been used before surgical ureteral reimplantation.

Conclusion

The management of fungal urinary tract obstruction should be based on a clinical, radiological and infectious approach with a precise anatomical characterization. This would be a major step forward for better and more specific treatment.

Competing interests: Dr. Praz, Dr. Burrini, Dr. Meid, Dr. Wisard, Dr. Jichlinski and Dr. Tawadros all declare no competing financial or personal interests.

This paper has been peer-reviewed.

References

1. Wainstein MA, Graham RC Jr, Resnick MI. Predisposing factors of systemic fungal infections of the genitourinary tract. *J Urol* 1995;154:160-3. [http://dx.doi.org/10.1016/S0022-5347\(01\)67255-0](http://dx.doi.org/10.1016/S0022-5347(01)67255-0)
2. Sobel JD, Fisher JF, Kauffman CA, et al. Candida urinary tract infections-epidemiology. *Clin Infect Dis* 2011;52:S433-6. <http://dx.doi.org/10.1093/cid/cir109>
3. Lundquist CW. On primary mycosis of the kidney. *Brit J Urol* 1931;3:1-13. 6. <http://dx.doi.org/10.1111/j.1464-410X.1931.tb11081.x>
4. Smaldone MC, Cannon GM, Benoit RM. Case report: bilateral ureteral obstruction secondary to Aspergillus bezoar. *J Endourol* 2006;20:318-20. <http://dx.doi.org/10.1089/end.2006.20.318>
5. Palacio-Bedoya F, Cadena JA, Thompson GR, et al. A noninvasive renal fungus ball caused by Rhizopus - a previously unreported manifestation of zygomycosis. *Med Mycol* 2010;48:866-9. <http://dx.doi.org/10.3109/13693781003694796>
6. Kamimura Y, Segawa T, Yamaguchi K, et al. A case of Candida parapsilosis fungal balls in the urinary tract associated with a retrocaval ureter [in Japanese]. *Hinyokika Kyo* 2010;56:443-5.
7. Chung BH, Chang SY, Kim SI, et al. Successfully treated renal fungal ball with continuous irrigation of fluconazole. *J Urol* 2001;166:1835-6. [http://dx.doi.org/10.1016/S0022-5347\(05\)65693-5](http://dx.doi.org/10.1016/S0022-5347(05)65693-5)
8. Karpman E, Kurzrock EA, Low RK. Percutaneous nephroscopic removal of obstructing fungal bezoars and endopyelotomy in an infant. *J Urol* 2003;169:1499-500. <http://dx.doi.org/10.1097/JU.0000053501.90725.29>
9. Shimada S, Nakagawa H, Shintaku I, et al. Acute renal failure as a result of bilateral ureteral obstruction by Candida albicans fungus balls. *Int J Urol* 2006;13:1121-2. <http://dx.doi.org/10.1111/j.1442-2042.2006.01509.x>
10. Altmannsberger P, Holler E, Andreesen R, et al. Amphotericin B deoxycholate: no significant advantage of a 24 h over a 6 h infusion schedule. *J Antimicrob Chemother* 2007;60:180-2. <http://dx.doi.org/10.1093/jac/dkm147>
11. Davis NF, Smyth LG, Mulcahy E, et al. Ureteric obstruction due to fungus-ball in a chronically immunosuppressed patient. *Can Urol Assoc J* 2013;7:E355-8.

Correspondence: Dr. Thomas Tawadros, Centre Hospitalier Universitaire Vaudois, Service of Urology, BH-16, CHUV-1011 Lausanne, Switzerland; thomas.tawadros@gmail.com