

**Transrectal ultrasound-guided prostate biopsies vs. MRI-ultrasound fusion targeted biopsies: Who are the best candidates?**

Elsa Bey<sup>1</sup>; Olivier Gaget<sup>2</sup>; Jean-Luc Descotes<sup>1,3</sup>; Quentin Franquet<sup>1</sup>; Jean-Jacques Rambeaud<sup>1,4</sup>; Jean-Alexandre Long<sup>1,3,4</sup>; Gaëlle Fiard<sup>1,3,4</sup>

<sup>1</sup>Department of Urology, Grenoble University Hospital; <sup>2</sup>Department of Public Health, Grenoble University Hospital; <sup>3</sup>CNRS, TIMC-IMAG; <sup>4</sup>Université Grenoble Alpes; Grenoble, France

*Acknowledgements: The authors wish to thank the radiology department, and more specifically Dr. Noëlie Hohn, for their help with this work.*

**Cite as:** *Can Urol Assoc J* 2017 Dec. 1; Epub ahead of print.  
<http://dx.doi.org/10.5489/cuaj.4571>

**Published online December 1, 2017**

\*\*\*

**Abstract**

**Introduction:** The aim of this study was to compare the results of ultrasound-guided prostate biopsies (US-PB) and magnetic resonance imaging ultrasound fusion biopsies (MRI-PB) in two contemporary cohorts, and to describe the parameters orienting the choice of technique.

**Methods:** Two contemporary cohorts of patients undergoing US-PB or MR-PB using the Urostation<sup>®</sup> (Koelis, Grenoble, France) between November 2010 and July 2015 were analyzed retrospectively. Patients with metastatic cancer or recurrence after treatment, saturation biopsies, and US-PB performed after a negative MRI were excluded. Comparison of populations, biopsy results, and clinical and biological parameters guiding the choice of technique were studied on multivariate analysis (logistic regression) taking into account the following confounding factors: age, prostate-specific antigen (PSA) rate, prostatic volume, number of previous biopsies, and abnormal digital rectal examination.

**Results:** One hundred fourteen patients were included in the US-PB group and 118 in the MR-PB group. Prostate cancer was diagnosed among 65 patients in the US-PB group (detection rate 57%) and 70 patients in the MR-PB group (detection rate 59.3%) (odds ratio [OR] 3.00; 95% confidence interval [CI] 1.52–6.17;  $p=0.002$ ). Among the cancers diagnosed in the MR-PB group, 21 were diagnosed by the two targeted biopsy cores only (15.5%). Patients undergoing MR-PB were significantly younger ( $p=0.0005$ ), with a higher number of previous biopsy sessions ( $p<10^{-7}$ ) and larger prostate volume ( $p=0.001$ ). PSA rate alone ( $p=0.23$ ) and digital rectal examination ( $p=0.48$ ) did not significantly interfere with the choice of a technique.

**Conclusions:** Younger patients with larger prostates and prior negative biopsy were more likely to be offered the MR-PB technique. On multivariate analysis, the detection rate was higher in the MR-PB group.

## Introduction

An optimal prostate cancer screening program would detect only significant cancers, threatening to shorten life expectancy or decrease quality of life, without overdiagnosing indolent cancers and exposing patients to unjustified treatment induced morbidity. Such a screening strategy relies on the use of efficient diagnostic procedures.

Ultrasound-guided randomized prostate biopsies have shown their limits by exposing patients to overdiagnosis (non-significant cancer) or underdiagnosis (missed cancer due to randomized procedure)<sup>1</sup>. Prostatic Multi-Parametric Magnetic Resonance Imaging (MRI) has proved helpful in selecting patients awaiting prostate biopsies by showing high Gleason score lesions<sup>2–6</sup> and allowing the performance of targeted biopsies using various techniques<sup>7</sup>. MRI/Ultrasound-fusion platforms allow targeting without radical modifications of the surrounding environment and technique, providing precise targeting and taking into account prostatic distortion and patient's movements<sup>8–10</sup>. Nevertheless, and although prostatic MRI before repeated biopsy is now recommended by official guidelines, its implementation before the first round of biopsies is still under evaluation, and a vast majority of patients still undergo standard transrectal ultrasound-guided prostate biopsy, even in centers where both techniques are available<sup>11</sup>.

Our objectives were to compare the results of these two strategies on two contemporary cohorts, and to describe the parameters orienting the choice of technique.

## Methods

We performed a retrospective monocentric study, on a prospectively gathered, institutionally-approved database of patients undergoing prostate biopsies between 2010 and 2015. All patients had given oral informed consent.

### *Inclusion and exclusion criteria. Biopsy technique.*

All patients involved in a prostate cancer screening procedure (PSA > 4 ng/mL, PSA increasing rate or pathological digital rectal examination), undergoing 12 cores ultra-sound guided prostatic biopsies (US-PB group) or 12 randomized ultra-sound guided biopsies plus 2 MRI-ultrasound fusion biopsies (MR-PB group) were included. Suspicious areas were defined on multiparametric prostatic MRI interpreted using the PiRADS V2 scoring system (PiRADS  $\geq 3/5$ ). Two targeted cores of the suspicious lesion were taken in case of a single lesion, and one core of each lesion in case of 2 suspicious lesions. If more than 2 lesions were identified on MRI, one core was taken in the 2 lesions of highest PiRADS score. Patients presenting with metastatic disease, symptoms related to locally advanced disease, or recurrence after treatment were excluded, as well as patients undergoing saturation biopsies or US-PB after a negative MRI.

The decision of orienting the patient towards US-PB or MR-PB was taken by the urologist in charge of the patient. US-PB were performed using a 3D transrectal ultrasound system (SonoAceX8, Medison) and targeted biopsies were performed using the Urostation® MRI-US fusion device (Koelis, Grenoble, France). All patients received pre-operative prophylaxis with fluoroquinolones and rectal enema, and the procedure was conducted under pure local or neuroleptanalgesia based on patient's preference.

### ***Collected data***

Collected data included the patient age at biopsy, MRI description, PSA rate and clinical stage at digital rectal examination, prostatic volume measured by trans-rectal ultrasound (using the ellipsoid formula), number of prior negative biopsy sessions, pathology results (number and location of positive biopsies, total cancer length, Gleason score of each positive biopsy).

### ***Statistical analysis***

We studied the association between the diagnostic of prostate cancer and the elected type of biopsy using a first multivariate logistic regression analysis, adjusted on various identified confounding factors such as age, digital rectal examination, prostatic volume, PSA rate and the existence of prior negative biopsies (Table 1). The distribution of Gleason scores across groups was reported (Table 2).

A second logistic regression model was adjusted to evaluate the impact of the parameters orienting the choice of biopsy technique (Table 3).

In the two logistic regression models, explanatory variables were tested by Wald's test. A significance threshold of 0.05 was adopted for all statistical analyses. Statistical analysis was performed using the computing environment R.

## **Results**

### ***Population***

Between November 2010 and July 2015, 372 prostatic biopsies were performed, of which 169 were ultra-sound guided biopsies (US-PB) and 203 were MRI-ultrasound fusion biopsies (MR-PB). Forty-six patients were excluded from the US-PB group and 82 from the MR-PB group. Fig. 1 summarizes the patient selection process (Fig. 1). One-hundred and fourteen patients in the US-PB group and 118 in the MR-PB group were included (Fig. 1). Patient's characteristics are summarized in Table 3.

### ***Biopsy results***

Prostate cancer was detected among 70 patients in the MR-PB group (59.3%) and 65 patients (57%) in the US-PB group. On multivariate analysis, MR-PB allowed the detection of a significantly higher number of prostate cancer cases than US-PB (OR = 3.22 (IC 95%: 1.63-7.09), p-value 0.001).

Among cancers diagnosed in the MR-PB group, 21 were detected by targeted biopsy cores only (15.5% of the diagnosed cancers). On average, two biopsies were positive in the MR-PB group and 3 in the US-PB group. The median cancer length was 10.5 mm in the US-PB group and 13 mm in the MR-PB group (Table 1). Distribution of Gleason scores across groups is presented in Table 3.

### ***Parameters orienting the choice of technique***

Younger patients ( $p=0.005$ ) with a prior history of negative biopsies ( $p<0.001$ ) were more likely to be offered the MRI-ultrasound fusion technique. A larger prostatic volume was also a factor predicting the choice of the targeted technique ( $p=0.001$ ). PSA rate (0.23) and normal

digital rectal examination (0.48) were not influencing significantly the choice of technique (Table 3).

## Discussion

This study confirms a higher cancer detection rate by MR-PB than US-PB after adjustment on confounding factors. To the best of our knowledge, this is the first study also reporting the parameters guiding the urologist's choice in the diagnostic strategy. When the two techniques are available, younger patients, with a past history of negative prostate biopsies, presenting a larger prostate volume, are more likely to be offered targeted prostate biopsies.

As expected, the two groups were not comparable and one could be worried that both populations did not *a priori* have the same risk of prostate cancer. We chose to exclude from the MR-PB group patients having a negative MRI, thus allowing no targeted procedure. These patients underwent a classical randomized echo-guided procedure, but were also excluded from the global analysis to prevent induced selection bias, these patients being at lower risk of having significant prostate cancer. Comparing both populations after applying our inclusion criteria to the overall population that underwent prostatic biopsy between 2010 and 2015, patients in the randomized biopsy group seemed at higher risk of presenting prostate cancer based on PSA rate, digital rectal examination, age, number of previous negative biopsies and prostate volume, therefore reducing the risk of bias when interpreting the superiority of MR-PB.

The MRI-ultrasound fusion technique is currently an interesting compromise to reduce overdiagnosis without missing an aggressive cancer<sup>3-5,12</sup>. Still, the additional cost of the technique and the extra-operating time needed leave a place for conventional ultrasound-guided randomized biopsies, even in centers where both techniques are available. It was thereafter interesting to try to define the population that will benefit the most of this new technique, perhaps before a generalization to the whole group of patients involved in a prostate cancer screening, as some authors currently suggest<sup>13</sup>.

The detection rate of 57% in the US-PB group and of 59.3% in the MR-PB group is above the usual values found in the literature (20-40% for a first round and 14-18% for a 2<sup>nd</sup> round of biopsies)<sup>10,12,14-19</sup>. This rate reflects both the efficiency of a strategy combining pelvic MRI and targeted biopsies, especially in the case of repeated prostate biopsies, but also an institutional attitude towards prostate cancer screening probably less aggressive than other centers.

The randomized trials published by Baco et al.<sup>15</sup>, and Tonttila et al.<sup>20</sup> failed to show a superiority of the MR-PB technique compared to standard 10 to 12- cores randomized prostate biopsies. In our study, multivariate logistic regression analysis showed a significantly higher detection rate in the MR-PB group. These results can be explained first by the fact that we compared the association of US-PB and MR-PB to US-PB alone and not only MR-PB to US-PB. Secondly, patients in the MR-PB group were previously screened by MRI and we only included patients with a PiRADS score  $\geq 3/5$ .

Younger patients with a larger prostate were more frequently offered the MRI-ultrasound fusion technique, as well as patients with a history of at least one prior negative prostate biopsy<sup>1,9,21-25</sup>. Targeted biopsies were mostly dedicated to patients having at least one

prior negative round of biopsies<sup>26</sup>, whom we suspected to have an anteriorly located aggressive cancer<sup>27</sup> or a cancer foci in a high volume of benign prostatic hyperplasia.

The limitations of this study, besides its retrospective nature, are mainly linked to the lack of systematic histological confirmation of the information obtained by prostatic biopsy (most notably in the case of negative biopsies), false negative rate being therefore impossible to evaluate. Regarding the choice of technique, we could deplore the lack of consideration for non-patient-related motivations such as the desire to limit healthcare costs<sup>28</sup>.

### **Conclusion**

Younger patients with a larger prostatic volume and a history of prior negative biopsies were more likely to be offered the MR-PB technique. When comparing the results of both techniques on two contemporary cohorts, on multivariate analysis, the detection rate was higher in the MR-PB group.

## References

1. Bjurlin MA, Meng X, Le Nobin J, et al. Optimization of prostate biopsy: the role of magnetic resonance imaging targeted biopsy in detection, localization and risk assessment. *J Urol*. 2014;192(3):648-658. doi:10.1016/j.juro.2014.03.117.
2. Hoeks CMA, Somford DM, van Oort IM, et al. Value of 3-T multiparametric magnetic resonance imaging and magnetic resonance-guided biopsy for early risk restratification in active surveillance of low-risk prostate cancer: a prospective multicenter cohort study. *Invest Radiol*. 2014;49(3):165-172. doi:10.1097/RLI.0000000000000008.
3. Wu J, Ji A, Xie B, et al. Is magnetic resonance/ultrasound fusion prostate biopsy better than systematic prostate biopsy? An updated meta- and trial sequential analysis. *Oncotarget*. 2015;6(41):43571-43580. doi:10.18632/oncotarget.6201.
4. Valerio M, Donaldson I, Emberton M, et al. Detection of Clinically Significant Prostate Cancer Using Magnetic Resonance Imaging-Ultrasound Fusion Targeted Biopsy: A Systematic Review. *Eur Urol*. 2015;68(1):8-19. doi:10.1016/j.eururo.2014.10.026.
5. Meng X, Rosenkrantz AB, Mendhiratta N, et al. Relationship Between Prebiopsy Multiparametric Magnetic Resonance Imaging (MRI), Biopsy Indication, and MRI-ultrasound Fusion-targeted Prostate Biopsy Outcomes. *Eur Urol*. 2016;69(3):512-517. doi:10.1016/j.eururo.2015.06.005.
6. Siddiqui MM, Rais-Bahrami S, Truong H, et al. Magnetic resonance imaging/ultrasound-fusion biopsy significantly upgrades prostate cancer versus systematic 12-core transrectal ultrasound biopsy. *Eur Urol*. 2013;64(5):713-719. doi:10.1016/j.eururo.2013.05.059.
7. Fiard G, Descotes J-L, Rambeaud J-J, Hohn N, Troccaz J, Long J-A. [MRI-guided targeted prostate biopsies in the diagnosis of prostate cancer: a systematic literature review]. *Prog En Urol J Assoc Fr Urol Société Fr Urol*. 2012;22(15):903-912. doi:10.1016/j.purol.2012.06.005.
8. Mozer P, Rouprêt M, Le Cossec C, et al. First round of targeted biopsies using magnetic resonance imaging/ultrasonography fusion compared with conventional transrectal ultrasonography-guided biopsies for the diagnosis of localised prostate cancer. *BJU Int*. 2015;115(1):50-57. doi:10.1111/bju.12690.
9. Fiard G, Hohn N, Descotes J-L, Rambeaud J-J, Troccaz J, Long J-A. Targeted MRI-guided prostate biopsies for the detection of prostate cancer: initial clinical experience with real-time 3-dimensional transrectal ultrasound guidance and magnetic resonance/transrectal ultrasound image fusion. *Urology*. 2013;81(6):1372-1378. doi:10.1016/j.urology.2013.02.022.
10. Delongchamps NB, Portalez D, Bruguère E, et al. Are MRI-TRUS-guided targeted biopsies non-inferior to TRUS-guided systematic biopsies for the detection of prostate cancer in patients with a single suspicious focus on multiparametric prostate MRI? Results of a multicentric controlled trial. *J Urol*. April 2016. doi:10.1016/j.juro.2016.04.003.

11. Salomon L, Bastide C, Beuzeboc P, et al. Recommandations en onco-urologie 2013 du CCAFU : Cancer de la prostate. *Prog En Urol*. 2013;23, Supplement 2:S69-S101. doi:10.1016/S1166-7087(13)70048-4.
12. Fourcade A, Perrouin-Verbe M, Tissot V, et al. Rôle des biopsies ciblées utilisant un système d'enregistrement 3D avec fusion élastique écho/IRM chez les hommes ayant une suspicion de cancer prostatique. *Prog En Urol*. 2015;25(13):832. doi:10.1016/j.purol.2015.08.230.
13. Burruni R, Cerantola Y, Meuwly J-Y, Tawadros T, Jichlinski P, Valerio M. [Prostate biopsy: which strategy for which patient?]. *Rev Médicale Suisse*. 2015;11(497):2288-2290, 2292.
14. Klein J, Mayor G, De Gorski A, Vallee J, Iselin C. Biopsies prostatiques ciblées par guidage IRM dans le diagnostic du cancer localisé de la prostate : taux de détection et valeur prédictive de l'imagerie. *Prog En Urol*. 2014;24(13):812. doi:10.1016/j.purol.2014.08.066.
15. Baco E, Rud E, Eri LM, et al. A Randomized Controlled Trial To Assess and Compare the Outcomes of Two-core Prostate Biopsy Guided by Fused Magnetic Resonance and Transrectal Ultrasound Images and Traditional 12-core Systematic Biopsy. *Eur Urol*. 2016;69(1):149-156. doi:10.1016/j.eururo.2015.03.041.
16. Peltier A, Aoun F, Lemort M, Kwizera F, Paesmans M, Van Velthoven R. MRI-targeted biopsies versus systematic transrectal ultrasound guided biopsies for the diagnosis of localized prostate cancer in biopsy naïve men. *BioMed Res Int*. 2015;2015:571708. doi:10.1155/2015/571708.
17. Attard G, Parker C, Eeles RA, et al. Prostate cancer. *The Lancet*. 2016;387(10013):70-82. doi:10.1016/S0140-6736(14)61947-4.
18. ROEHL KA, ANTENOR JAV, CATALONA WJ. Serial Biopsy Results in Prostate Cancer Screening Study. *J Urol*. 2002;167(6):2435-2439. doi:10.1016/S0022-5347(05)64999-3.
19. Campos-Fernandes J-L, Bastien L, Nicolaiew N, et al. Prostate Cancer Detection Rate in Patients with Repeated Extended 21-Sample Needle Biopsy. *Eur Urol*. 2009;55(3):600-609. doi:10.1016/j.eururo.2008.06.043.
20. Tonttila PP, Lantto J, Pääkkö E, et al. Prebiopsy Multiparametric Magnetic Resonance Imaging for Prostate Cancer Diagnosis in Biopsy-naïve Men with Suspected Prostate Cancer Based on Elevated Prostate-specific Antigen Values: Results from a Randomized Prospective Blinded Controlled Trial. *Eur Urol*. 2016;69(3):419-425. doi:10.1016/j.eururo.2015.05.024.
21. Pinto PA, Chung PH, Rastinehad AR, et al. Magnetic Resonance Imaging/Ultrasound Fusion Guided Prostate Biopsy Improves Cancer Detection Following Transrectal Ultrasound Biopsy and Correlates With Multiparametric Magnetic Resonance Imaging. *J Urol*. 2011;186(4):1281-1285. doi:10.1016/j.juro.2011.05.078.
22. Pokorny MR, de Rooij M, Duncan E, et al. Prospective study of diagnostic accuracy comparing prostate cancer detection by transrectal ultrasound-guided biopsy versus magnetic resonance (MR) imaging with subsequent MR-guided biopsy in men without

- previous prostate biopsies. *Eur Urol*. 2014;66(1):22-29. doi:10.1016/j.eururo.2014.03.002.
23. Sonn GA, Margolis DJ, Marks LS. Target detection: magnetic resonance imaging-ultrasound fusion-guided prostate biopsy. *Urol Oncol*. 2014;32(6):903-911. doi:10.1016/j.urolonc.2013.08.006.
  24. Sonn GA, Natarajan S, Margolis DJA, et al. Targeted Biopsy in the Detection of Prostate Cancer Using an Office Based Magnetic Resonance Ultrasound Fusion Device. *J Urol*. 2013;189(1):86-92. doi:10.1016/j.juro.2012.08.095.
  25. Sonn GA, Chang E, Natarajan S, et al. Value of Targeted Prostate Biopsy Using Magnetic Resonance–Ultrasound Fusion in Men with Prior Negative Biopsy and Elevated Prostate-specific Antigen. *Eur Urol*. 2014;65(4):809-815. doi:10.1016/j.eururo.2013.03.025.
  26. Vourganti S, Rastinehad A, Yerram NK, et al. Multiparametric Magnetic Resonance Imaging and Ultrasound Fusion Biopsy Detect Prostate Cancer in Patients with Prior Negative Transrectal Ultrasound Biopsies. *J Urol*. 2012;188(6):2152-2157. doi:10.1016/j.juro.2012.08.025.
  27. Rastinehad AR, Turkbey B, Salami SS, et al. Improving Detection of Clinically Significant Prostate Cancer: Magnetic Resonance Imaging/Transrectal Ultrasound Fusion Guided Prostate Biopsy. *J Urol*. 2014;191(6):1749-1754. doi:10.1016/j.juro.2013.12.007.
  28. de Rooij M, Crienien S, Witjes JA, Barentsz JO, Rovers MM, Grutters JPC. Cost-effectiveness of Magnetic Resonance (MR) Imaging and MR-guided Targeted Biopsy Versus Systematic Transrectal Ultrasound–Guided Biopsy in Diagnosing Prostate Cancer: A Modelling Study from a Health Care Perspective. *Eur Urol*. 2014;66(3):430-436. doi:10.1016/j.eururo.2013.12.012.



## Figures and Tables

Fig.1. Flow chart

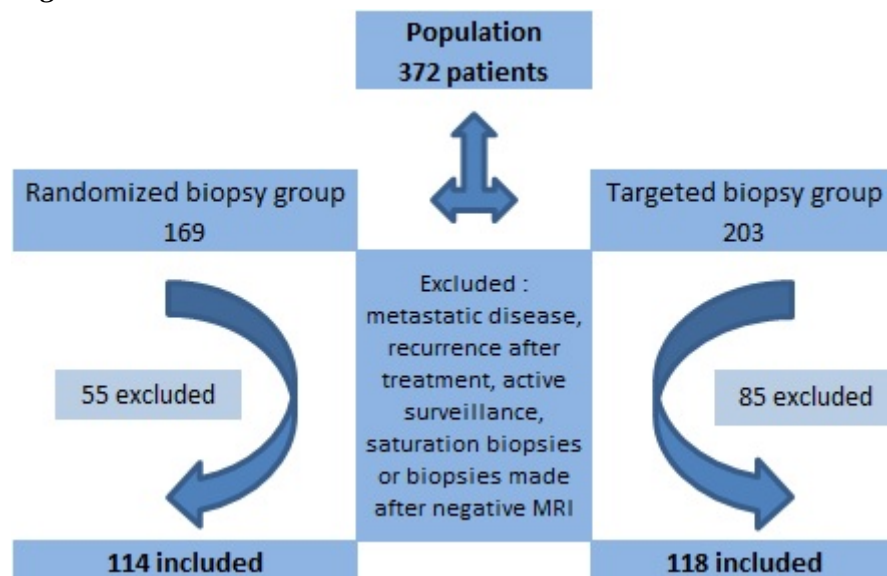


Table 1. Results on multivariate analysis

|                           | Randomized biopsies               | Targeted biopsies | Adjusted OR<br>(multivariate analysis) | p-value   |
|---------------------------|-----------------------------------|-------------------|--|-----------|
| Prostate cancer on biopsy | 65/114 (57%)                      | 70/118 (59,3%)    | OR = 3,00 [1,52 - 6,17]                | p = 0,002 |
| Explanatory variables     | Age (median)                      | 70.3              | OR = 1,09 [1,04 - 1,15]                | p < 0,001 |
|                           | PSA rate (median)                 | 9.7               | OR = 1,06 [1,02 - 1,13]                | p = 0,018 |
|                           | Prostate volume (median)          | 40                | OR = 0,97 [0,95 - 0,99]                | p < 0,001 |
|                           | First round of biopsies           | 60 (92.3%)        | OR = 2,33 [1,08 - 5,11]                | p = 0,032 |
|                           | Normal digital rectal examination | 32 (49.2%)        | OR = 0,35 [0,18 - 0,69]                | p = 0,003 |

Table 2. Gleason score repartition in targeted and randomized biopsy groups

|                           | Randomized biopsies | Targeted biopsies |
|---------------------------|---------------------|-------------------|
| Prostate cancer on biopsy | 65                  | 70                |
| Gleason 3+3               | 22 (34%)            | 23 (33%)          |
| Gleason 3+4               | 16 (25%)            | 19 (27%)          |
| Gleason 4+3               | 13 (20%)            | 15 (21%)          |
| Gleason 8 and more        | 14 (22%)            | 13 (19%)          |

**Table 3. Population and parameters orienting the choice of technique**

| Parameters orienting the choice of technique |                          | Randomized biopsy group | Targeted biopsy group | Adjusted OR [confidence interval] | p value          |
|--|--------------------------|-------------------------|-----------------------|-----------------------------------|------------------|
|  | Age (median)             | 68 [63-73]              | 65 [62-70]            | 0.917 [0.87-0.96]                 | <b>0.0005</b>    |
|  | Prostate volume (median) | 40 [30-50]              | 49 [38-66]            | 1.029 [1.01-1.05]                 | <b>0.001</b>     |
|  | PSA rate (median)        | 8.2 [5.5-12.9]          | 7.2 [5.6-12.0]        | 0.982 [0.69-1.01]                 | 0.23             |
|  | Normal DRE               | 68                      | 82                    | 0.791 [0.41-1.50]                 | 0.48             |
|  | First round of biopsies  | 106                     | 73                    | 0.098 [0.04-0.22]                 | <b>&lt;0.001</b> |
|  | TOTAL                    | 114                     | 118                   | NR                                | NR               |