

Ovarian vein thrombosis: A complication of percutaneous nephrolithotomy

Louisa Ho, BSc;¹ Grayson Hall, MD;² Richard Thomas, MD, FRCSC;³ Darren Beiko, MD, MBA, FRCSC¹

¹Department of Urology; ²Department of Radiology; ³Department of Obstetrics and Gynecology; Queen's University, Kingston, ON, Canada

Cite as: *Can Urol Assoc J* 2016;10(9-10):E309-11. <http://dx.doi.org/10.5489/cuaj.3728>
Published online September 13, 2016

Abstract

The medical and surgical complications of percutaneous nephrolithotomy (PCNL) are well-known, including deep venous thrombosis. Ovarian vein thrombosis (OVT) is a rare, but potentially serious type of venous thrombosis that has not previously been reported as a complication of PCNL or ureteral stent placement. We report a case of OVT associated with ureteral stenting following a tubeless PCNL. This complication was successfully managed conservatively without any short- or long-term sequelae.

Introduction

Percutaneous nephrolithotomy (PCNL) is widely used for extraction of large renal calculi. In tubeless PCNL, an indwelling ureteral stent replaces the traditional nephrostomy tube. This approach has been used with favourable outcomes in selected patients without increased complications over standard PCNL.¹ Ovarian vein thrombosis (OVT) is a potentially serious type of venous thrombosis most often diagnosed in women postpartum or following gynecological procedures. This case report describes a rare case of right-sided OVT associated with ureteral stenting following a tubeless ipsilateral PCNL.

Case report

A 47-year-old healthy female presented to the emergency department at our institution with a two-week history of right renal colic and hematuria. Urinalysis was positive for blood, but negative for pyuria or nitrites. Computed tomography (CT) scan revealed bilateral renal stones, with the largest stone being a right-sided 13 x 11 x 9 mm renal pelvic calculus (Fig. 1) and the largest left-sided calculus measuring 9 x 6 x 6 mm in the lower pole.

After discussing the options of shockwave lithotripsy, ureteroscopy, and PCNL, a decision was made to proceed with PCNL in an attempt to achieve complete removal of her right-sided renal stone burden. Informed consent was obtained and a seven-day course of prophylactic oral antibiotics was administered during the week leading up to her operation. Preoperative urine culture was negative.

Intraoperatively, prone cystoscopy was performed and retrograde ureteropyelography revealed that the calculus had migrated into the lower pole calyx from the renal pelvis. Lower pole calyceal access was achieved using a modified bull's eye technique, followed by balloon dilation and 30-French sheath insertion. Rigid nephroscopy readily identified the calculus, which was removed intact using a percutaneous nitinol stone basket. A 6-French, 24 cm ureteral stent was placed in an antegrade fashion. There were no intraoperative or early postoperative complications, and the patient was hemodynamically stable, with a hemoglobin of 117 g/L in the recovery room. She was discharged home with minimal discomfort 2.5 hours following the procedure. She was given a three-day course of oral antibiotics for continued urinary tract infection (UTI) prophylaxis.

The patient presented to the emergency department five weeks after the procedure with protracted irritative voiding symptoms, hematuria, and significant lower abdominal pain, but denied experiencing fever or chills. At time of presentation, she was afebrile and hemodynamically stable, with no history of septicemia. On physical examination, she had suprapubic and right costovertebral angle tenderness. Urinalysis was positive for blood and pyuria, but negative for nitrites. Routine laboratory tests were within normal limits and blood cultures were negative. The emergency room team ordered a CT scan that was negative for findings of pyelonephritis or obstructing calculi, although right-sided periureteral stranding was noted. Additionally, the right ovarian vein was expanded with mural enhancement and central hypoattenuation, consistent with intraluminal thrombus and a radiographic diagnosis of OVT (Fig. 2). The patient did not have a previous personal or family history for thrombosis and no other risk factor could be detected.

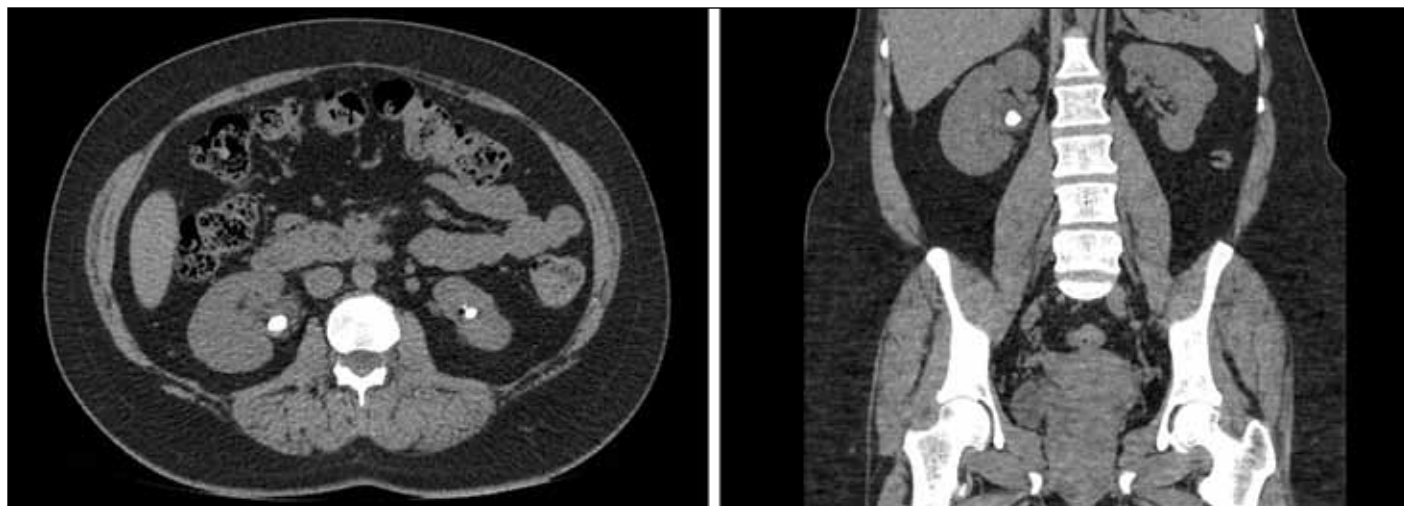


Fig. 1. Preoperative computed tomography images showing right renal pelvis calculus in transverse (*left*) and coronal (*right*) views.

The patient was managed conservatively and discharged in stable condition with a plan to followup at her six-week postoperative appointment two days later.

The patient was subsequently seen in clinic, and at that time her pain had improved and she was stable and otherwise doing well. The stent was removed cystoscopically. Stone analysis revealed a mixed stone containing calcium phosphate, magnesium ammonium phosphate, and calcium oxalate. Complete clinical resolution of her symptoms persisted at followup two years later.

Discussion

Although the incidence of OVT outside the postpartum period is not known, there are several conditions associated with OVT, including pelvic inflammatory disease, inflammatory bowel disease, underlying malignancy, sepsis, hypercoagulable state, and recent pelvic or abdominal surgery.² To the

best of our knowledge, there have been no previous reports of OVT associated with ureteral stenting. OVT is seldom idiopathic, and it is thought that bacterial injury to the ovarian venous endothelium may be an initiating step in the formation of OVT.³

Tubeless PCNL, while minimally invasive, still traverses through skin, retroperitoneal, and renal tissue to access the intrarenal collecting system, and is considered to be a clean-contaminated surgical procedure.¹ In addition, as a foreign body, the ureteral stent becomes colonized with bacteria within two weeks of placement.⁴ The most common complication arising from PCNL is infection, including UTI, fever, and septicemia. Ureteral infection or inflammation associated with ureteral stenting following PCNL may potentially be a mechanism for ovarian venous endothelial injury.

Patients with OVT typically present with persistent unexplained fever and abdominal pain one week after delivery or surgery. Approximately 80–90% of OVT occurs on the

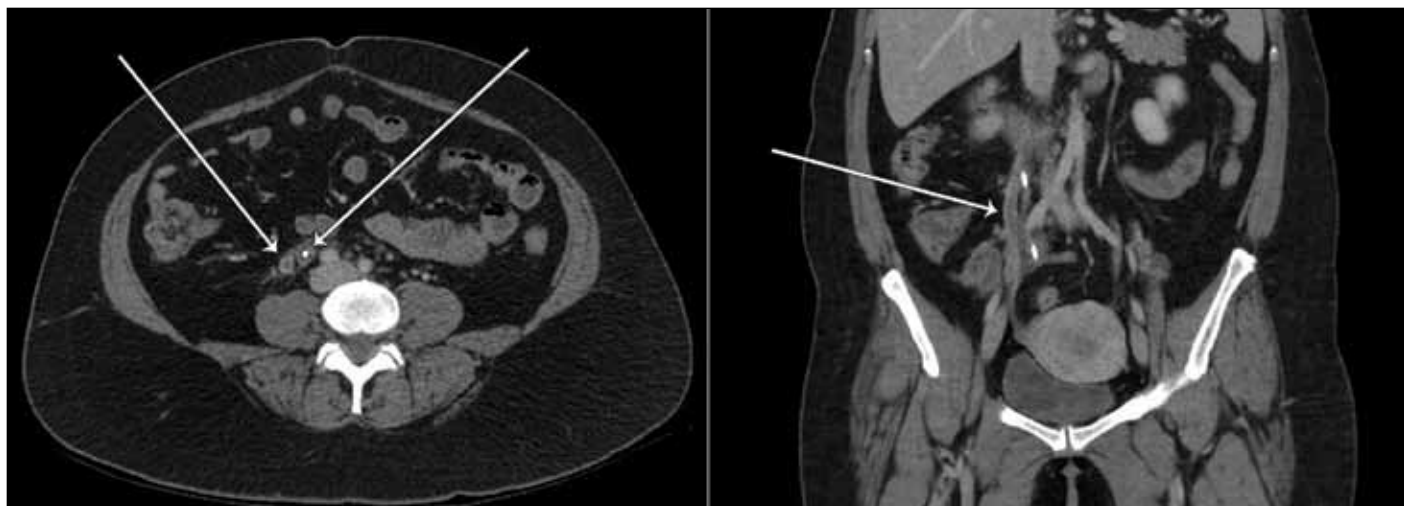

Fig 2. Postoperative computed tomography images showing right ovarian vein thrombosis (arrow) in transverse (*left*) and coronal (*right*) views.

right side.⁵ One accepted explanation for the predominant right localization is that the right ovarian vein has many incompetent valves along its length that may act as a nidus for thrombosis.³ Definitive diagnosis of OVT relies on radiographic findings, and CT scan with IV contrast is currently considered the imaging modality of choice.⁶

Potential complications of the thrombosis include extension into adjacent veins (iliac, femoral, renal, inferior vena cava) and pulmonary emboli. Risk of pulmonary embolism is low, and when emboli do occur, they tend to be small and rarely cause hypoxia. Mortality due to OVT is rare, and is most often attributable to overwhelming systemic infection due to septic emboli.^{2,3,6} In a study including 69 cases of septic pelvic thrombophlebitis among nearly 45 000 deliveries, no deaths were observed.⁷ Systemic anticoagulation to prevent further thrombosis in conjunction with antibiotic therapy is the most common treatment for OVT.^{3,8} Although there are no definite guidelines regarding duration of anticoagulation therapy for cases of OVT, febrile patients should be anticoagulated for at least 48 hours after defervescence.

This case was atypical, as the patient presented five weeks post-procedure, and at time of presentation she was afebrile. In this clinical situation, the patient did not receive anticoagulation and was managed conservatively, with clinical resolution of her symptoms. Our standard practice is to leave ureteral stents indwelling for 2–4 weeks following tubeless PCNL, but in her case, there was a longer wait list than usual for a cystoscopy suite appointment. As a result, her stent unfortunately remained indwelling for six weeks. It is conceivable that a shorter indwelling stent time may have prevented her OVT.

Conclusion

To the best of our knowledge, this is the first reported case of OVT associated with ureteral stenting following tubeless

PCNL. For this patient with a low risk profile for thrombosis, stable parameters and no evidence of infection, conservative treatment was appropriate and successful.

Competing interests: Dr. Beiko has received grants/honoraria from Cook Medical. The remaining authors report no competing personal or financial interests.

This paper has been peer-reviewed.

References

1. Feng MJ, Tamaddon K, Mikhail A, et al. Prospective randomized study of various techniques of percutaneous nephrolithotomy. *Urology* 2001;58:345-50. [http://dx.doi.org/10.1016/S0090-4295\(01\)01225-0](http://dx.doi.org/10.1016/S0090-4295(01)01225-0)
2. Heavrin BS, Wrenn K. Ovarian vein thrombosis: A rare cause of abdominal pain outside the peripartum period. *J Emerg Med* 2008;34:67-9. <http://dx.doi.org/10.1016/j.jemermed.2007.05.034>
3. Khlifi A, Kebaili S, Hammami M, et al. Postpartum ovarian vein thrombophlebitis: Report of a case and review of the literature. *North Am J Med Sci* 2010;2:389-391. <http://dx.doi.org/10.4297/najms.2010.2389>
4. Paick SH, Park HK, Oh SJ, et al. Characteristics of bacterial colonization and urinary tract infection after indwelling of double-J ureteral stent. *Urology* 2003;62:214-7. [http://dx.doi.org/10.1016/S0090-4295\(03\)00325-X](http://dx.doi.org/10.1016/S0090-4295(03)00325-X)
5. Prieto-Nieto MI, Perez-Robledo JP, Rodriguez-Montes JA, et al. Acute appendicitis-like symptoms as initial presentation of ovarian vein thrombosis. *Ann Vasc Surg* 2004;18:481-3. <http://dx.doi.org/10.1007/s10016-004-0059-9>
6. Yildirim E, Kanbay M, Ozbek O, et al. Isolated idiopathic ovarian vein thrombosis: A rare case. *Int Urogynecol J Pelvic Floor Dysfunct* 2005;16:308-10. <http://dx.doi.org/10.1007/s00192-004-1247-4>
7. Brown CE, Stettler RW, Twickler D, et al. Puerperal septic pelvic thrombophlebitis: Incidence and response to heparin therapy. *Am J Obstet Gynecol* 1999;181:143-8. [http://dx.doi.org/10.1016/S0002-9378\(99\)70450-3](http://dx.doi.org/10.1016/S0002-9378(99)70450-3)
8. Dessole SG, Capobianco AA, Demurtas PG, et al. Postpartum ovarian vein thrombosis: An unpredictable event: two case reports and review of the literature. *Arch Gynecol Obstet* 2003;267:242-6.

Correspondence: Dr. Darren Beiko, Department of Urology, Queen's University, Kingston, ON, Canada; beiko@queensu.ca