

Concurrent use of endourological and radiologic methods in the management of high-grade renal trauma

Ardalan Akbari, MD;¹ Manraj K.S. Heran, MD;² Kourosh Afshar, MD³

¹University of British Columbia, Vancouver, BC, Canada; ²Department of Radiology; ³Department of Urologic Sciences; University of British Columbia, Vancouver, BC, Canada

Cite as: *Can Urol Assoc J* 2016;10(9-10):E312-5. <http://dx.doi.org/10.5489/cuaj.3196>
Published online September 13, 2016

Abstract

This case report explores the efficacy of simultaneous use of endourological and radiological methods to assess and manage high-grade renal trauma. A male rugby player was diagnosed with Grade 4 blunt renal trauma. A segment of the patient's kidney was isolated from the main renal pelvis with intact perfusion. This resulted in urinary extravasation. Ureteral stenting and angioembolization were used to treat the patient's severe symptoms. Angioembolization ablated functional tissue that was causing a persistent urinary leak. Following the treatment, the patient was discharged with no significant bleeding or leakage from the kidney. This report illustrates an uncommon use of this combined approach. Followup 18 months post-trauma revealed normal blood pressure and approximately 30% loss of volume of the affected kidney.

Introduction

Renal injuries constitute up to 60% of pediatric genitourinary trauma.¹⁻³ In most instances, renal trauma can be managed conservatively, depending on the severity.⁴ However, a minimally invasive approach using endoscopic or interventional radiologic procedures may be necessary for patients presenting with high-grade renal trauma. Examples include angioembolization to control hemorrhage with the intent to minimize renal tissue loss⁵ and ureteral stents or nephrostomy tubes for management of urinary leaks. In this case, a combination of ureteral stenting and angioembolization was performed to respectively divert drainage and ablate functioning renal tissue that was causing a persistent urinary leak.

Case report

A 16-year-old boy presented to the emergency department with gross hematuria and abdominal pain following blunt trauma to his right flank during a rugby game. He was tachy-

cardic on arrival, but his vital signs were otherwise stable. Triphasic computed tomography (CT) scan showed a Grade IV right renal injury with retroperitoneal hematoma and urinary extravasation. The lower pole of the kidney was totally avulsed, but still perfused via a segmental arterial branch (Fig. 1). He was admitted to the intensive care unit. His vital signs and hemoglobin (Hb) stayed stable. Two days following transfer to the surgical ward, he developed fever and tachycardia. Following institution of broad-spectrum antibiotics, his urine and blood cultures returned negative, but his stool was positive for *C. difficile*, at which point intravenous metronidazole was prescribed. An ultrasound showed a perinephric fluid collection, which was drained percutaneously for ongoing fever and pain. He required blood transfusion for a slowly dropping Hb. His fever resolved in two days, but the drain output remained high (average 400 cc of clear urine per day). Retrograde ureteropyelogram demonstrated ongoing leakage from the avulsed lower pole calyx. A double-J ureteral stent was inserted (Figs. 2, 3). Over the course of the next few days, he remained clinically stable, however, drainage output persisted at 100 cc per day. A repeat CT scan showed a well-perfused, avulsed lower pole segment with ongoing urinary leakage (Fig. 4). A decision was made to embolize the segmental artery perfusing the lower pole. This was carried out without complications and resulted in immediate resolution of drainage (Fig. 5). A mild post-embolization fever was managed conservatively. His drain was removed after two days and he was discharged on Day 23 post-injury. His ureteral stent was removed four weeks after insertion.

The patient was clinically well at followup 18 months later, with full resumption of physical activities. His blood pressure was 116/50 mmHg. Ultrasound demonstrated loss of volume on the right side (right renal volume of 120 mL vs. 186 mL on the left side), but normal perfusion to the remaining parenchyma.

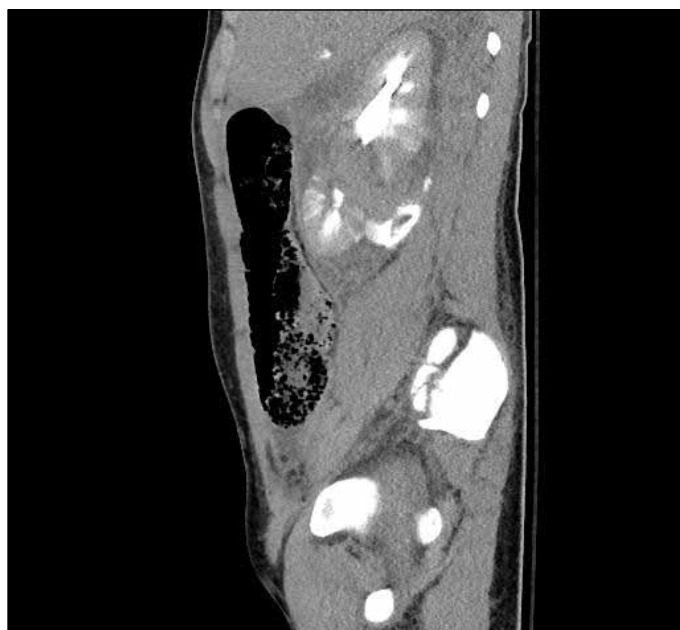


Fig. 1. Computed tomography scan performed at presentation showing Grade IV renal injury.

Discussion

Pediatric kidneys are believed to be more susceptible to traumatic injuries.⁶ This observation may be explained by the fact that children have relatively larger kidneys with higher mobility and less protective tissue. Approximately 90% of pediatric kidney injuries are due to blunt trauma.⁷ Recently, there has been an increasing trend towards non-operative treatments because the majority of these injuries

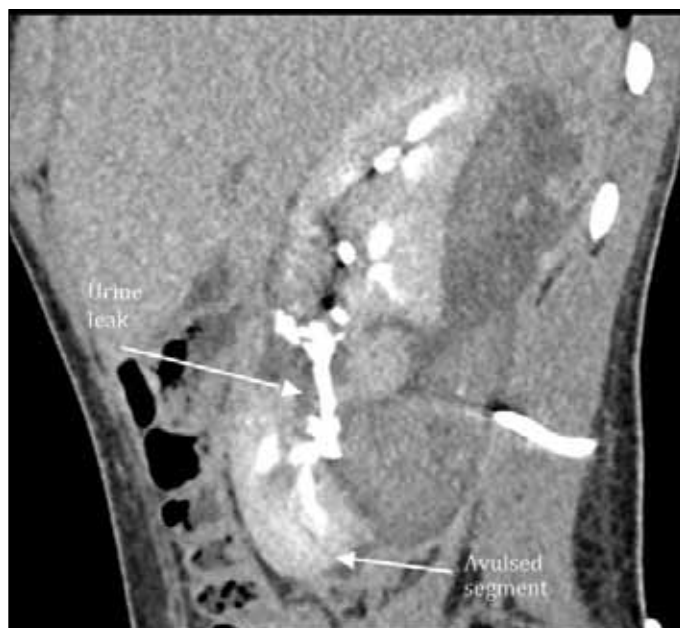

Fig. 3. Delayed computed tomography scan showing urinary leak.

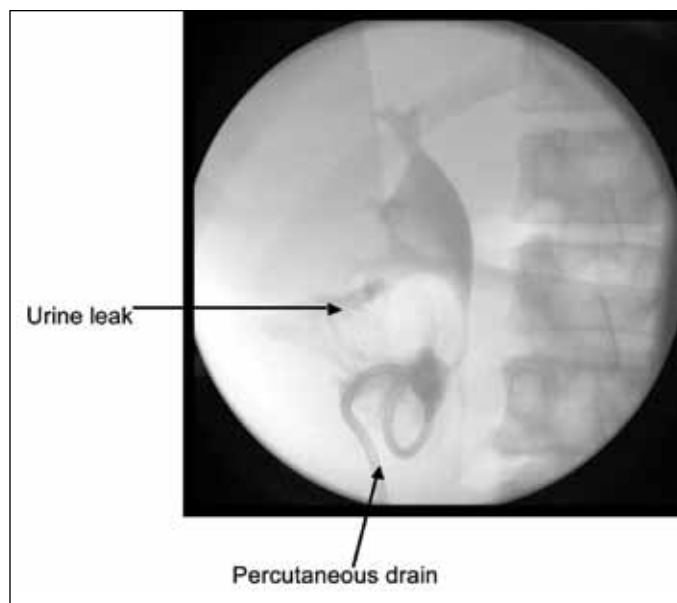


Fig. 2. Retrograde ureterogram showing urinary extravasation.

can be successfully managed conservatively.^{8,9} The severity of renal trauma is classified by an injury scale consisting of five grades, according to the American Association for the Surgery of Trauma (AAST). Low-grade injuries are typically managed conservatively, with no surgical intervention. In high-grade renal trauma, the kidney can have major lacerations that extend through the renal cortex, medulla, and collecting system, with or without vascular injuries. A

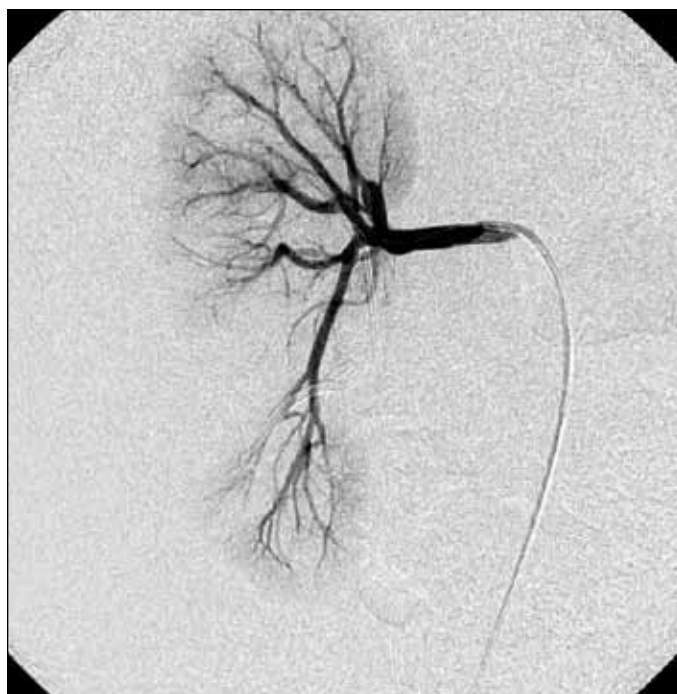

Fig. 4. Renal angiogram showing renal arterial supply.

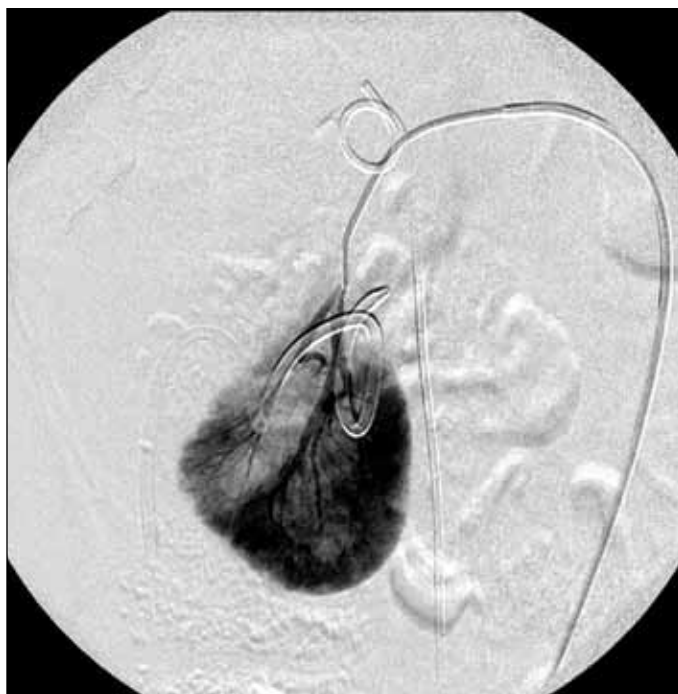


Fig. 5. Selective angiogram of the avulsed section pre-embolization.

surgical approach is usually reserved for high-grade cases such as a shattered kidney.⁸ The role of minimally invasive procedures, including endourological or radiological intervention, as an alternative to surgical intervention in the management of select cases of high-grade renal trauma is evolving.

CT is the primary radiologic imaging technique for the assessment and diagnosis of renal injuries.¹⁰ Santucci et al conducted a study on a sample of high-grade renal trauma patients and reported a 100% accuracy rate with respect to CT diagnoses.¹¹ The current case confirms the precision of CT in delineating the details and the extent of the renal injury in our patient.

The current body of literature advocates the role of interventional radiology in the treatment of renal trauma. The primary objective of this case report is to reveal how the simultaneous use of endourologic and radiological methods can successfully manage high-grade renal trauma. High-grade renal injuries may be associated with severe hemorrhage that can be treated with minimally invasive angioembolization.¹² Unlike most reports,¹³⁻¹⁵ our case involves the use of angioembolization to stop urine production from an unsalvageable, but perfused segment of the kidney in conjunction with a ureteral stent, as opposed to stopping persistent bleeding. We have not been able to find any reports that discuss angioembolization for such an indication. In our case, percutaneous drainage of the urinoma and ureteral stent alone were not effective due to the peculiar nature of the injury (i.e., a well-perfused, but otherwise avulsed

segment of the kidney causing persistent urinary extravasation). After the procedure, urinary leakage stopped and the majority of renal parenchyma remained functional.

A review of the literature in conjunction with our experience supports the simultaneous use of endourologic and radiologic methods in the management of complex high-grade renal trauma in the pediatric population. The concurrent use of these two modalities was effective for a patient who was hemodynamically stable, but displayed signs of persistent urinary extravasation due to high-grade blunt renal trauma. Although this scenario is not common, renal segmental ablation therapy should be considered an alternative to operative management to treat a persistent urine leak in selected cases.

Conclusion

This case illustrates the simultaneous use of endourological and radiological procedures to assess and manage an uncommon case of high-grade renal trauma. No significant complication occurred from the procedure and a considerable amount of renal parenchyma was preserved at long-term followup.

Competing interests: The authors report no competing personal or financial interests.

This paper has been peer-reviewed.

References

1. Levy JB, Baskin LS, Ewalt DH, et al. Non-operative management of blunt pediatric major renal trauma. *J Urol* 1993;42:418-24. [http://dx.doi.org/10.1016/0090-4295\(93\)90373-1](http://dx.doi.org/10.1016/0090-4295(93)90373-1)
2. Santucci RA, Mc Aninch JM. Grade IV renal injuries: Evaluator treatment and outcome. *World J Surg* 2001;1565-7. <http://dx.doi.org/10.1007/s00268-001-0151-Z>
3. Santucci R, Langenburg S, Zachareas M: Traumatic hematuria in children can be evaluated as in adults. *J Urol* 2004;171:822-5. <http://dx.doi.org/10.1097/01.ju.0000108843.84303.a6>
4. Harper K, Shah KH. Renal trauma after blunt abdominal injury. *J Emerg Med* 2013;45:400-4. <http://dx.doi.org/10.1016/j.jemermed.2013.03.043>
5. Willis AP. Interventional radiology in renal trauma. *Trauma* 2011;13:282-93. <http://dx.doi.org/10.1177/1460408611400802>
6. Husmann DA. Pediatric Genitourinary Trauma in *Campbell-Walsh Textbook of Urology*, 10th ed. Philadelphia: Elsevier, 2012:3731-53.
7. Elashry OM, Dessouky BA. Conservative management of major blunt renal trauma with extravasation: A viable option? *Eur J Trauma Emerg Surg* 2009;35:115-23. <http://dx.doi.org/10.1007/s00068-008-8105-x>
8. Umbreit EC, Routh JC, Husmann DA. Non-operative management of non-vascular Grade IV blunt renal trauma in children: Meta-analysis and systematic review. *Urology* 2009;74:579-82. <http://dx.doi.org/10.1016/j.urol.2009.04.049>
9. Matthews LA, Smith EM, Spirnak JP. Non-operative treatment of major blunt renal lacerations with urinary extravasation. *J Urol* 1997;157:2056-8. [http://dx.doi.org/10.1016/S0022-5347\(01\)64673-1](http://dx.doi.org/10.1016/S0022-5347(01)64673-1)
10. Kawashima A, Sandler CM, Corl FM, et al. Imaging of renal trauma: A comprehensive review. *Radiographics* 2001;21:557-74. <http://dx.doi.org/10.1148/radiographics.21.3.g01ma11557>
11. Santucci RA, McAninch JW. Diagnosis and management of renal trauma: Past, present, and future. *J Am Coll of Surg* 2000;191:443-51. [http://dx.doi.org/10.1016/S1072-7515\(00\)00695-5](http://dx.doi.org/10.1016/S1072-7515(00)00695-5)

12. Dinkel H-P, Danuser H, Triller J. Blunt renal trauma: Minimally invasive management with microcatheter embolization: Experience in nine patients. *Radiology* 2002;223:723. <http://dx.doi.org/10.1148/radiol.2233011216>
13. Master VA, McAninch JW. Operative management of renal injuries: Parenchymal and vascular. *Urol Clin North Am* 2006;33:21-31. <http://dx.doi.org/10.1016/j.ucl.2005.11.006>
14. Mavili E, Donmez H, Ozcan N, et al. Transarterial embolization for renal arterial bleeding. *Diagn Interv Radiol* 2009;15:143-7.
15. Corr P, Hacking G. Embolization in traumatic intrarenal vascular injuries. *Clin Radiol* 1991;43:262-4. [http://dx.doi.org/10.1016/S0009-9260\(05\)80252-1](http://dx.doi.org/10.1016/S0009-9260(05)80252-1)

Correspondence: Dr. Kourosh Afshar, Department of Urologic Sciences, University of British Columbia, Vancouver, BC, Canada; kafshar@cw.bc.ca